

Transcatheter Closure of Aorto-Left Atrial Fistula Using an Amplatzer Device

José M. Hernández-García,^a Juan H. Alonso-Briales,^a Manuel F. Jiménez-Navarro,^a Fernando Cabrera-Bueno,^a Emilio González-Cocina,^b and Miguel Such-Martínez^a

^aUnidad del Corazón, Hospital Universitario Virgen de la Victoria, Málaga, Spain.

^bServicio de Cardiología, Hospital Costa del Sol, Marbella, Málaga, Spain.

Aorto-left atrial fistulas are rare. We describe the case of a patient in whom transcatheter closure of an aorto-left atrial fistula was carried out using an Amplatzer septal occluder. The patient had previously undergone cardiac surgery twice because of a recurrent left atrial myxoma. Closure of this type of fistula using a transcatheter device should be considered when the location and size of the fistula are appropriate and there are no associated abnormalities. The risk of surgery must also be taken into account.

Key words: *Catheterization. Fistula. Shunt.*

Cierre percutáneo de una fístula entre aorta y aurícula izquierda mediante dispositivo Amplatzer

Las fístulas entre la aorta y la aurícula izquierda son excepcionales. Describimos un caso tras cirugía en dos ocasiones de un mixoma auricular izquierdo con posterior recidiva, que fue tratado mediante una prótesis Amplatzer para el cierre de la comunicación interventricular. El cierre percutáneo de estas fístulas debe valorarse en función del riesgo quirúrgico y cuando la localización y el tamaño sean adecuados, en ausencia de anomalías asociadas.

Palabras clave: *Cateterismo cardíaco. Fístula. Cortocircuito.*

INTRODUCTION

Fistulas between the aorta and cardiac cavities are rare and usually found in the right cavities. The presence of fistulas between the aorta and the left atrium (AOF-LA) is associated with complications of infectious endocarditis¹ and paravalvular abscess, aortic dissection,² and surgery affecting the valve or aortic root. We describe a patient with LA-AOF after resection of a left atrial myxoma presenting heart failure who underwent percutaneous treatment with an Amplatzer device for closure of interventricular communication.

CLINICAL CASE

Woman, 72 years old, admitted to hospital due to heart failure. She had undergone intervention in ano-

ther center on two occasions for left atrial myxoma and posterior relapse (18 years and 15 years before, respectively) and had been diagnosed at follow-up with asymptomatic LA-AOF. Electrocardiogram showed atrial flutter that was electrically cardioverted. The patient continued with heart failure despite treatment with diuretics and captopril. Transesophageal echocardiogram showed LA-AOF through the non-coronary sinus with an important shunt through it. The left ventricle was mildly dilated and presented preserved systolic function.

Cardiac catheterization was done showing normal lung pressure (30/14/20) and a pulmonary capillary pressure of 14 mm Hg. Aortography showed a large flow of contrast agent from the noncoronary sinus to the left atrium (Figure 1A and B).

We decided on transcatheter closure of the LA-AOF which was done via the right femoral artery. By use of a right coronary Judkins catheter, a hydrophilic guidewire was advanced from the aorta, via the fistula, to the left atrium with the catheter over this (Figure 2). Next, a long high-support guidewire was introduced into the left atrium and the coronary right catheter was exchanged for an Amplatzer delivery system. Through this system, an Amplatzer de-

Correspondence: Dr. J.M. Hernández García.
Unidad del Corazón. Hemodinámica. Hospital Universitario Virgen de la Victoria.
Campus Teatinos, s/n. 29010 Málaga. España.
E-mail: jmhg@secardiologia.es

Received October 18, 2004.

Accepted for publication January 18, 2005.

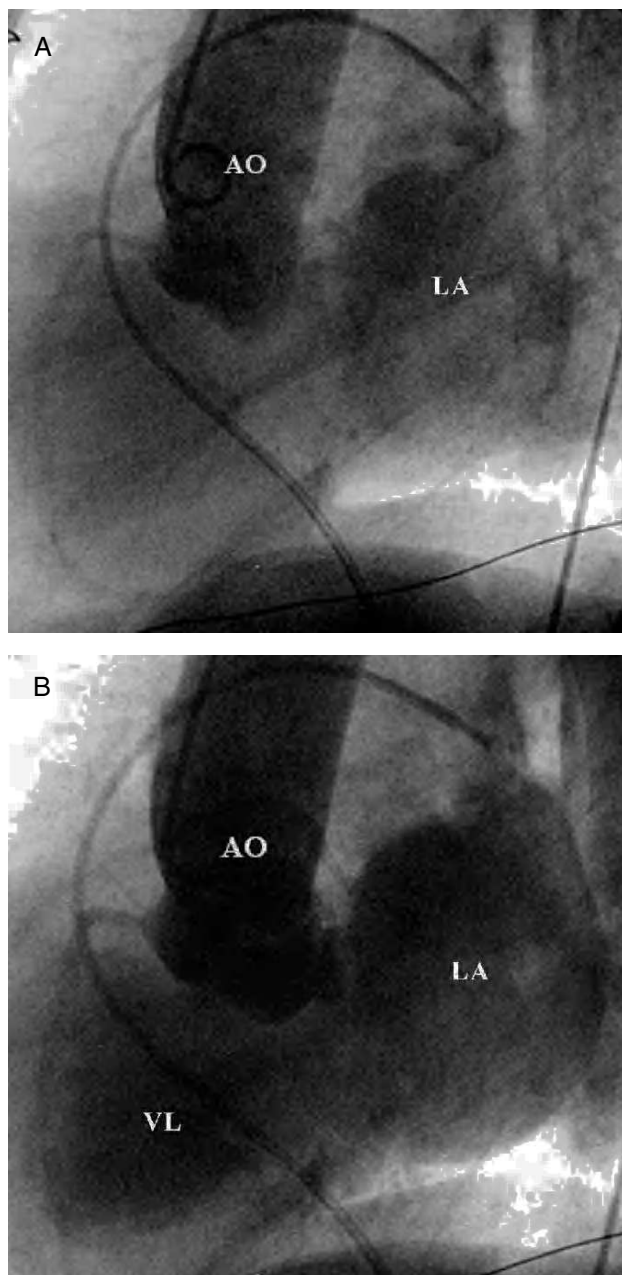


Figure 1. A: fistula between the noncoronary sinus of the aorta and left atrium. Aortography in lateral projection (90° LAO); only the aorta and left atrium are filled in these initial images. B: finally, the aorta, atrium, and left ventricle are contrast-filled. LA indicates left atrium; AO, aorta; LV, left ventricle.

vice was advanced via this system to close the 12-mm interventricular communication (AGA Medical Corporation, Golden Valley, Minneapolis, USA). This device is made of nitinol mesh with dacron patches inside consisting of 2 disks joined by a 7-mm central neck. Under fluoroscopic guidance and transesophageal echocardiogram, the delivery system was gradually withdrawn until the device was completely deployed, leaving 1 disc in the left atrium and the other in the aorta, checking that valve operation was

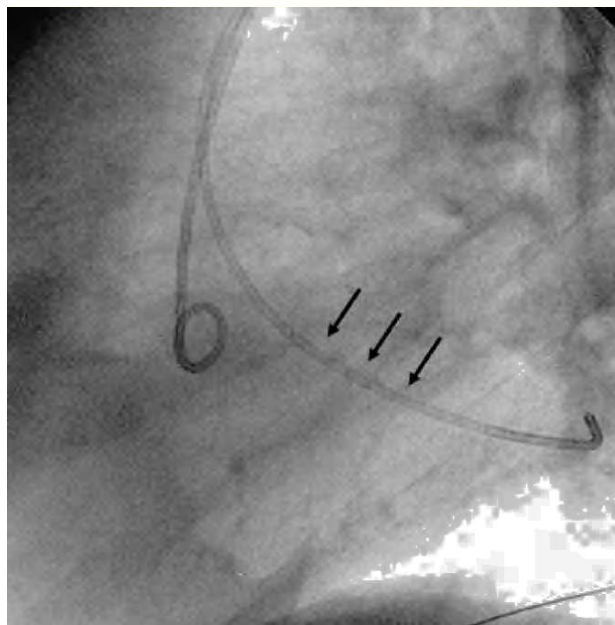


Figure 2. Passage of the catheter (arrows) from the aorta through the fistula to the left atrium.

not blocked. Transesophageal echocardiogram and control aortography showed that the device had been correctly placed with minimum leakage to the left atrium (Figure 3A and B). The patient received 100 mg aspirin/day to which 75 mg clopidogrel/day was added for 3 months. At 6-month follow-up, the patient was asymptomatic and the echocardiogram did not show residual shunt.

DISCUSSION

Closure of LA-AOF is indicated in symptomatic patients and surgery is the standard treatment. Transcatheter closure was based on the favorable angiographic characteristics (noncoronary sinus, small diameter) and the background of 2 heart operations.

Recently, isolated experiences have been reported with an Amplatzer device in the treatment of perivalvar leak involving prosthetic mitral valve,³ sinus rupture of Valsalva aneurysm in right cavities,⁴ aortopulmonary window,⁵ and coronary fistulas in right cavities.⁶

Closure of LA-AOF with an Amplatzer device for antegrade closure of the ductus has been described in the literature with subsequent closure of an *ostium secundum*-type interatrial communication.⁷ Not having to carry out transeptal puncture would have suggested the antegrade approach to the authors making it possible for them to implant a device for ductus closure (with a single external disc that remains in the aorta). We chose the retrograde approach due to its simplicity aiming to implant an interventricular communication closure device.

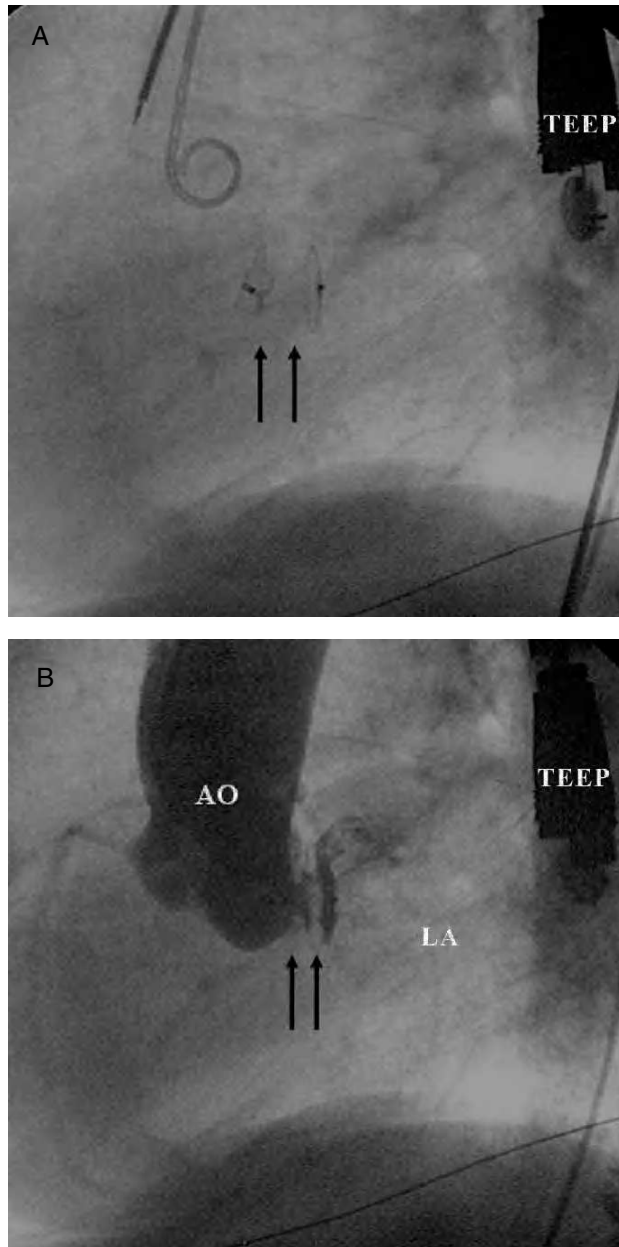


Figure 3. A: Amplatzer device (arrows) in the fistula under fluoroscopic guidance. B: aortography after implantation of the Amplatzer device in the fistula with minimum residual leak. LA indicates left atrium; AO, aorta. TEEP, transesophageal echocardiography probe.

Choice of the device was based on angiographic and echocardiographic findings, and the need for two discs to be anchored in the aorta and left atrium with a 7-mm central neck.

The 80-cm length of the Amplatzer delivery system makes a brachial approach necessary, but in short patients, as in this case, a femoral approach was possible. Potential risks could involve occluding a coronary ostium or restricting the movement of the aortic valves. In the present case, the fistula was located in the non-coronary sinus and had a small diameter, meaning that there was less risk, but such possible complications should be assessed before definitively releasing the device.

In conclusion, the percutaneous closure of LA-AOF with an Amplatzer-type device can be considered a therapeutic option in cases when the anatomy is favorable.

REFERENCES

1. Archer TP, Mabee SW, Baker PB, Orsinelli DA, Leier CV. Aorto-Left atrial fistula. A reversible cause of acute refractory heart failure. *Chest*. 1997;111:828-31.
2. Patsouras D, Argyri Q, Siminilakis S, Michalis L, Sideris D. Aortic dissection with aorto-left atrial fistula formation soon after aortic valve replacement: A lethal complication diagnosed by transthoracic and transesophageal echocardiography. *J Am Soc Echocardiogr*. 2002;15:1409-11.
3. Korth HW, Sharkey AM, Balzer DT. Novel use of the Amplatzer duct occluder to close perivalvar leak involving a prosthetic mitral valve. *Catheter Cardiovasc Interv*. 2004;61:548-51.
4. Arora R, Trehan V, Rangasetty UM, Mukhopadhyay S, Thakur AK, Kalra GS. Transcatheter closure of ruptured sinus of Valsalva aneurysm. *J Interv Cardiol*. 2004;17:53-8.
5. Naik GD, Chandra VS, Shenoy A, Isaac BC, Shetty GG, Padmakumar P, et al. Transcatheter closure of aortopulmonary window using Amplatzer device. *Catheter Cardiovasc Interv*. 2003;59:402-5.
6. Tang JJ, Zhou SH, Shen XQ. Transcatheter closure of large fistula between left main coronary artery and right atrium using Amplatzer duct occluder. *Heart*. 2003;89:772.
7. Suárez J, Medina A, Pan M, Romero M, Segura J, Pavlovic D, et al. Transcatheter occlusion of complex atrial septal defects. *Catheter Cardiovasc Interv*. 2000;51:33-41.