

Transient Left Ventricular Apical Ballooning Without Coronary Stenoses Syndrome: Importance of the Intraventricular Pressure Gradient

Roberto Barriaes Villa,^a Raquel Bilbao Quesada,^a Enrique Iglesias Río,^a Nicolás Bayón Meleiro,^a Ramón Mantilla González,^b and Manuel Penas Lado^a

^aServicio de Cardiología, Complejo Hospitalario de Pontevedra, Pontevedra, Spain.

^bUnidad de Cardiología Intervencionista, Hospital do Meixoeiro, Vigo, Pontevedra, Spain.

A syndrome of transient apical ballooning without coronary stenosis, which mimics acute myocardial infarction, was recently described. Although several possible etiologic mechanisms have been proposed and investigated, the precise cause remains unclear. We describe 3 cases of transient left ventricular apical ballooning without coronary stenosis, and discuss the etiology of this syndrome, in particular the possible role of a transient intraventricular gradient.

Key words: *Myocardial infarction. Myocardial ischemia. Myocardial stunning. Obstruction. Hypertrophy.*

Full English text available at: www.revespcardiol.org

Síndrome de discinesia apical transitoria sin lesiones coronarias: importancia del gradiente intraventricular

Recientemente se ha descrito un síndrome caracterizado por discinesia (*ballooning*) apical transitoria, sin lesiones coronarias, que simula un infarto agudo de miocardio. Aunque se especula sobre sus posibles causas, su verdadero origen es todavía desconocido. Describimos 3 casos de este síndrome y discutimos su etiología, en particular el posible papel de un gradiente intraventricular transitorio.

Palabras clave: *Infarto de miocardio. Isquemia miocárdica. «Aturdimiento» miocárdico. Obstrucción. Hipertrofia.*

INTRODUCTION

In most cases acute myocardial infarction (AMI) is caused by thrombotic occlusion of a coronary artery and its treatment is based on early reperfusion. Not all AMIs have this etiology, however, and not all benefit from the same treatment.¹ A recently described syndrome mimicking AMI, known as transient apical ballooning, is characterized by dyskinesia of the apical portion of the left ventricle without coronary stenosis.²⁻⁴ Several possible causes have been proposed for this syndrome, which is often triggered by situations involving physical or psychological stress and adrenergic discharge. These include

myocardial “stunning” of neurogenic origin, coronary spasm, alterations in coronary microcirculation, and myocarditis.^{2,3} Nevertheless, its true cause is still uncertain.

Transient intraventricular gradients have been detected in many of these patients and their possible role as a cause or a consequence of transient apical ballooning syndrome has also been the subject of discussion.^{2,5} We describe three new cases of transient apical ballooning and discuss the etiology of this condition, in particular the possible role of a transient intraventricular gradient as the initial causative mechanism in some of these cases.

Case 1

A 76-year-old woman with hypertension and chronic atrial fibrillation under treatment with diltiazem and oral anticoagulant agents experienced intense retrosternal pain with considerable nausea and sweating after hearing about the death of a relative. The

Correspondence: Dr. M. Penas Lado.
Servicio de Cardiología. Complejo Hospitalario de Pontevedra.
Mourete-Montecelo. 36071 Pontevedra. España.
E-mail: manuel.penas.lado@sergas.es

Received 31 July, 2003.

Accepted for publication 27 October, 2003.

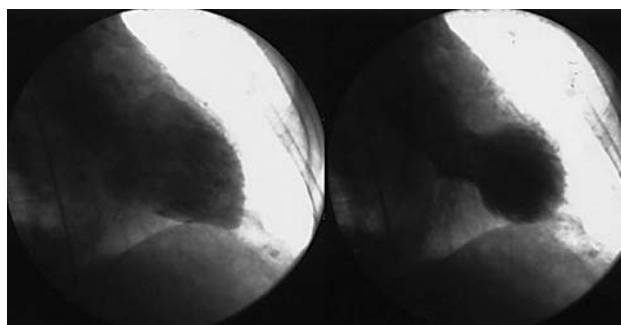


Figure 1. Right anterior oblique (RAO) ventriculography, in diastole and in systole, demonstrates characteristic apical ballooning.

electrocardiogram (ECG) showed anterior ST segment elevation. On the basis of suspected AMI in a patient under anticoagulation therapy, she was referred for primary angioplasty. Catheterization showed apical ballooning (Figure 1), without coronary artery lesions. Echocardiography performed 24 hours later revealed anteroapical, medial and apical akinesia, an ejection fraction of 35% and no evidence of intraventricular gradient. Cardiac enzymes were not elevated. The patient was treated with enalapril, amlodipine and pravastatin, and 100 mg of acetylsalicylic acid was added to her anticoagulant treatment. One month later the patient was asymptomatic, the ballooning had disappeared, and overall and regional ventricular function were normal on the echocardiogram.

Case 2

A 78-year-old woman with hypertension came to the hospital for acute epigastric pain of 12 hours' duration. The ECG showed anterior wall ST segment elevation (Figure 2). She presented melena and a hemoglobin level of 8 g/L. After transfusion of 2 units of packed RBCs, the symptoms disappeared and the ECG evidenced extensive anterior subepicardial ischemia.

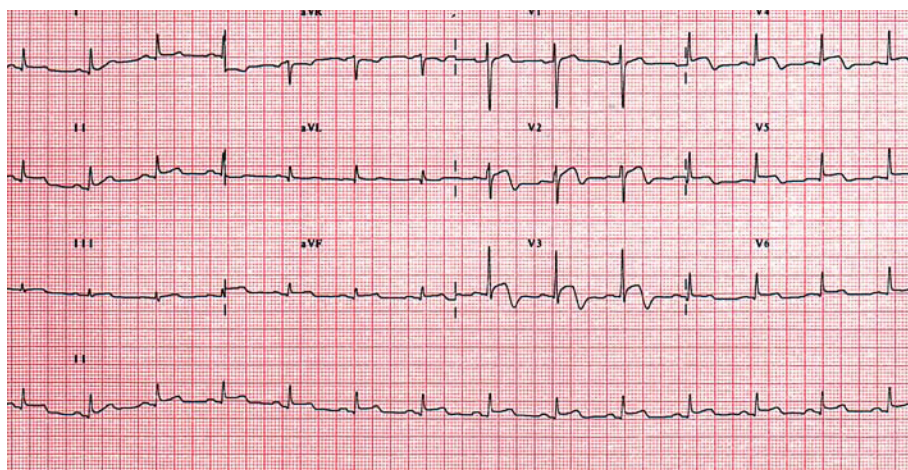


Figure 2. Twelve-lead electrocardiogram shows ST segment elevation in the anteroapical wall at the time of hospital admission.

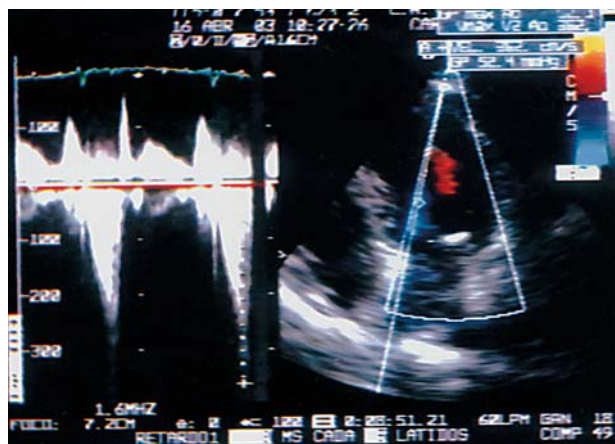


Figure 3. Transthoracic echocardiography image shows a dynamic subaortic gradient.

The troponin I concentration was 8.5 ng/mL. The echocardiogram showed anteroapical akinesia and dynamic subaortic obstruction with a peak gradient of 42 mm Hg (Figure 3). Catheterization performed 5 days later showed normal coronary arteries and apical ballooning; an intraventricular gradient was not detected at that time. The patient was treated with carvedilol, clopidogrel and gastroprotective agents. She has remained asymptomatic after 15 months of follow-up, with normalized ECG and left ventricular wall motion.

Case 3

A 70-year-old hypertensive woman experienced retrosternal pain with nausea and sweating, coinciding with fever due to a respiratory condition. She came to the hospital 24 hours later. The ECG showed anterolateral subepicardial ischemia and troponin I elevation to 4 ng/mL. The echocardiogram demonstrated an intraventricular dynamic gradient of 80 mm Hg, with moderate mitral regurgitation and apical ballooning. Atenolol treatment was started. Subsequent

catheterization showed no significant coronary disease, although apical ballooning with no intraventricular gradient was seen. The patient was discharged with atenolol and acetylsalicylic acid. At 1 month, no intraventricular gradient was detected, and the ECG findings and ventricular wall motion were normal.

DISCUSSION

The cause and pathogenic mechanisms of transient apical ballooning syndrome without coronary stenosis mimicking AMI, a condition described by Tsuchihashi et al,² remain uncertain. Thus, acute management of this condition and prevention of recurrence are still difficult. Various possible etiologic mechanisms have been proposed and analyzed, including coronary spasm, coronary microcirculation alterations and myocarditis,^{2,3} but none of them have been clearly related with this syndrome. Neurogenic myocardial “stunning” induced by physical or emotional stress has been suggested as the most probable cause.² In any case, the fact that in many of these patients (including those presented here) the clinical manifestations are preceded by severe physical or emotional stress, or by acute concomitant illnesses, suggests a catecholamine-mediated mechanism.²

There is evidence that the generation of a transient intraventricular dynamic gradient, present in many of these cases (including 2 in our series), can play an important role in the genesis of transient apical ballooning.⁵⁻⁷ In previously described cases, the clinical and hemodynamic situation improved when the gradient disappeared⁷ and in some patients with cardiogenic shock on hospital admission, the condition persisted until the dynamic obstruction was identified and specifically treated.^{5,6} We suggest that, at least in some patients, transient apical ballooning syndrome may be produced by the development of an acute, severe, transient dynamic left ventricular outflow tract (LVOT) obstruction that precedes and causes the ischemic episode.⁸ Dynamic obstruction would raise intraventricular pressures in the distal chamber and reduce myocardial perfusion in this area, leading to apical ischemia and dyskinesia.⁸ In fact, exposure to an exogenous catecholamine, as in dobutamine infusion, can provoke dynamic LVOT obstruction even in normal hearts.⁹ Moreover, some patients with hypertrophic cardiomyopathy can present apical necrosis associated with intraventricular gradients.¹⁰

Some patients, particularly women such as the cases presented, might have a geometric predisposition (sigmoid septum, narrow LVOT, reduced left ventricular volume) to the development of dynamic subaortic obstruction that would only be manifested in situations of intense adrenergic stimulation or hypovolemia.^{5,6,8}

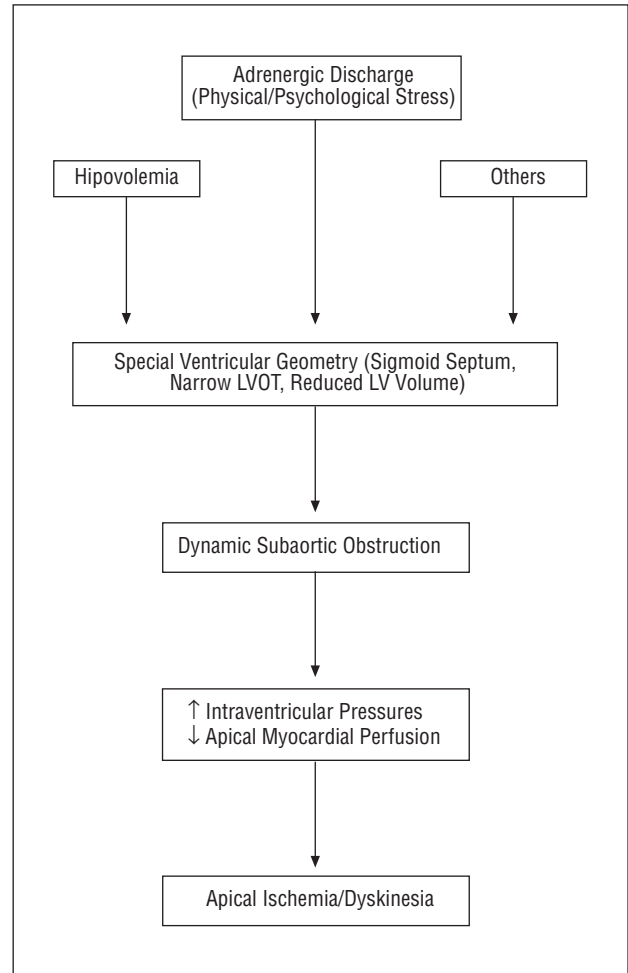


Fig. 4. Proposed pathophysiological mechanism of transient apical ballooning syndrome without coronary lesions. LVOT indicates left ventricular outflow tract; LV, left ventricle.

The intense physical or psychological stress that precedes apical ischemia in the majority of patients with transient apical ballooning syndrome² would be the triggering factor of the acute dynamic subaortic or mid-ventricular obstruction causing the apical ischemia⁸ (Figure 4).

At least in theory, the intraventricular gradients detected in some patients with transient apical ballooning could be a consequence and not the cause of the apical dyskinesia (and compensating basal hyperkinesia).^{2,5} However, the transitory nature of these gradients, with early, spontaneous resolution in the majority of cases,² makes this an unlikely hypothesis. Nevertheless, in some patients persistence of the gradient can contribute to maintaining the apical ischemia and hemodynamic deterioration, which would improve with beta-blockers.^{4-7,11}

Identification of a dynamic LVOT gradient as the possible initial mechanism in these patients could have important clinical and therapeutic implications. The usual measures for treating patients with chest pain

and evidence of myocardial ischemia (nitrates) can increase the gradient and cause greater deterioration, whereas elimination of the gradient with beta-blockers, volume expansion or alpha adrenergic stimulants could be beneficial or even vital.^{5,6,11} Precise identification of the etiopathogenic mechanism is also essential to establish suitable treatment for the prevention of possible recurrence in these patients.⁸

REFERENCES

1. Arós F, Loma-Orsio A, Alonso A, Alonso JJ, Cabadés A, Coma-Canella I, et al. Guías de actuación clínica de la Sociedad Española de Cardiología en el infarto agudo de miocardio. *Rev Esp Cardiol* 1999;52:919-56.
2. Tsuchihashi K, Ueshima K, Uchida T, Oh-mura N, Kimura K, Owa M, et al. Transient left ventricular apical ballooning without coronary artery stenosis: a novel heart syndrome mimicking acute myocardial infarction. *J Am Coll Cardiol* 2001;38:11-8.
3. Abe Y, Kondo M, Matsuoka R, Araki M, Doshima K, Tanio H.

Assessment of clinical features in transient left ventricular apical ballooning. *J Am Coll Cardiol* 2003;41:737-42.

4. Pereira Moral JR, Segovia Cubero J, Oteo Domínguez JF, Ortiz Oficialdegui P, Fuentes Manso R, Martín Júdez V. Síndrome de discinesia apical transitoria con una complicación inusual. *Rev Esp Cardiol* 2002;55:1328-32.
5. García Quintana A, Ortega JR, Padrón A, Huerta R, González L, Medina A. Shock cardiogénico secundario a obstrucción dinámica del tracto de salida del ventrículo izquierdo como complicación mecánica del infarto agudo de miocardio. *Rev Esp Cardiol* 2002;55:1324-7.
6. Haley JH, Sinak LJ, Tajik AJ, Ommen SR, Oh JK. Dynamic left ventricular outflow tract obstruction in acute coronary syndromes: an important cause of new systolic murmur and cardiogenic shock. *Mayo Clin Proc* 1999;74:901-6.
7. Villareal RP, Achari A, Wilansky S, Wilson JM. Anteroapical stunning and left ventricular outflow tract obstruction. *Mayo Clin Proc* 2001;76:79-83.
8. Penas-Lado M, Barriales-Villa R, Goicolea J. Transient left ventricular apical ballooning and outflow tract obstruction. *J Am Coll Cardiol* 2003;42:1143-4.
9. Luria D, Klutstein MW, Rosenmann D, Shaheen J, Sergey S, Tzivoni D. Prevalence and significance of left ventricular outflow gradient during dobutamine echocardiography. *Eur Heart J* 1999;20:386-92.
10. Penas-Lado M, Barriales-Villa R, Arias JC. Apical hypertrophic cardiomyopathy, intraventricular pressure gradients and ST segment elevation. *Int J Cardiol* 2002;82:179-80.
11. Kyuma M, Tsuchihashi K, Shinshi Y, Hase M, Nakata T, Ooiwa H, et al. Effect of intravenous propranolol on left ventricular apical ballooning without coronary artery stenosis (ampulla cardiomyopathy): three cases. *Circ J* 2002;66:1181-4.