

# Usefulness of the Electrocardiogram in Predicting the Occlusion Site in Acute Anterior Myocardial Infarction with Isolated Disease of the Left Anterior Descending Coronary Artery

Luis Martínez-Dolz, Miguel A. Arnau, Luis Almenar, Joaquín Rueda, Ana Osa, Anastasio Quesada, Joaquín Osa, Esther Zorio, Miguel Palencia and Romualdo Cebolla

Servicio de Cardiología. Hospital Universitario La Fe. Valencia. España.

**Introduction and objectives.** In acute anterior myocardial infarction (AMI), the site of occlusion in the left anterior descending coronary artery (LAD) is related to the extension of myocardial necrosis and the prognosis. The aim of this study was to assess the value of the electrocardiogram (ECG) as a predictor of the LAD occlusion site in patients with anterior AMI.

**Methods.** Forty-five consecutive patients with a first anterior AMI and isolated disease of the LAD were included. We evaluated retrospectively the ECG with the most pronounced ST-segment changes before fibrinolysis and correlated the findings with the site of LAD occlusion in angiography before hospital discharge in relation to the first dominant septal and first diagonal branch: first septal affected (S), first diagonal affected (D), both affected (S + D), or neither affected were considered.

**Results.** ST depression in leads II, III, or aVF strongly predicted proximal LAD occlusion in S + D, S, and D ( $p = 0,003$ ,  $p = 0,04$ , and  $p = 0,02$ , respectively). ST elevation in leads II, III, or aVF was observed only in the presence of wrap-around LAD and was related with occlusion distal to the first diagonal branch. ST elevation  $\geq 3$  mm in lead V1 was a specific predictor of occlusion proximal to first septal (S,  $p = 0,01$ ). ST elevation in aVR was associated with proximal LAD occlusion in S + D and S ( $p = 0,03$  and  $p = 0,03$ , respectively) and absence of coronary collateral circulation.

**Conclusions.** In anterior AMI and isolated LAD disease, the ECG can be useful in predicting the LAD occlusion site in relation to its major side branches.

**Key words:** *Electrocardiography. Myocardial infarction. Angiography.*

Full English text available at: [www.revespcardiol.org](http://www.revespcardiol.org)

Correspondence: Dr. L. Martínez-Dolz.  
Avda. Campanar, 21. 46009 Valencia.  
E-mail: [lmartinezd@meditex.es](mailto:lmartinezd@meditex.es)

Received 18 January 2002.  
Accepted for publication 21 May 2002.

## Utilidad del electrocardiograma para predecir el lugar de la oclusión en el infarto agudo de miocardio anterior con enfermedad aislada de la arteria descendente anterior

**Introducción y objetivos.** En el infarto agudo de miocardio (IAM) anterior, el lugar de la oclusión de la arteria descendente anterior (DA) se relaciona con la extensión de la necrosis y con el pronóstico. El propósito del estudio fue valorar la utilidad del electrocardiograma (ECG) para predecir el lugar de la oclusión de la DA en pacientes con IAM anterior y enfermedad aislada de la DA.

**Métodos.** Estudio retrospectivo en el que se incluyen a 45 pacientes consecutivos con un primer IAM de localización anterior y enfermedad aislada de la DA. Analizamos el ECG que mostró la mayor desviación del segmento ST (ST) previo al tratamiento fibrinolítico y lo correlacionamos con el nivel lesional en la DA en coronariografía realizada antes del alta hospitalaria en relación con la primera septal dominante y primera diagonal, distinguiendo: territorio septal afectado («S»), territorio diagonal afectado («D»), ambos afectados («S + D») o ninguno.

**Resultados.** El descenso del segmento ST en las derivaciones II, III o aVF fue un potente predictor de lesión proximal en la DA en las localizaciones angiográficas «S + D», «S» y «D» ( $p = 0,003$ ,  $p = 0,04$  y  $p = 0,02$ , respectivamente). El ascenso del ST en II, III o aVF únicamente se observó en pacientes con una DA desarrollada que daba la vuelta al ápex y se relacionó con lesión distal a la diagonal dominante ( $p < 0,01$ ). El ascenso del ST en V1  $\geq 3$  mm fue un predictor específico de oclusión proximal a la primera septal («S»,  $p = 0,01$ ). El ascenso del ST en aVR se asoció con afectación de «S + D» y «S» ( $p = 0,03$  y  $p = 0,03$ , respectivamente) y ausencia de circulación colateral al territorio de la DA.

**Conclusiones.** En el IAM anterior y enfermedad exclusiva de la DA, el ECG puede ser una herramienta útil en la predicción del nivel lesional de la DA en relación con sus ramas principales.

**Palabras clave:** *Electrocardiografía. Infarto de miocardio. Angiografía.*

SEE EDITORIAL ON PAGES 1015-7

## ABBREVIATIONS

AMI: acute myocardial infarction  
 ADA: anterior descending artery  
 ECG: electrocardiogram  
 S: first dominant septal artery  
 D: first dominant diagonal artery  
 CPK: creatinphosphokinase  
 ↑ ST: elevation of the ST segment  
 ↓ ST: depression of the ST segment

## INTRODUCTION

In acute myocardial infarction (AMI) of the inferior face, the site of occlusion in the anterior descending coronary artery (ADA) is related to the extent of the myocardial necrosis as well as patient prognosis.<sup>1-3</sup> There have been several studies that attempted to correlate electrocardiogram (ECG) results with the site of the occlusion of the ADA in anterior infarcts; the degree of success of these studies varied, likely because of factors such as the number of vessels affected, the presence or absence of collateral circulation, and the degree of development of each of the coronary territories.<sup>4-6</sup>

The aim of the present study is to analyze the usefulness of ECG for predicting the amount of damage to the ADA in patients with anterior AMI and isolated disease of the ADA.

## METHODS

We studied 52 consecutive patients admitted to our hospital with a diagnosis of anterior AMI, defined as typical chest pain lasting more than 30 minutes, accompanied by an ST segment elevation of 2 mm in at least 2 contiguous leads from the precordial series, an elevation in blood creatinphosphokinase (CPK) at least twice the upper limit of normal, and isolated disease of the ADA on coronary angiography. We excluded from the study patients with complete left branch block of the ST segment on acute ECG, those with left ventricular hypertrophy as determined by the Sokolow index, and patients with electrocardiographic evidence of an old infarct or a subacute infarct. A total of 45 patients remained in the study group who fell within the appropriate parameters. Mean patient age was 59±11 years, and more than 86% of the patients were men.

We analyzed the admission ECG results (standard 12-lead recording, recording velocity 25 mm/second, calibration 1 mV=10 mm) that showed the greatest ST segment changes before the initiation of reperfusion

therapy. The variables analyzed were: ST segment changes at the J point and 80 ms from the J point, intraventricular conduction on acute ECG, and the presence of pathological Q-waves on evolutionary ECG. With regard to ST segment changes, we specifically analyzed those results that, in previous studies, were found to be related to the extent of the damage, specifically: ST segment depression and elevation in leads II, III, or aVF; depression and elevation in leads I or aVL; ST elevation in leads aVR; ST elevation in lead V2 greater than that in V3; ST elevation in V1 of more than 2 or 3 mm; and ST depression and elevation in leads V4, V5, or V6. The level of ST changes was measured manually in each lead, considering the preceding P-Tp segment to be the isoelectric line. The measurements from 3 successive heartbeats were averaged by an observer who was blinded to the angiographic findings.

Coronary angiography was performed an average of 6 days after the acute episode (range, 1 to 13 days) in all patients after receiving thrombolytic treatment, which was administered in 40 of the 45 patients. The angiographic variables (which were analyzed by an observer who was blinded to the electrocardiographic findings) were: location of the causative AD lesion (defined as the most serious stenosis with a residual thrombus or ulcerated plaque) in association with the dominant septal and first diagonal arteries, development of the AD and diagonal arteries, segment contractility changes, and qualitative analysis of overall systolic function of the left ventricle on ventriculography.

Anatomic variability of the coronary tree meant that in some patients the dominant septal artery had its origin in the anterior descending artery before the outlet of the dominant diagonal artery (proximal to the diagonal artery), while in other cases its origin was distal to the diagonal artery. In our study, the lesion was proximal to both the septal and diagonal arteries in 14 patients; proximal to the septal artery and distal to the diagonal artery in 10 patients; proximal to the diagonal artery and distal to the septal artery in 11 patients; and distal to both the septal and diagonal arteries in the remaining 10 patients. We analyzed the predictive capacity of electrocardiographic changes with regard to 4 possible angiographic findings: *a*) the area of the septal and diagonal arteries involved (S+D, 14 patients) vs the remaining patients (31); this enabled evaluation of the proximal ADA damage with all involved areas in situations where some dependent area of the ADA was safeguarded; *b*) the area of the septal artery area involved (S) by means of proximal lesion at the origin of the septal artery (14+10) vs the other patients; *c*) the area of the diagonal artery involved (D) via proximal damage to the origin of the diagonal artery (14+11) vs the other patients, and *d*) none of the areas involved by damage distal to the septal and diagonal arteries (10 patients).

**TABLE 1. Demographic, clinical, and angiographic data of the study population**

	S+D	S	D	None
N	14	24	25	10
Age	60 (44-70)	56 (29-70)	57 (32-71)	60 (46-71)
Men				
%	93	92	84	80
Dom, r/l/e	11/2/1	19/4/1	20/2/3	8/1/1
ADA apex	9	13	17	6
Collat. c.	5	8	10	4
LVF, g/n/b	1/10/3	6/14/4	4/17/4	5/2/3
Max CPK	2803±2248	2292±1687	2673±2165	1605±1113
ECG t.	3.1±2.1	2.9±2.3	3.3±2.7	3.1±2.8

N indicates number of patients; S, affected area of the first septal artery; D, affected area of the first diagonal artery; S+D, both areas affected; None, none of the areas affected (lesion distal to the septal and diagonal arteries); Dom, coronary dominance; r/l/e, right/left/equal; ADA apex, wrap-around anterior descending artery (around the apex); Collat. C, collateral circulation; LVF, left ventricle function; g/n/b, good/normal/bad; Max CPK, maximum serum creatinphosphokinase (U/L); ECG t., time elapsed before ECG was performed (in hours).

The continuous variable data is expressed as mean±standard deviation and the categorical variables are expressed as percentages. For the comparison of categorical variables, we used the  $\chi^2$  test or the exact Fisher test, and we used the Student *t* test for comparison of continuous variables. A value of  $P<.05$  was considered statistically significant. The 95% confiden-

ce intervals (CI) for the sensitivity and specificity values were obtained by means of the binomial theorem.

## RESULTS

The baseline patient characteristics are shown in Table 1. The patient subgroups were comparable with regard to mean age, sex, coronary dominance, ADA development, the presence of collateral circulation, and the amount of time that elapsed between the start chest pain and performance of an ECG. We observed a tendency to a larger CPK peak and worse overall left ventricular systolic function in patients who had proximal lesions compared with those in whom none of the areas was affected.

Table 2 shows the electrocardiographic parameters that were related in a statistically significant manner to each of the angiographic findings documented.

### ↓ ST IN LEADS II, III OR AVF

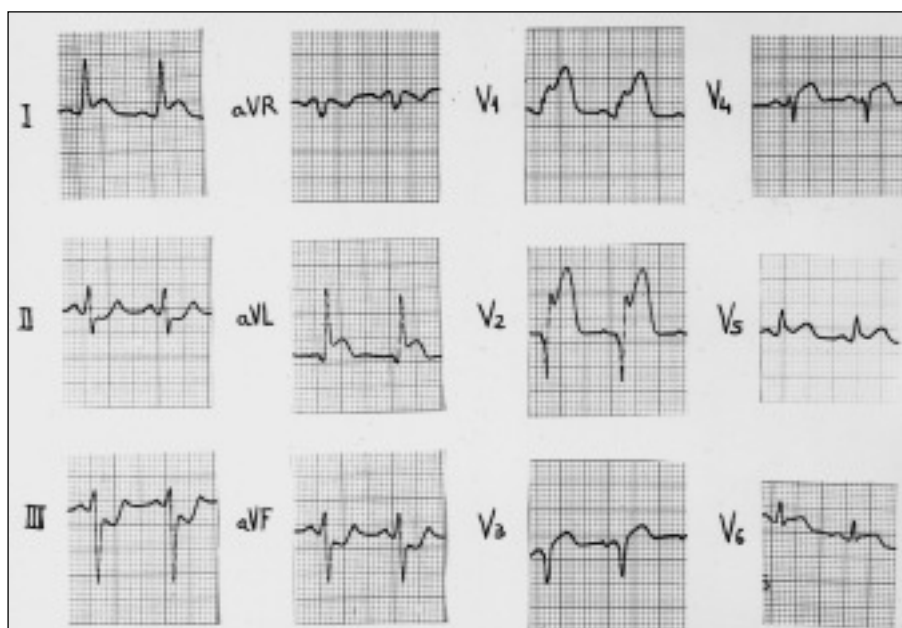
ST in leads II, III, or aVF measured both at the level of the J point and at 80 ms from the J point that was greater than 0.5 to 1 mm was a predictor of damage proximal to the septal and diagonal arteries (S+D), with a sensitivity of 79% and specificity of 71% ( $P=.002$ ) when the cut-off point was a depression of more than 1 mm in the J point.

Similarly, the ↓ ST ST in leads II, III, or aVF re-

**TABLE 2. Electrocardiographic predictors of the occlusion site in the descending anterior artery**

	↓ ST II, III, aVF			↑ ST aVR	
	≥1 mm-J	≥0,5 mm-J	≥0,5 mm-80 J	≥0,5 mm-80 J	≥3 mm-80 J
S+D					
S	79 (49-95)	86 (57-98)	86 (57-98)	36 (11-61)	21 (5-51)
E	71 (55-87)	55 (37-72)	61 (44-78)	90 (74-98)	90 (74-98)
LPT	2.7	1.9	2.2	3.6	2.1
P	.002	.01	.003	.03	.3
S					
S	58 (39-78)	71 (53-89)	71 (53-89)	29 (11-47)	25 (8-42)
E	71 (52-91)	57 (36-78)	67 (47-87)	95 (76-100)	100 (84-100)
LPT	2	1.7	2.2	5.8	
P	.04	.06	.01	.03	.01
D					
S	60 (41-79)	72 (54-90)	68 (50-86)	20 (4-36)	12 (3-31)
E	75 (56-94)	60 (39-81)	65 (44-86)	85 (62-97)	85 (62-97)
LPT	4	1.8	1.9	1.3	0.8
P	.02	.03	.03	.7	.8
None					
S	20 (3-56)	30 (2-58)	20 (3-56)	10 (0-45)	0 (0-31)
E	49 (32-65)	34 (19-50)	37 (21-53)	80 (67-93)	83 (70-95)
LPT	0.39	0.45	0.32	0.5	0
P	.14	.07	.03	.6	.3

S+D indicates septal and diagonal artery areas affected (occlusion proximal to both) with respect to any situation where a respective area was affected; S, affected septal artery area; D, affected diagonal artery area; None, none of the territories affected (lesion distal to the septal and diagonal arteries); ST, ST segment; J, J point; S, sensitivity (percentage and 95% confidence interval); E, specificity (percentage and 95% confidence interval); LPT, likelihood preference test (in the presence of specified criteria); P, significance level.



**Fig. 1.** ECG of a patient with AMI of the anterior face and proximal occlusion of the ADA. Marked ST segment depression is seen in the inferior face leads.

regardless of the point of measurement and the amount (0.5 to 1 mm) was significantly associated manner with damage proximal to the septal artery (S), with an acceptable sensitivity of 58% and an acceptable specificity of 71% (for a depression of more than 1 mm in the J point).

↓ ST in leads II, III, or aVF was also associated in a significant manner with damage proximal to the dominant diagonal artery (D), with an acceptable sensitivity of 60% and an acceptable specificity of 75% (for an ST depression of more than 1 mm in the J point).

#### ↑ ST IN LEAD aVR

↑ ST in lead aVR  $\geq 0.5$  mm at 80 ms from the J point was shown to be a specific (90%) measurement for a proximal lesion in S+D ( $P=.03$ ).

↑ ST in lead aVR  $\geq 0.5$  mm at 80 ms from the J point was equally specific (95%) for a lesion proximal to S, although it has a low sensitivity (29%).

#### ↑ ST IN LEAD V1

↑ ST in lead V1  $\geq 3$  mm at 80 ms from the J point was shown to be a specific measurement (100%) for the affected septal area, present in 25% of the proximal lesions and in none of the lesions distal to the dominant septal artery ( $P=.01$ ).

#### Other findings

↑ ST in leads II, III, or aVF occurred in 7 of the 45 patients studied, and in all patients we observed the presence of a developed wrap-around ADA (around the apex) (30% sensitivity, 100% specificity, positive

predictive value [PPV] 100%, negative predictive value [NPV] 46%;  $P=.016$ ); in all cases, the area of the diagonal artery was observed (lesion distal to the diagonal artery). The ST segment depression in leads II, III, or aVF ( $>0.5$  or 1 mm, measured in the J point or at 80 ms from the J point) continued to be a good predictor of damage proximal to the septal and diagonal arteries in this subgroup of patients ( $P=.003$ ).

We confirmed the presence of collateral circulation in 17 patients, we did not find an ST segment elevation in the lead aVR in any of them, whether or not the first dominant septal artery was compromised (8 patients compromised; 9 not compromised). On the other hand, the presence of ST segment elevation in lead aVR (8 patients) was specific (92%) for a lesion proximal to the dominant septal artery in the subgroup of patients without collateral circulation to the ADA (28).

#### DISCUSSION

The clinical usefulness of obtaining electrocardiography markers for the level of damage in the ADA in an anterior AMI is based on identifying those patients with a proximal occlusion who, therefore, require more aggressive treatment with revascularization in order to prevent more extensive myocardial damage. The implication for patient prognosis is clear.

In our study, a decrease in ST segment in the inferior face proved to be an excellent predictor of a proximal ADA lesion (Figure 1), including in the presence of a developed wrap-around vessel around the apex. An ST segment elevation in lead V1 of more than 3 mm appears to be a specific finding for damage proximal to the dominant septal artery, while an ST segment elevation in lead aVR is associated with compro-

mise of the dominant septal artery and the absence of collateral circulation.

The presence of an ST segment depression in the inferior face in the setting of an anterior AMI is a parameter that in previous studies<sup>4,7,8</sup> predicted the existence of an occlusion proximal to the dominant first septal and diagonal arteries. In our study, this parameter was equally shown to be a predictor of a proximal lesion starting with an ST depression of 0.5 mm measured both in the J point and 80 ms from the J point. There is controversy about the significance of this parameter. Thus, the magnitude of the ST depression in the inferior face was correlated with the site of the ADA occlusion,<sup>5,6,8-10</sup> with the degree of ST elevation in the precordial leads (reciprocal effect), and with the seriousness of the ischemia of the anterior wall,<sup>10</sup> and was associated with a larger area of infarction, increased morbidity, and a worse prognosis.<sup>11-13</sup> It has also been correlated with a greater prevalence of 3-vessel disease<sup>11</sup> and with concomitant dependent inferior ischemia of the right coronary or circumflex artery (ischemia at a distance).<sup>11,13</sup> In our study, in all those patients who presented with only AD disease, the ST segment depression in the inferior face probably represents reciprocal repolarization changes associated with transmural ischemia in the upper part of the anterobasal wall of the left ventricle, which has been described in other studies in the context of multi-vessel disease.<sup>4,14,15</sup>

On the other hand, in our study ST segment elevation in the inferior face was invariably associated with the presence of a developed wrap-around ADA (around the apex), as well as the presence of a lesion distal to the dominant diagonal artery ( $P<.01$ ). In addition, even in the patients in which a wrap-around ADA (around the apex) was observed, the presence of ST segment decline (both  $>0.5$  and  $>1$  mm), measured in the J point or at 80 ms from the J point, reliably predicted a lesion proximal to the septal and diagonal arteries ( $P=.003$ ). It is likely that this finding is a result of the fact that the amount of ischemia in the anterobasal wall surpassed the ischemia of the inferior wall. Therefore, in spite of the existence of a wrap-around ADA (around the apex), the presence of a distal occlusion in this vessel would be a pre-requisite for observing an isoelectric or elevated ST in the inferior face leads, which has also been observed in similar studies.<sup>4,10,16,17</sup>

ST segment elevation in lead V1  $\geq 3$  mm measured at 80 ms from the J point is associated in a statistically significant manner with a lesion proximal to the dominant septal artery, with 100% specificity. In a previous study<sup>4</sup> it was observed that ST elevation in lead V1  $>2.5$  mm was, together with ST depression in lead V5, the only electrocardiographic parameter on analysis of the ST leads in the precordial series, capable of discriminating between a proximal and a distal lesion in the first dominant septal artery in the individual pa-

tient.

ST elevation in lead aVR of more than 0.5 mm measured at 80 ms from the J point was shown in our study to be a specific parameter of the involvement of the S+D (90%) and S (95%) areas. This data concurs with the study by Engelen et al,<sup>4</sup> where ST elevation in lead aVR had a 95% specificity for the prediction of an ADA lesion proximal to the origin of the dominant septal artery, attributing this to be most likely due to transmural ischemia of the basal septum (a lesion usually oriented toward the right shoulder). When we analyzed the presence or absence of collateral circulation, we observed that in all patients with collateral circulation there was no ST elevation in lead aVR whether or not the septal artery was compromised. Nevertheless, in the subgroup of patients without collateral circulation (and, therefore, with greater and obvious ischemia of the basal segments of the septum), the presence of ST elevation in lead aVR was specific (92%) for a lesion proximal to the septal artery. Although the limited number of patients included in the study does not allow us to draw definitive conclusions, ST elevation  $>0.5$  mm at 80 ms from the J point is associated with compromise of the first dominant septal artery and the absence of collateral circulation.

The presence of pathological Q-waves in leads V4 through V6, associated in some studies<sup>4</sup> with distal occlusion of the dominant septal artery, was not related to level of damage in the ADA. Similarly, the presence of Q-waves in the entire precordial series, probably because it was only observed in 7 patients, was also not associated with the lesion level, the presence or absence of collateral circulation, or the residual systolic function of the left ventricle.

The presence of a right branch block of the bundle of His in the context of an anterior AMI has been correlated with the existence of an occlusion of the ADA proximal to the dominant septal artery,<sup>4</sup> although in our study we were unable to analyze this due to the small number of patients (4) who presented with this deficit.

Contrary to other studies that correlated electrocardiographic findings in the context of an anterior AMI that may have been limited by the presence of additional ischemia in other coronary territories, our study is novel because our study population is composed exclusively of patients with ADA disease. On the other hand, the application of these electrocardiographic findings is limited to that population, whose coronary anatomy would be known *a posteriori*.

The fundamental limitation of this study is the small number of patients analyzed who could be divided into 4 principal groups and some secondary groups (such as the presence or absence of collateral circulation, AD development, left ventricular function, etc.), that would predict limitations in the reproducibility of the

findings. Another aspect to take into account is the early point at which we obtained both the ECG in the acute phase (an average of 3 hours after initiation of the clinical state) and the coronary angiography that permitted identification of the lesion responsible, so that we do not know whether our findings would be equally applicable in records obtained at a later date.

## REFERENCES

- Gaudron P, Eilles C, Kugler I, Ertl G. Progressive left ventricular dysfunction and remodeling after myocardial infarction: potential mechanisms and early predictors. *Circulation* 1993;87:755-63.
- Jeremy RW, Allman KC, Bautovitch G, Harris PJ. Patterns of left ventricular dilation during the six months after myocardial infarction. *J Am Coll Cardiol* 1989;13:304-10.
- Pirollo JS, Hutchins GM, Moore GW. Infarct expansion: pathologic analysis of 204 patients with a single myocardial infarct. *J Am Coll Cardiol* 1986;7:349-54.
- Engelen D, Gorgels A, Cheriex E, De Muinck E, Oude A, Dassen W, et al. Value of the electrocardiogram in localizing the occlusion site in the left anterior descending coronary artery in acute anterior myocardial infarction. *J Am Coll Cardiol* 1999;34:389-95.
- Arbane M, Goy JJ. Prediction of the site of total occlusion in the left anterior descending coronary artery using admission electrocardiogram in anterior wall acute myocardial infarction. *Am J Cardiol* 2000;85:487-91.
- Birnbaum Y, Slarovsky S, Solodky A, Tschori J, Herz I, Sulkes J, et al. Prediction of the level of left anterior descending coronary artery obstruction during anterior wall acute myocardial infarction by the admission electrocardiogram. *Am J Cardiol* 1993;72:823-6.
- Birnbaum Y, Solodky A, Herz I, Kusniec J, Rechavia E, Sulkes J, et al. Implications of inferior ST-segment depression in acute anterior myocardial infarction: electrocardiographic and angiographic correlation. *Am Heart J* 1994;127:1467-73.
- Tamura A, Kataoka H, Mikuriya Y, Nasu M. Inferior ST-segment depression as a useful marker for identifying proximal left anterior descending coronary artery occlusion during acute anterior myocardial infarction. *Eur Heart J* 1995;16:1795-9.
- Birnbaum Y, Solodky A, Herz I, Kusniec J, Rechavia E, Sulkes J, et al. Implication of inferior ST-segment depression in anterior acute myocardial infarction: electrocardiographic and angiographic correlation. *Am Heart J* 1994;127:1467-73.
- Lew AS, Hod H, Cercek B, Shah PK, Ganz W. Inferior ST segment changes during acute anterior myocardial infarction: a marker of the presence or absence of concomitant inferior wall ischemia. *J Am Coll Cardiol* 1987;10:519-26.
- Haraphongse M, Tanomsup S, Jugdutt BI. Inferior ST segment depression during acute anterior myocardial infarction: clinical and angiographic correlations. *J Am Coll Cardiol* 1984;4:467-76.
- Willens JL, Willems RJ, Willems GM, Arnold AER, Van de Werf F, Verstraete M. Significance of initial ST segment elevation and depression for the management of thrombolytic therapy in acute myocardial infarction. *Circulation* 1990;82:1147-58.
- Kyriakidis M, Antonopoulos A, Barbetseas J, Aspioris N, Georgiakodis F, Sfrikakis P, et al. Correlation of reciprocal ST-segment depression after acute myocardial infarction with coronary angiographic findings. *Int J Cardiol* 1992;36:163-8.
- Fletcher WO, Gibbons RJ, Clements IP. The relationship of inferior ST depression, lateral ST elevation, and left precordial ST elevation to myocardium at risk in acute anterior myocardial infarction. *Am Heart J* 1993;126:526-35.
- Quyyumi AA, Crake T, Rubens MB, Levy RD, Rickards AF, Fox KM. Importance of reciprocal electrocardiographic changes during occlusion of the left anterior descending coronary artery: studies during percutaneous transluminal coronary angioplasty. *Lancet* 1986;15:347-50.
- Sapin PM, Musselman DR, Dehmer GJ, Cascio WE. Implications of inferior ST-segment elevation accompanying anterior wall acute myocardial infarction for the angiographic morphology of the left anterior descending coronary artery morphology and site of occlusion. *Am J Cardiol* 1992;69:860-5.
- Tamura A, Kataoka H, Nagase K, Mikuriya Y, Nasu M. Clinical significance of inferior ST elevation during acute anterior myocardial infarction. *Br Heart J* 1995;74:611-4.