

Virtual Histology of an Acute Thrombotic Occlusive Lesion

To the Editor:

Virtual histological reconstruction by intravascular ultrasound (VH-IVUS) is a validated technique that allows us to determine the histological composition of coronary atherosclerotic plaque.¹ Fibrous tissues are coloured green, fibro-fatty tissue yellow, calcium in white, and the necrotic lipid core red.² This technique, which is still being developed, has some serious limitations, such as its inability to differentiate calcium from metal stents, or its lack of characterisation of thrombotic material.

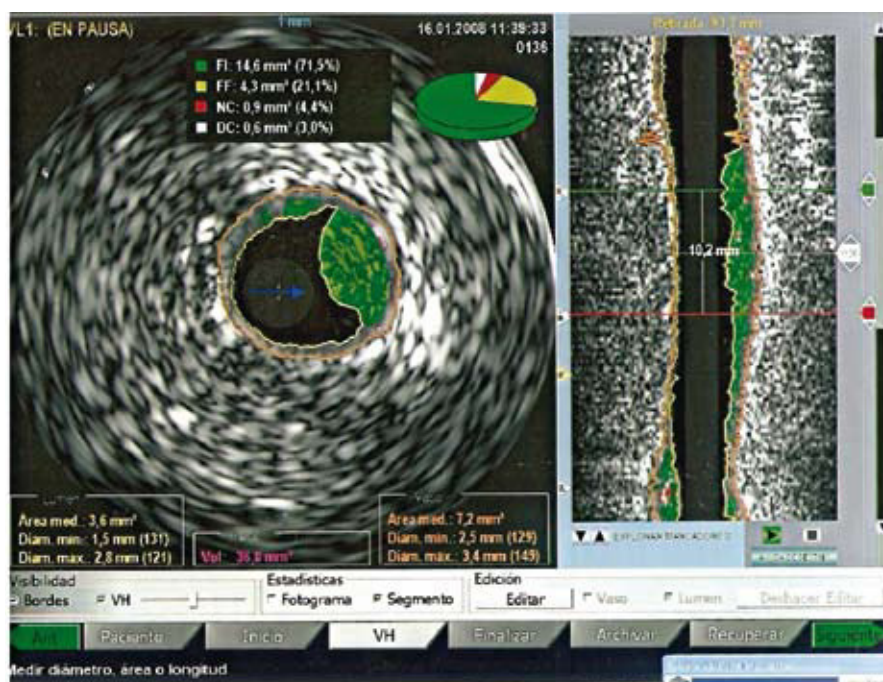
Our patient is a 60 year-old diabetic woman with a STEMI that had been evolving over 6 h, who was referred to our laboratory for primary angioplasty. The diagnosis showed a single acute occlusive thrombotic lesion in the middle of the anterior descending artery (DA) with a distal flow of TIMI 0. By passing a BMW wire toward the distal DA, we achieved a flow of TIMI 1; the angiograph shows a clear image of the thrombus, measuring 10 mm in length, and attached to the arterial wall distal to the occlusion site. We performed an VH-IVUS (Figure 1) with automatic removal to analyse a 40.2 mm long segment from the edge of the plaque causing the ischaemic event to the end of the image of the thrombus attached to the arterial wall. Firstly, 5 mm from the edge of the plaque, we found a section with the image of a type IV thin-cap fibroatheroma with a 36%

necrotic core near the lumen with no evidence of a fibre cap, a calcium component of 26.9%, a 55% plaque content, and positive remodelling of 1.06. Posteriorly and distally, we find the most stenotic zone, with a luminal area of 2.1 mm.² Further on, there is a 10.2 mm segment that corresponds angiographically with the image of the thrombus, and which in the IVUS appears as plaque, mostly coloured in green. As the next step in the intervention, we used a thrombus extraction device and managed to capture a large thrombus (8 mm). In the next angiographic sequence the image of the thrombus did not appear, and VH-IVUS was performed again after the extraction (Figure 2). The intervention concluded with the implantation of a stent. Posterior clinical evolution was good.

Based on the ultrasound studies, both before and after the aspiration, we compared the same 10.2 mm long segment, with the same proximal and distal limits (in reference to the edge of the plaque), which covered 285 frames.

In the first study (prior to aspiration) we can see a luminal obstruction (plaque and thrombus) with a total volume of 36.8 μ L, with 71.5% colour-coded in green, 21.1% yellow, 4.4% red, and 3% in white. In the second (after aspiration), the obstruction has a volume of 32.1 μ L, with 75% colour-coded in green, 22.9% yellow, 1.3% red, and 0.9% white. Both studies showed transverse a similar composition for the lesion, which is mostly coded green and to a lesser extent, yellow, and we see the resulting reduction in the total volume of material after effective aspiration of the thrombus.

Figure 1. Intravascular echography image before aspirating the thrombus with a transverse slice on the left and longitudinal on the right. Here, after 3 h, we can see the thrombus protruding at vesicular lumen, mostly coloured green. The orange line outlines the external elastic lamina of the coronary artery wall, and the yellow line delimits the luminal border. In the upper part, circular sectors with the distribution of each of the identified tissue components.



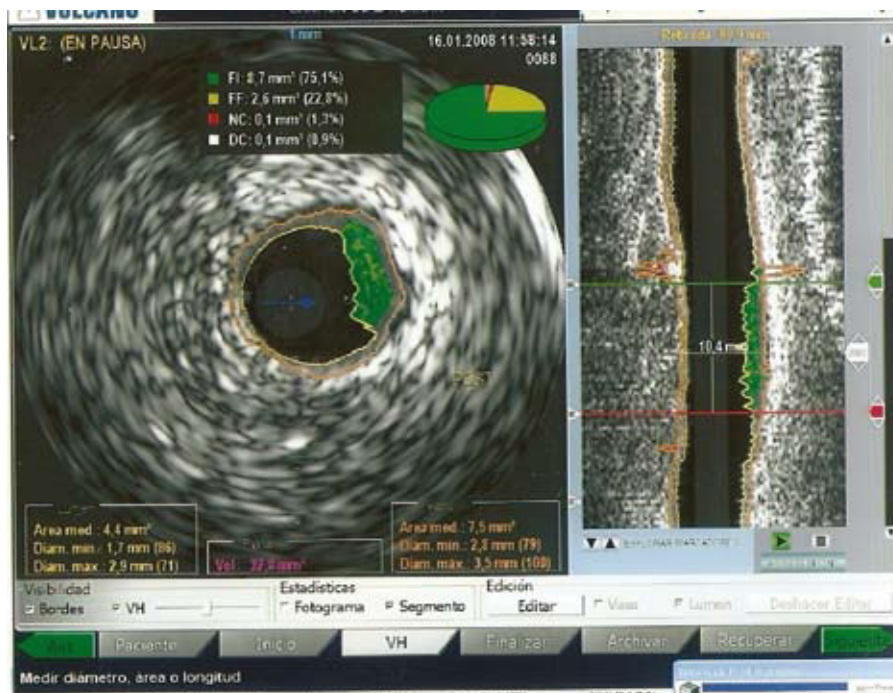


Figure 2. After aspiration of the thrombus, the transverse slice (to the left), performed in the same point as in the previous study, shows a reduction in the load of plaque with an increase in luminal area. Likewise, in the longitudinal slice we can see a reduction in the green-coloured area.

By analysing the volumetric figures for the segment and the images of the longitudinal slice, as well as the transversal slice at the most obstructed point of the lumen using conventional IVUS and VH-IVUS, we conclude that the thrombotic material extracted from the patient's DA was for the most part coded wrong by the ultrasound and coloured green, as if it were fibrous tissue. However, it is possible to deduce the approximate volume of the extracted thrombus by subtracting both total volumes, which gives us 4.7 μL .

As a result, we find that VH-IVUS is a useful tool for studying the composition of coronary plaque,³ but it should be perfected technically for use in further studies that may help us to predict the plaque's instability, vulnerability,⁴ and complications.

José D. Cascón-Pérez, Luciano Consuegra,
and Francisco Picó-Aracil

Unidad de Hemodinámica, Hospital Universitario Santa María del Rosell,
Cartagena, Murcia, Spain

REFERENCES

1. Virmani R, Kolodgie FD, Burke AP, Farb A, Schwartz SM. Lessons from sudden coronary death. A comprehensive morphological classification scheme for atherosclerotic lesions. *Arterioscler Thromb Vasc Biol.* 2000;20:1262-75.
2. Nasu K, Tsuchikane E, Katoh O, Vince DG, Virmani R, Surmely JF, et al. Accuracy of in vivo coronary plaque morphology assessment. A validation study of in vivo virtual histology compared with in vitro histopathology. *J Am Coll Cardiol.* 2006;47:2405-12.
3. Surmely JF, Nasu K, Fujita H, Terashima M, Matsubara T. Coronary plaque composition of culprit/target lesions according

to the clinical presentation: a virtual histology intravascular ultrasound analysis. *Eur Heart J.* 2006;27:2939-44.

4. Kari I. Saunamaki. Virtual histology and the hunt for the vulnerable plaque. *Eur Heart J.* 2006;27:2914-29.