

Aspergillus fumigatus Endocarditis in a Patient With a Biventricular Pacemaker

José M. Cuesta,^a María C. Fariñas,^b Irene G. Rodilla,^c Ricardo Salesa,^d and José R. de Berrazueta^a

^aServicio de Cardiología, Hospital Universitario Marqués de Valdecilla, Santander, Cantabria, Spain.

^bServicio de Enfermedades Infecciosas, Hospital Universitario Marqués de Valdecilla, Santander, Cantabria, Spain.

^cServicio de Anatomía Patológica, Hospital Universitario Marqués de Valdecilla, Santander, Cantabria, Spain.

^dServicio de Microbiología, Hospital Universitario Marqués de Valdecilla, Santander, Cantabria, Spain.

Aspergillus fumigatus endocarditis is one of the rarest and severest complications in cardiological patients. We describe a patient with an intracardial pacemaker who was diagnosed as having *Aspergillus fumigatus* endocarditis. Postmortem examination showed a large, *Aspergillus*-infected thrombus encased in the right ventricle, pulmonary trunk, and main pulmonary branches.

Key words: *Aspergillus fumigatus*. Endocarditis. Pacemaker.

Endocarditis por *Aspergillus fumigatus* en un marcapasos bicameral

La endocarditis por *Aspergillus fumigatus* es una de las complicaciones más raras y severas que puede presentar un paciente cardiológico. Presentamos el caso de una paciente portadora de marcapasos endocavitario diagnosticada de endocarditis por *Aspergillus*. El estudio *post mortem* mostró un trombo infectado por *Aspergillus* que ocupaba el ventrículo derecho, así como la arteria y las ramas de la arteria pulmonar.

Palabras clave: *Aspergillus fumigatus*. Endocarditis. Marcapasos.

INTRODUCTION

Fungal endocarditis forms an estimated 2%-6% of all endocarditis¹ and less than 1% of fungal endocarditis occurs in pacemaker carriers.² Diagnosis is difficult and when the infecting fungus is *Aspergillus fumigatus* mortality can be >90%.³ We present the case of a female pacemaker carrier who developed fatal *A fumigatus* endocarditis.

CLINICAL CASE

Seventy-four-year-old woman with a bicameral pacemaker implanted 5 years earlier. Five months before admission she began to present intermittent fever and shivering. Physical exploration was normal whereas blood analysis showed modest white cell count and high ESR (105 mm); serology, antibodies and tumor markers were normal. Transthoracic echocardiogram did not show vegetations. Chest x-ray

showed calcification compatible with granuloma in right upper lung (RUL) lobe; 2 months later a new mass appeared next to the calcification. Computerized thoracic tomography (CT) showed a 15-mm calcified granuloma together with small infiltrates attached to the RUL and left lung, and right pleural swelling. Sputum culture and a series of 3 Ziehl-Neelsen smears were negative despite which tuberculostatic treatment was started. One month later the patient again presented fever leading to her being hospitalized for further study.

Mobile images compatible with vegetations adhering to the pacemaker lead were observed with transesophageal echocardiogram. On the second day following admission, *Staphylococcus hominis* was isolated in 2 blood cultures and antibiotic treatment was initiated with vancomycin, rifampicin, and gentamycin. One week later, due to the persisting fever, she underwent surgery and the pacemaker, its leads, and numerous vegetations in the right cavities removed. A new epicardial pacemaker was implanted. Anatomopathological study showed abundant fungal hyphae, compatible with *Aspergillus*, that also grew in the blood cultures. Treatment started with intravenous liposomal amphotericin B while continuing antibiotic treatment for *Staphylococcus*. Complications arose due to *Escherichia coli* pneumonia, septic shock,

Correspondence: Prof. J.R. Berrazueta.
Servicio de Cardiología. Hospital Universitario Marqués de Valdecilla.
Avda. Marqués de Valdecilla, s/n. 39008 Santander. Cantabria. España.
E-mail: jose.berrazueta@unican.com

Received March 24, 2004.

Accepted for publication October 5, 2004.

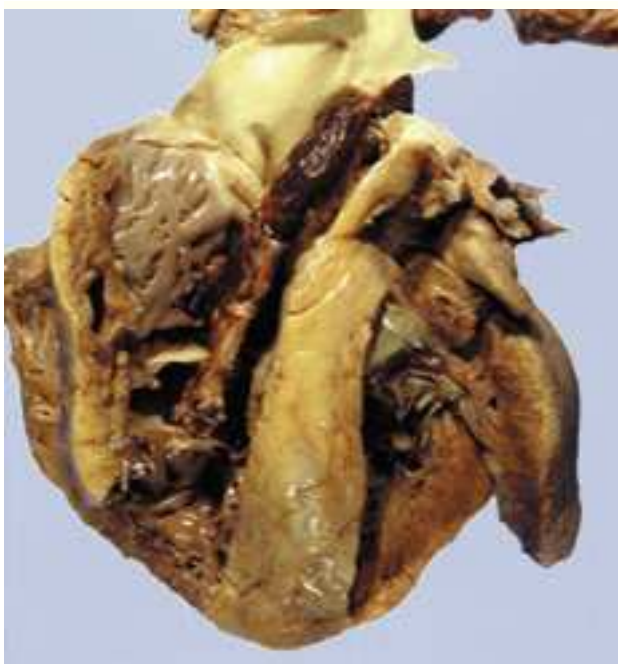

Figure 1. Heart with a large thrombus encased in the right ventricle that extends to and occupies the trunk of the pulmonary artery.

right-sided heart failure, and kidney failure. Ten days later the patient died.

The autopsy revealed a large embolus encased in the right ventricle occluding the pulmonary trunk and both branches of the pulmonary artery (Figure 1). Histological study showed the presence of a large amount of *Aspergillus* spores and hyphae in this thrombus (Figure 2), granulomatous arteritis with giant cell reaction in the presence of fungus, aspergilloma in the left lung, and multiple pulmonary microemboli in different stages of development and acute bilateral broncopneumonia foci.

DISCUSSION

The present case is unique due to the following factors: the difficulty involved in its diagnosis despite following a strict diagnostic protocol; *Aspergillus* infection is the least frequent pacemaker endocarditis³; and, as in our case, the diagnosis was made mainly with the material extracted from the infected lead⁴ or during necropsy.⁵

Vegetations easily become emboligenic, as suggested in our patient by the thoracic TC lung images and confirmed by necropsy. Transthoracic echocardiography did not lead to the diagnosis during the first examination, whereas transesophageal echocardiography

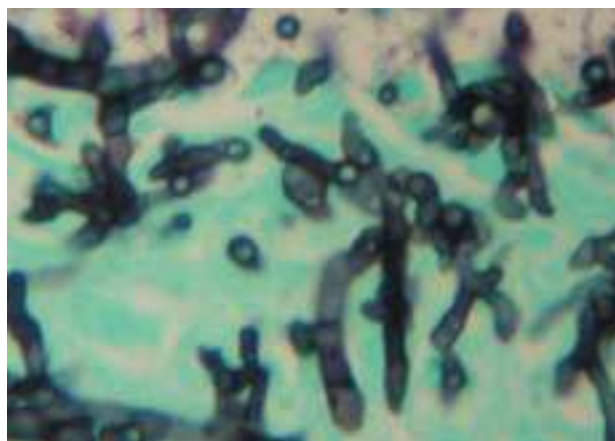


Figure 2. Histological section of the thrombus showing abundant branched and septate hyphae forming part of the thrombotic material (hematoxylin-eosin).

was useful in this regard some months later. The fatal outcome is consonant with the high mortality referred to, despite having used the recommended surgical treatment plus medical treatment with amphotericin B.⁶

Our patient had all the characteristics presented by this fungal infection, such as diagnostic delay despite following a rigorous diagnostic protocol for febrile syndrome, the long duration of the symptoms before hospitalization, the initial negative results in blood cultures, the presence of extracardiac manifestations in the form of septic embolizations, and the death of the patient as the final outcome following a desperate attempt at treatment.

REFERENCES

1. Ramírez Moreno A, Anguita Sánchez M, Castillo Domínguez JC, Siles Rubio JR, Torres Calvo F, Vallés Belsué F. Endocarditis por hongos en pacientes no adictos a drogas por vía parenteral. Nuestra experiencia en 10 años. *Rev Esp Cardiol.* 2000;53:507-10.
2. Pierrotti LC, Baddour LM. Fungal endocarditis, 1995-2000. *Chest.* 2002;122:302-10.
3. Roux JP, Koussa A, Cajot MA, Marquette F, Goullard L, Gosselin B, et al. Primary *Aspergillus* endocarditis. Case report and review of the international literature. *Arch Chir Thorac Cardiovasc.* 1992;46:110-5.
4. Acquati F, Semeraro F, Respighi E, Gallotti R, Repetto S, Binaghi G. *Aspergillus flavus*-infection of a pacemaker wire: continuing evidence for active management of infected pacemakers. *G Ital Cardiol.* 1987;17:467-8.
5. Kramer L, Rojas-Corona RR, Sheff D, Eisenberg ES. Disseminated aspergillosis and pacemaker endocarditis. *Pacing Clin Electrophysiol.* 1985;8:225-9.
6. Wilson HA Jr, Downes TR, Julian JS, White WL, Haponik EF. *Candida* endocarditis. A treatable form of pacemaker infection. *Chest.* 1993;103:283-4.