

Image in cardiology

Complete Resorption After Implantation of Multiple Overlapped Scaffolds

Reabsorción completa tras implante de múltiples armazones solapados

Livia Luciana Gheorghe,* Marcelo Jiménez Kockar, and Antonio Serra Peñaranda

Servicio de Cardiología Intervencionista, Hospital de la Santa Creu i Sant Pau, Barcelona, Spain

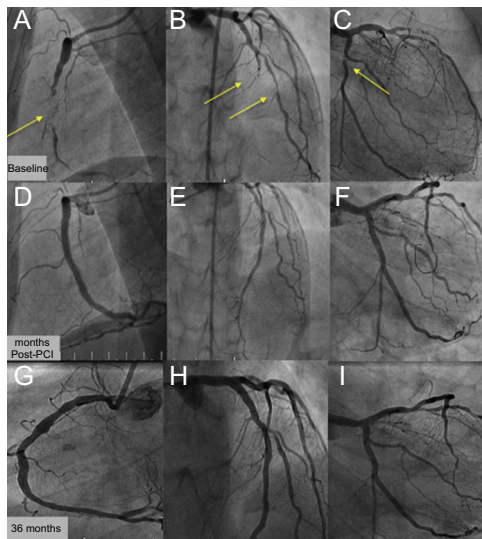


Figure 1.

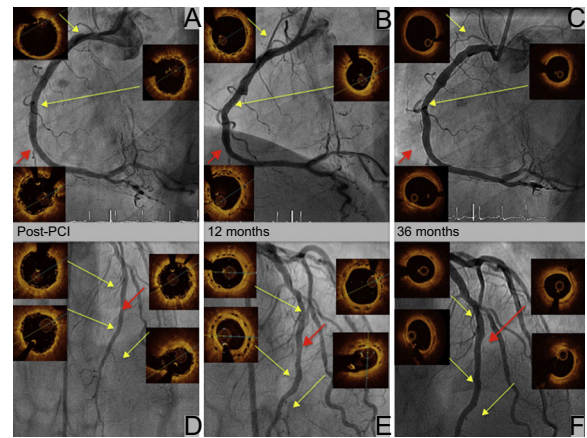


Figure 2.

We present the case of a 36-year-old woman with familial dyslipidemia, a positive ischemia induction test and multivessel coronary artery disease, chronic occlusion of the right coronary artery and left anterior descending artery, with lesions in the diagonal branch and circumflex artery (Figure 1A-C, yellow arrows). The patient was entered in the ABSORB-CTO study and underwent complete percutaneous coronary intervention (PCI) with 8 bioresorbable vascular scaffolds (BVS): 4 in the right coronary artery (Figure 1D and Figure 2A), 2 in the left anterior descending artery (Figure 1E and Figure 2D), 1 in the diagonal branch and 1 in the circumflex artery (Figure 1F). Optical coherence tomography was also performed after the procedure and at 12 and 36 months. Dual antiplatelet therapy was continued for 3 years. At 12 months, the struts of the right coronary artery and left anterior descending artery were endothelialized (Figure 2B and E, yellow arrows), well apposed, and had more intimal hyperplasia in the overlap area (Figure 2B and E, red arrows). At 36 months, all segments remained free from restenosis (Figure 1G-I) and optical coherence tomography showed resorption of the struts (Figure 2C and F, yellow arrows), with dissolved black boxes, including the area of overlap (Figure 2C and F, red arrows).

This case of a young woman with multivessel coronary disease and complete percutaneous revascularization with 8 BVS (194 mm scaffold) shows the excellent long-term outcome with resorption of the scaffolds.

The option of using BVS in cases such as this is attractive. Nonetheless, in light of the recent withdrawal of BVS, further studies are required to show their benefit and long-term efficacy.

* Corresponding author:
E-mail address: livia_gheorghe_ro@yahoo.es (L.L. Gheorghe).
Available online 5 May 2018