

Image in cardiology

Coronary Aneurysm After Paclitaxel-eluting Balloon Angioplasty



Aneurisma coronario tras angioplastia con balón recubierto de paclitaxel

Salvador Montalbán Larrea, Francisco J. Lacunza Ruiz,* and Eduardo Pinar Bermúdez

Servicio de Cardiología, Hospital Universitario Virgen de la Arrixaca, El Palmar, Murcia, Spain

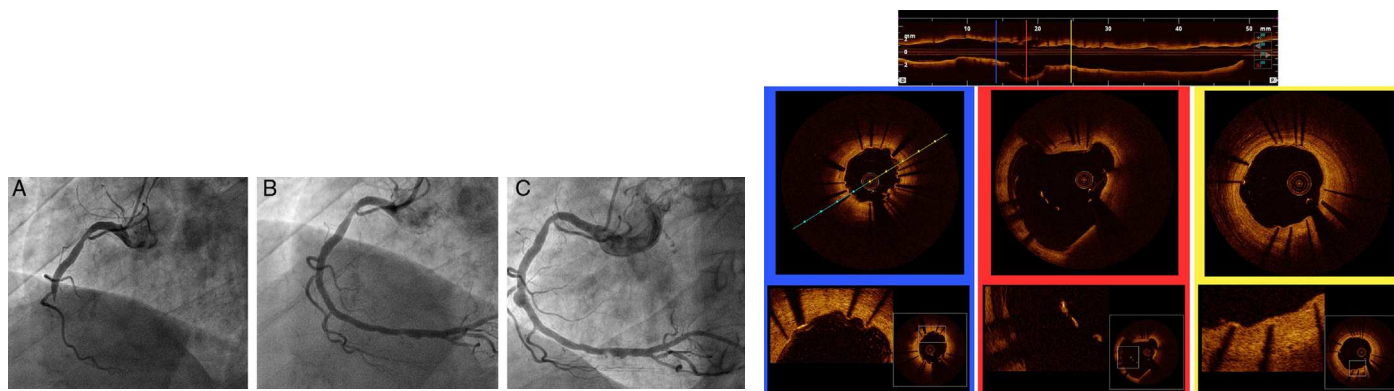


Figure 1.

Figure 2.

A 54-year-old man with a history of venous thrombosis receiving acenocoumarol for primary antiphospholipid syndrome was admitted with inferior myocardial infarction. Coronary angiography showed thrombotic occlusion of the right coronary artery (Figure 1A). The patient was enrolled in the Paclitaxel-Eluting Balloon in ST-Elevation Myocardial Infarction protocol (PEBSI-01). The lesion was predilated, a bare metal stent (Pro-Kinetic Energy 3×20 mm, Biotronik) was implanted, and angioplasty was performed using a paclitaxel-eluting balloon (Pantera Lux 3×25 mm, Biotronik) (Figure 1B). The patient was prescribed clopidogrel for 6 months and acetylsalicylic acid and acenocoumarol indefinitely. Angiographic follow-up at 8 months showed a coronary aneurysm in the middle segment of the stent (Figure 1C). Optical coherence tomography showed well-apposed struts at the distal and proximal portions of the stent. The aneurysmal segment had a maximum diameter of 5.8 mm and a small quantity of thrombotic material was attached to the struts not in contact with the vessel wall. The upper part of Figure 2 shows a longitudinal reconstruction of the right coronary artery (leftmost image, distal segment), and the lower part shows sections of the distal segment, aneurysmal segment, and proximal portion of the stent, with details of each region.

Aneurysm formation is a known but rare complication following coronary intervention. This phenomenon has been associated with inflammatory and arthritic processes caused by certain polymers in drug-eluting stents. It can also be caused by the implantation of stents in arteries with abundant thrombotic material, which could lead to stent malapposition following thrombolytic therapy. It has been suggested that the use of drug-eluting balloons for angioplasty may lead to a higher rate of adverse effects than the use of drug-eluting stents given that greater local concentrations of the drug are reached using the former devices. Although its treatment is a matter of debate, the most frequently used option is the conservative approach. Optical coherence tomography is the most effective tool to study these complications.

* Corresponding author:

E-mail address: javierlacunzarui@gmail.com (F.J. Lacunza Ruiz).

Available online 17 May 2014