

prosthesis. Several cases have since been published; most were transapical, as it was considered that this approach provided greater stability in valve deployment.<sup>4</sup> Early cases of TAVI in patients with a mitral prosthesis were performed using a CoreValve prosthesis, and it was confirmed that there was no deformation of the nitinol tubing of the valve or interference due to the poppets of the mitral prosthesis.<sup>5</sup> García et al.<sup>6</sup> published the first 3 cases of TAVI with an Edwards-SAPIEN XT valve, in 3 women with ATS 29 and St. Jude mechanical mitral prostheses. The authors recommended a thorough study of patients before the procedure, with particular emphasis on the characteristics and profile of the mitral valve prosthesis, as they considered that there should be sufficient distance between the lower edge of the annulus and the upper edge of the mitral valve prosthesis. This distance was not specified, although it was considered advisable that the distance be at least 3 mm in transapical implants and 7 mm in transfemoral implants.<sup>6</sup>

Furthermore, it appears that direct TAVI without prior valvuloplasty offers several advantages, such as a lower risk of stroke, greater stability in valve deployment, and lower perivalvular aortic regurgitation; however, no randomized studies have compared the 2 techniques.<sup>1,2</sup> To our knowledge, this is the first published case of direct TAVI in the presence of mechanical mitral prosthesis.

To ensure success in this type of procedure, patients should be carefully selected and direct implantation considered if the valve opens correctly and symmetrically, with no significant calcification of the leaflets or excessive commissural fusion. In addition, rapid valve placement at the annulus is recommended to shorten flow obstruction time and to obtain greater hemodynamic stability; inflation should be started slowly such that any undesirable movement of the prosthesis can be corrected, if necessary.

This case shows that a TAVI implant without predilation in the presence of a mitral mechanical prosthesis is feasible and safe and can offer advantages over the conventional method. Future studies are needed to compare the 2 implant techniques with the various models of percutaneous valve prostheses.

## SUPPLEMENTARY MATERIAL



Supplementary material associated with this article can be found in the online version available at <http://dx.doi.org/10.1016/j.rec.2013.02.009>.

Leire Unzué,\* Eulogio García, Leticia Fernández-Friera, Ana Alegría-Barrero, Juan Medina-Peralta, and F. José Rodríguez-Rodrigo

*Unidad de Hemodinámica y Cardiología Intervencionista, Hospital Universitario Montepríncipe, Madrid, Spain*

\*Corresponding author:

E-mail address: [leireunzue@yahoo.es](mailto:leireunzue@yahoo.es) (L. Unzué).

Available online 25 May 2013

## REFERENCES

- García E, Hernández-Antolín R, Martín P, Rodríguez JC, Almería C, Cuadrado AM. Implantación de prótesis aórtica Edwards-SAPIEN XT transfemoral sin valvuloplastia previa. *Rev Esp Cardiol*. 2013;66:150-1.
- Grube E, Naber C, Abizaid A, Sousa E, Mendiz O, Lemos P, et al. Feasibility of transcatheter aortic valve implantation without balloon pre-dilation: a pilot study. *JACC Cardiovasc Interv*. 2011;4:751-7.
- Rodes-Cabau J, Dumont E, Miro S. Apical aortic valve implantation in a patient with a mechanical valve prosthesis in mitral position. *Cir Cardiovasc Intervent*. 2008;1:233.
- Soon JL, Ye J, Lichtenstein SV, Wood D, Webb JG, Cheung A. Transapical transcatheter aortic valve implantation in the presence of a mitral prosthesis. *J Am Coll Cardiol*. 2011;58:715-21.
- Bruschi G, De Marco F, Oreglia J, Colombo P, Fratto P, Lullo F, et al. Percutaneous implantation of CoreValve aortic prostheses in patients with a mechanical mitral valve. *Ann Thorac Surg*. 2009;88:e50-2.
- García E, Albarrán A, Heredia-Mantrana J, Guerrero-Pinedo F, Rodríguez J, Hernández-Antolín R, et al. Implantación transfemoral de prótesis valvular aórtica en pacientes portadores de prótesis mitral mecánica. *Rev Esp Cardiol*. 2011;64:1052-5.

<http://dx.doi.org/10.1016/j.rec.2013.02.009>

## Dronedaron: An Option in the Treatment of Ventricular Arrhythmias

### *Dronedaron: una opción en el tratamiento de las arritmias ventriculares*

#### To the Editor,

The management of ventricular arrhythmias is complex and often requires the implantation of an implantable cardioverter-defibrillator (ICD). However, antiarrhythmic agents (AAA) continue to be relevant as a primary indication and as a way to reduce device-based therapies in patients with ICDs. However, patients often present contraindications that restrict AAA therapy to just a few options, such as amiodarone. Dronedaron is an AAA that has been proven effective in the control of atrial arrhythmias and may help patients with recurrent ventricular arrhythmias when other drugs cannot; however, information on its effectiveness in this clinical setting is scarce. We describe the use of dronedaron in 3 patients with ventricular arrhythmias who were unresponsive or intolerant to other AAAs.

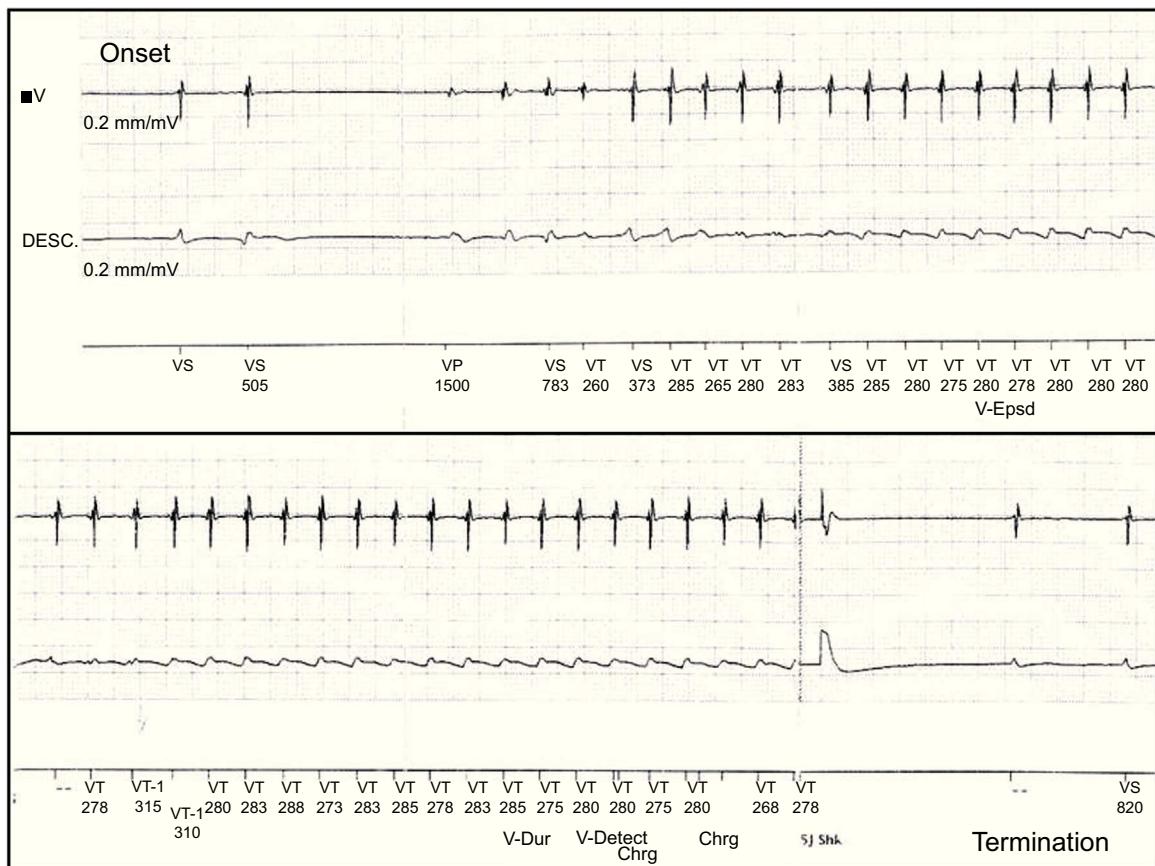
The first patient, a 53-year-old man with hypertension but without structural heart disease, had experienced frequent monomorphic premature ventricular beats since 2007. Treatment with atenolol and sotalol had failed. In February 2010, he was admitted after presenting with syncope and documented a

nonsustained monomorphic ventricular tachycardia. An electrophysiology study was conducted and a sustained monomorphic ventricular tachycardia (SMVT) similar to the clinical arrhythmia was induced, as well as 2 other morphologies. Endocardial and epicardial mapping located the arrhythmogenic substrate in the superolateral aspect of the mitral annulus. The application of RF energy was not effective and thus intramyocardial reentry was suspected. Cardiac magnetic resonance imaging showed a scar in the anterolateral aspect of the left ventricle. An ICD was implanted and treatment with flecainide was initiated. Subsequent follow-ups showed that he had experienced numerous episodes of SMVT and received ICD shocks (Figs. 1 and 2). We decided to replace flecainide for dronedaron 400 mg every 12 h and to avoid the use of amiodarone due to its adverse effects. From that time on, and up to his final check-up 14 months later, there was a reduction in arrhythmia burden and the patient did not undergo ICD shocks or experience SMVT episodes, with the exception of 2 episodes that were suppressed by the initial antitachycardia pacing therapy.

The second patient, a 64-year-old man with hypertension but without apparent structural heart disease, had been followed up in another hospital since 2006 for ventricular tachycardia. Three ablation procedures had failed and an ICD was implanted in 2007. Initially, he was treated with metoprolol and subsequently with sotalol and multiple ICD shocks. In 2009, treatment with amiodarone and atenolol was initiated, which reduced the number of episodes. On 2 occasions in December 2011, he was admitted for

	Device	TELIGEN 100 F102/017785		Date Impl.
	Modo Taqui	Monitor + Therapy		18 Feb 2010
Event	Date/hour	Type	Treatment	Duration hh:mm:ss
V-35	13 Jun 2011 06:29	VNoSust	Not sustained	00:00:11
V-34	04 Jun 2011 20:43	VNoSust	Not sustained	00:00:06
V-33	26 May 2011 20:22	VNoSust	Not sustained	00:00:09
V-32	26 May 2011 03:56	VNoSust	Not sustained	00:00:10
V-31	20 May 2011 21:34	VNoSust	Not sustained	00:00:09
V-30	18 May 2011 20:36	VNoSust	Not sustained	00:00:09
V-29	07 May 2011 22:07	VNoSust	Not sustained	00:00:10
V-28	09 Apr 2011 19:21	VNoSust	Not sustained	00:00:12
V-27	09 Apr 2011 19:19	VNoSust	Not sustained	00:00:11
Event	Date/hour	Type	Treatment	Duration hh:mm:ss
V-26	09 Apr 2011 18:50	TV-1	ATPx1	00:00:20
V-25	09 Apr 2011 18:34	TV-1	Any therapy	00:00:17
V-24	09 Apr 2011 18:33	VNoSust	Not sustained	00:00:11
V-23	09 Apr 2011 17:12	TV-1	ATPx1	00:00:20
V-22	09 Apr 2011 15:03	TV	◇ ATPx1, 5J	00:00:44
V-14	17 Mar 2011 19:40	TV-1	Any therapy	00:00:16
V-13	02 Mar 2011 22:14	TV-1	Any therapy	00:00:16
V-3	27 May 2010 06:23	TV-1	ATPx1	00:00:19
V-1	18 Feb 2010 12:22	FV	Induced: 14J	00:00:38

**Figure 1.** Recording of arrhythmias detected and treated with an implantable cardioverter-defibrillator. Patient 1.



**Figure 2.** Ventricular tachycardia episode recorded by an implantable cardioverter-defibrillator. Onset of the episode (top) and its termination by a 5-J electric shock (below). Patient 1.

multiple ICD shocks triggered by SMVT. During his stay he showed nonischemic left ventricle dysfunction (ejection fraction 35%) and thyroid hormone abnormalities (thyrotropin  $<0.01$   $\mu\text{IU/mL}$ ; free thyroxine 7.7 ng/dL) associated with the use of amiodarone. During hospital admission he presented a new SMVT episode and received 3 ICD shocks. Amiodarone was not well tolerated and was replaced by dronedarone. After hospital discharge, the patient did not experience ICD shocks during 6 months of follow-up, except for 1 shock that occurred within the first 2 weeks.

The third patient, a 42-year-old man, presented with SMVT in 2005 and was diagnosed with arrhythmogenic right ventricular cardiomyopathy, for which he was treated with sotalol 160 mg/d. In 2012, he was admitted to the emergency department for palpitations and presyncope; SMVT was detected and terminated by electrical cardioversion. During hospitalization, he experienced new SMVT episodes that did not respond to treatment with metoprolol and procainamide. The electrophysiology study showed 3 SMVT morphologies, one of them similar to clinical VT but all of them with poor hemodynamic tolerance that degenerated into ventricular fibrillation. We decided to implant a single-chamber ICD and treat the patient with dronedarone 400 mg every 12 h to avoid the adverse effects associated with amiodarone. During the month following discharge, the patient had 4 SMVT episodes and received multiple shocks. As a result, dronedarone was discontinued and sotalol was restarted, at 160 mg every 12 h; a partial response was achieved.

Dronedarone is a benzofuran derivative that shares the antiarrhythmic properties of amiodarone, but with a better safety profile regarding organ toxicity. It has been proven effective in the treatment of atrial arrhythmias in selected populations.<sup>1,2</sup> However, its effectiveness in treating ventricular arrhythmias is less well known. Animal studies have demonstrated its antiarrhythmic effect on ventricular myocardium.<sup>3</sup> Its use in humans has been described in 3 isolated cases, with significant reductions reported in arrhythmia burden and the number of ICD shocks.<sup>4–6</sup>

In this series, which is the largest published to date, a satisfactory response to dronedarone was obtained in 2 patients without structural heart disease; however, in the patient with arrhythmogenic right ventricular cardiomyopathy the decrease in arrhythmia burden was not significant and the drug was discontinued. Furthermore, no adverse clinical or laboratory events were observed and there were no changes in the ICD pacing and sensing parameters. These results, together with

previously published findings, support the use of dronedarone in patients with recurrent ventricular arrhythmias in whom other AAAs are considered unsuitable and with no contraindications for its use. However, like other AAAs, its use cannot be expected to be completely effective, especially when other drugs have failed.

## CONFLICTS OF INTEREST

Dr. Merino has acted as a consultant and received financial remuneration for preparing educational presentations on behalf of Sanofi-Aventis.

Jorge L. Páez, David Doiny, Alejandro Estrada, Jorge Figueroa, David Filgueiras-Rama, and Jose L. Merino\*

*Unidad de Arritmias y Electrofisiología Cardíaca Robotizada, Servicio de Cardiología, Hospital Universitario La Paz, Madrid, Spain*

\*Corresponding author:

E-mail address: [jlmerino@secardiologia.es](mailto:jlmerino@secardiologia.es) (J.L. Merino).

Available online 20 June 2013

## REFERENCES

1. Hohnloser SH, Crijns HJ, Van Eickels M, Gaudin C, Page RL, Torp-Pedersen C. Effect of dronedarone on cardiovascular events in atrial fibrillation. *N Engl J Med*. 2009;360:668–78.
2. Hernández-Madrid A, Francés RM, Moro C. Novedades en electrofisiología cardíaca y arritmia. *Rev Esp Cardiol*. 2011;64 Supl. 1:81–90.
3. Finance O, Manning A, Chatelain P. Effects of a new amiodarone-like agent, SR 33589, in comparison to amiodarone, D,L-sotalol, and lignocaine, on ischemia-induced ventricular arrhythmias in anesthetized pigs. *J Cardiovasc Pharmacol*. 1995;26:570–6.
4. Fink A, Duray GZ, Hohnloser SH. A patient with recurrent atrial fibrillation and monomorphic ventricular tachycardia treated successfully with dronedarone. *Europace*. 2011;13:284–5.
5. Shaaraoui M, Freudenberger R, Levin V, Marchlinski FE. Suppression of ventricular tachycardia with dronedarone: a case report. *J Cardiovasc Electrophysiol*. 2011;22:201–2.
6. Exposito V, Rodriguez-Entem F, Gonzalez-Enriquez S, Olalla JJ. Dronedarone for recurrent ventricular tachycardia: a real alternative? *Indian Pacing Electrophysiol J*. 2012;12:73–6.

<http://dx.doi.org/10.1016/j.rec.2013.02.008>

## Nonvalvular Atrial Aneurysmal Dilation

### *Dilatación aneurismática auricular en pacientes no valvulares*

#### To the Editor,

Left atrial (LA) aneurysmal dilation is often associated with rheumatic valve disease.<sup>1</sup> Our objective was to define the actual incidence of nonvalvular aneurysmal dilation of the LA and the clinical and echocardiographic characteristics of patients with this condition.

Aneurysmal dilation was defined as an anteroposterior LA diameter of more than 6 cm, measured in M-mode from the parasternal view. Echocardiographic studies recorded during 2010 and 2011 were reviewed. Patients with mitral valve prosthesis, mitral stenosis, or mitral regurgitation of more than mild severity and pericardial constriction were excluded. Patients were then classified in 1 of 2 groups: patients with LA aneurysmal dilation with diastolic dysfunction (ADDD) and those with isolated aneurysmal dilation (IAD). Diastolic dysfunction was

defined as an  $e'$  velocity of less than 8 cm/s at the septal mitral annulus.<sup>2</sup>

The echocardiographic parameters recorded (see Table) were as follows: anteroposterior LA diameter and indexed volume according to the Simpson rule (apical 4-chamber 2-chamber view), right atrial volume, left ventricular systolic and diastolic function,  $e'$  and  $S$  velocities at the septal mitral annulus, pulmonary pressure, tricuspid annular plane systolic excursion, and severity of regurgitation. In each case, the mean of 5 measurements was taken.

The clinical parameters recorded were age, sex, cardiac rhythm, smoking habit, diabetes mellitus, dyslipidemia, hemoglobin in blood, hypertension, chronic pulmonary disease, heart disease, functional class, and history of admission for heart failure.

Of 22 555 echocardiograms (Figure), 644 had LA  $>6.0$  cm; 116 (18%) did not have any significant mitral valve lesions, and mitral valve prostheses were found in 43%, stenosis in 22%, mitral regurgitation in 9.3%, and annular calcification with hemodynamic impact in 6.8%. Eighty per cent of the patients without valve disease were in atrial fibrillation (AF). Twenty patients (17.2%) had  $e' >8$  cm/s and 18 were in AF; these patients comprised the IAD