

Image in cardiology

Dynamic road-mapping: role in left atrial appendage occlusion

Utilidad del *dynamic road-mapping* en el cierre de la orejuela izquierda

Ignacio Cruz-González, Blanca Trejo-Velasco,* and Rocío González-Ferreiro

Servicio de Cardiología, Hospital Clínico Universitario de Salamanca-IBSAL, CIBERCV, Salamanca, Spain

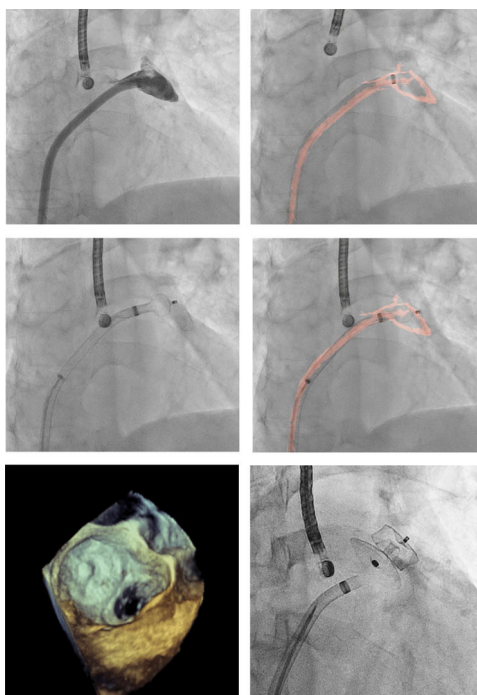


Figure 1.

We describe the case of an 85-year-old woman with permanent atrial fibrillation and a contraindication for oral anticoagulation who underwent percutaneous left atrial appendage closure. The patient had chronic kidney failure, with a glomerular filtration rate of 24 mL/min/1.73 m², which severely restricted the use of contrast material during implantation.

Transseptal puncture was guided by fluoroscopy and transesophageal echocardiography. A single 5-mL injection of contrast material was given in the left atrial appendage, with simultaneous acquisition of virtual appendage imaging using the Dynamic Coronary Roadmap (Philips).

This system navigates contrast-filled structures in each acquisition image and then produces a real-time dynamic overlay of this structure. The use of this technique in coronary interventional procedures has been associated with the use of lower radiation doses and contrast volume. However, its role in structural interventional cardiology has not been explored to date.

In our patient, the road-mapping system allowed adequate visualization of the morphology of the left atrial appendage, including its “anchor point” (Figure 1). Consequently, the closure device (Amulet 34 mm, Abbott) was successfully positioned and released without additional contrast injections, and correct positioning was confirmed by transesophageal echocardiography.

Although there are reports of atrial appendage closure guided only by echocardiography, road-mapping technology could be an additional tool for structural procedures and offer improved safety for complex patients with kidney failure.

CONFLICTS OF INTEREST

I. Cruz-González is a proctor for Abbott Vascular. There are no other conflicts of interest.

* Corresponding author:

E-mail addresses: treejooblanca@hotmail.com, btv2211@gmail.com (B. Trejo-Velasco).

Available online 22 March 2019