

Image in cardiology

Dysphagia Lusoria Caused by Kommerell Diverticulum

Disfagia lusoria causada por divertículo de Kommerell

Luís Seca,* Rosa Ferreira, and António Leitão Marques

Centro Hospitalar de Coimbra, Martinho do Bispo, Coimbra, Portugal

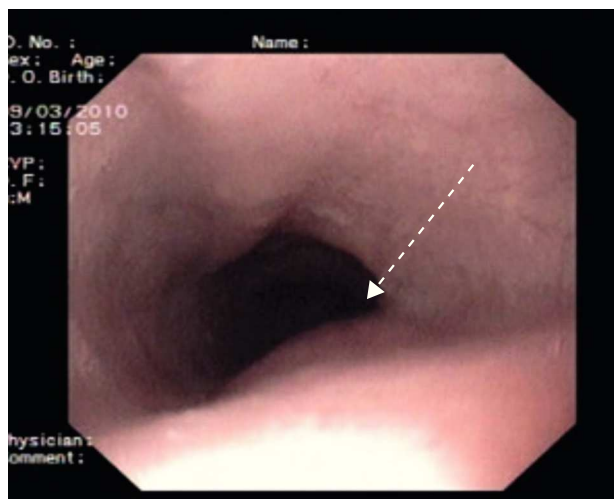


Figure 1.

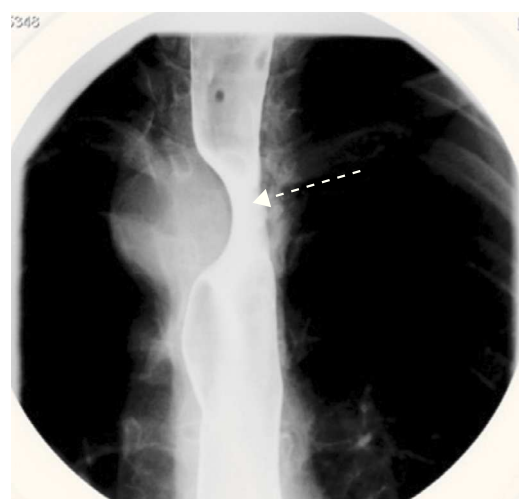


Figure 2.

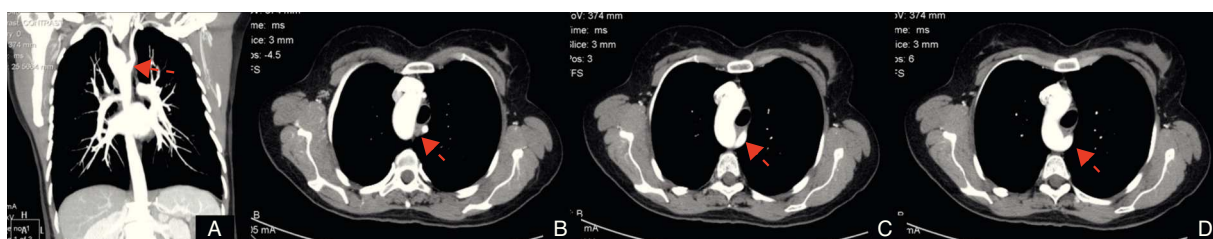


Figure 3.

A 45-year-old, otherwise healthy woman with a 1-year history of progressive solid dysphagia was referred to our hospital. The patient was initially submitted to an upper gastrointestinal endoscopy which revealed a small longitudinal pulsatile protruding mass in the proximal esophagus (Fig. 1). An additional esophagogram revealed a notching of the proximal esophagus from an extrinsic compression (Fig. 2). Chest computed tomography angiogram showed a right-sided aortic arch with a left aberrant subclavian artery dilated at its origin (Kommerell diverticulum), causing evident obstruction of the esophagus (Fig. 3). After presenting the case to the cardiothoracic surgical team, the patient was submitted to corrective surgery. She experienced an uneventful postoperative course and was discharged from the hospital 10 days after the procedure. At 6 months follow-up she was totally asymptomatic.

Right-sided aorta is present in 0.04% to 0.1% of the population, 50% of which are associated with an aberrant left subclavian artery. Some patients with left or right aberrant subclavian arteries have an obviously dilated origin of the aberrant artery from the aorta (called Kommerell diverticulum). Kommerell diverticulum and aberrant subclavian artery can be discovered accidentally in asymptomatic children or adults, but sometimes they are associated with complications, such as compression of adjacent structures, dissections, or ruptures. Compression of the esophagus may cause dysphagia, known as dysphagia lusoria.

Standard options for management of Kommerell diverticulum are not established because of the rarity of this anomaly. Generally speaking, surgical intervention is recommended in symptomatic patients or asymptomatic patients with a large diverticulum.

* Corresponding author:

E-mail address: luisseca@gmail.com (L. Seca).

Available online 28 January 2012