

ECG Contest

ECG, April 2015

ECG de abril de 2015

Ana Viana-Tejedor

Departamento de Cardiología, Hospital Clínico San Carlos, Madrid, Spain

A 65-year-old man with valvular dilated cardiomyopathy, severe left ventricular dysfunction, and permanent atrial fibrillation, who had a cardioverter-defibrillator and aortic and mitral prostheses, was admitted due to worsening of his functional class. During his admission, he underwent cardiac-resynchronization therapy after anticoagulation withdrawal. Three days later, he reported oppressive chest pain, radiating to the jaw, with sweating and low blood pressure. An ECG was performed ([Figure](#)). Emergency coronary angiography was ordered due to persistent chest pain and cardiogenic shock. Before the angiography could be performed, he went into cardiac arrest due to ventricular fibrillation. He recovered after advanced cardiopulmonary resuscitation.

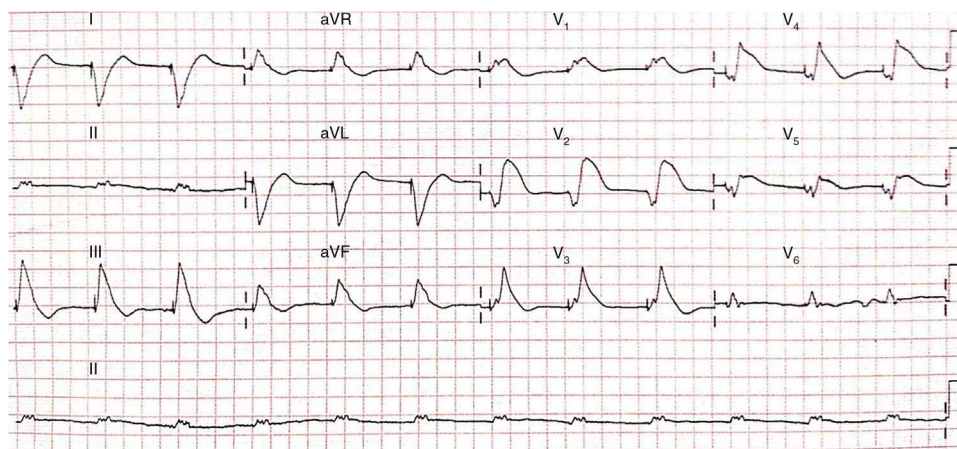


Figure.

Suggest a solution to this ECG Contest at <http://www.revespcardiol.org/es/electroreto/68/04> (only Spanish). The answer will be published in the next issue (May 2015). #RetoECG.

E-mail address: ana_viana_tejedor@hotmail.com