

ECG Contest

ECG, February 2016

ECG de febrero de 2016

Reyes Álvarez García-Rovés

Servicio de Cardiología Pediátrica, Hospital General Universitario Gregorio Marañón, Madrid, Spain



The patient was a 7-day-old boy who was in the immediate postoperative period after undergoing aortic arch repair involving coarctation repair with end-to-end anastomosis and pericardial patch closure of a perimembranous ventricular septal defect. There had been no adverse intraoperative events. The infant was transferred to the pediatric intensive care unit with inotropic support consisting of dopamine and milrinone. Twenty-four hours after the intervention, a change took place in his rhythm, with progressive hypotension and oliguria (Figure). Adenosine triphosphate was administered and electrical cardioversion was performed with no response. What is your diagnosis? How would you treat this patient?

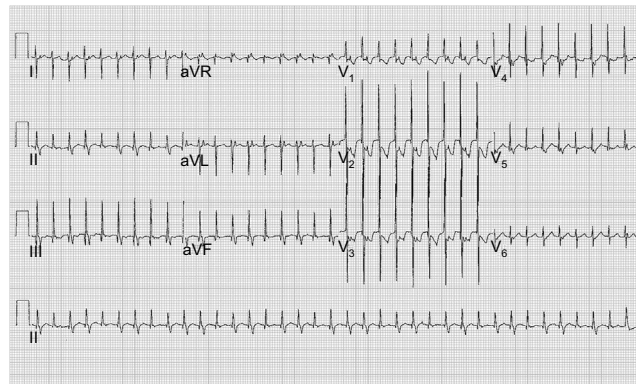


Figure.

Suggest a solution to this ECG contest at <http://www.revespcardiol.org/es/electroreto/69/02> (only Spanish). The answer will be published in the next issue (March 2016). #RetoECG.