

ECG Contest

ECG, February 2019

ECG de febrero de 2019



Alejandro Cruz-Utrilla,* Hernán Mejía-Rentería, and Alejandro Travieso-González

Servicio de Cardiología, Hospital Clínico San Carlos, Madrid, Spain

A 50-year-old man with a history of hypertension contacted the out-of-hospital emergency service after onset of oppressive retrosternal chest pain with radiation to the left arm and sweating. The first ECG recorded on arrival in the emergency room is the one shown in the Figure.

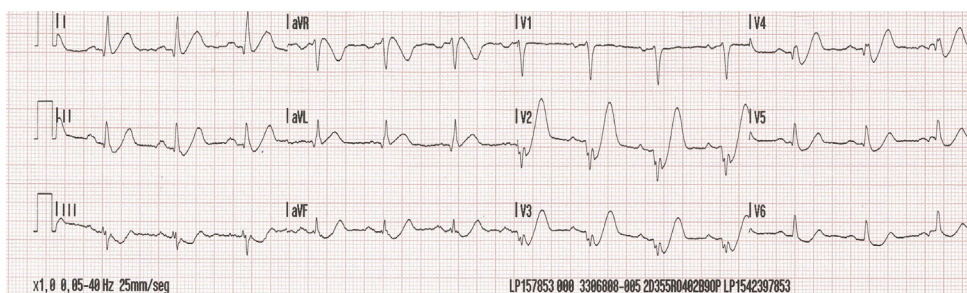


Figure.

According to this ECG, what was the most likely diagnosis?

1. Non-ST-elevation acute coronary syndrome (NSTEMI-ACS), with an ECG indicative of left main coronary artery involvement or 3-vessel disease.
2. NSTEMI-ACS but the affected vessel cannot be identified.
3. Posterior ST-elevation acute coronary syndrome (STEMI-ACS), with an ECG indicative of involvement of a posterolateral branch.
4. Anterior STEMI-ACS, with an ECG indicative of ostial-proximal left anterior descending artery involvement.

Submit your answer to <http://www.revespcardiol.org/en/electroreto/72/2>. The solution will be published in the next issue (March 2019). #ECGChallenge #RetoECG.

* Corresponding author:

E-mail address: acruzutrilla@gmail.com (A. Cruz-Utrilla).

Available online