

## ECG Contest

## ECG, January 2015

## ECG de enero de 2015

Jorge Toquero Ramos

Servicio de Cardiología, Clínica Puerta de Hierro, Majadahonda, Madrid, Spain



A 52-year-old woman had been treated with implantation of an aortic prosthesis for severe stenosis of a bicuspid aortic valve 37 years previously. During follow-up, she developed progressive, severe prosthetic valve stenosis without ventricular dysfunction that required valve replacement. On the fourth postoperative day, she experienced an episode of loss of contact with her surroundings. Complete atrioventricular block was documented, which persisted in paroxysmal form at 7 days of monitoring; finally, a dual-chamber pacemaker was implanted. Normal functioning of the device was confirmed. On the third day following the procedure, the patient underwent ECG study (Figure 1, ECG during tachycardia; Figure 2, preoperative ECG) to investigate palpitations, her only symptom. What would your diagnosis be?

Suggest a solution to this ECG Contest at <http://www.revespcardiol.org/es/electroreto/68/01> (only Spanish). The answer will be published in the next issue (February 2015). #ECG-RETO.

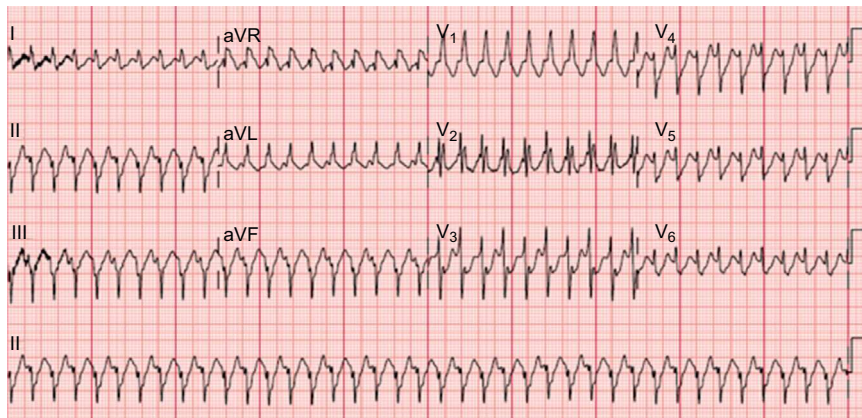


Figure 1.

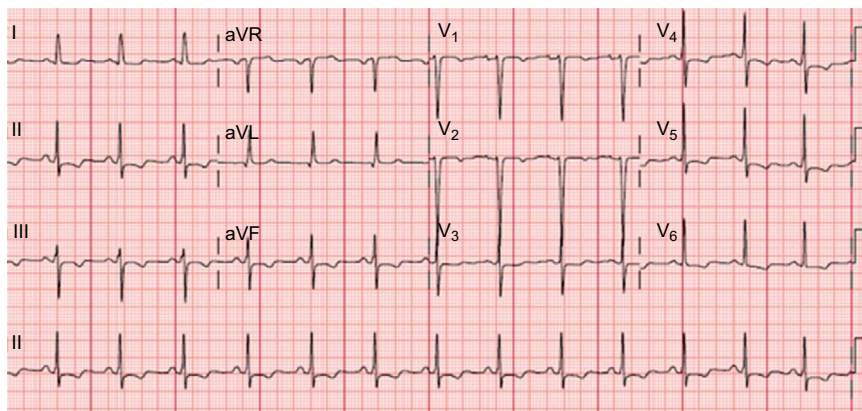


Figure 2.

E-mail address: [jorgetoquero@secardiologia.es](mailto:jorgetoquero@secardiologia.es)

<http://dx.doi.org/10.1016/j.rec.2014.06.021>

1885-5857/© 2014 Sociedad Española de Cardiología. Published by Elsevier España, S.L.U. All rights reserved.