

ECG Contest

ECG, July 2019

ECG de julio de 2019



Maria Melendo-Viu,* Adolfo Fontenla, and María López-Gil

Unidad de Arritmias, Servicio de Cardiología, Hospital Universitario 12 de Octubre, Madrid, Spain

We present the case of a 58-year-old man admitted for syncope and congestive heart failure who had undergone biatrial orthotopic heart transplant 6 years earlier. The echocardiogram showed restrictive filling. Coronary angiography and endomyocardial biopsy confirmed advanced graft-versus-host disease (grade 3) and evidenced humoral rejection. Specific treatment was indicated. During his stay on the ward, episodes of atrial flutter were observed with fast ventricular response and asymptomatic bradycardia in the telemetry, with the ECG shown in the [Figure](#).

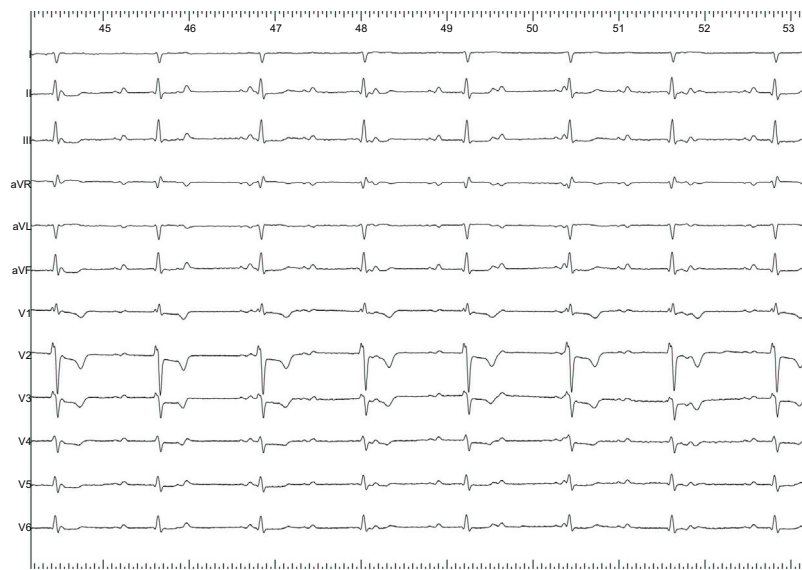


Figure.

What do you think was the diagnosis?

1. The patient has sinus dysfunction.
2. The patient has complete atrioventricular block.
3. The patient's ECG is normal for a transplant recipient.
4. The patient has Wenckebach-type grade 2 atrioventricular block.

Submit your answer to <http://www.revespcardiol.org/en/electroreto/72/07>. The solution will be published in the next issue (August 2019). #ECGChallenge #RetoECG.

* Corresponding author:
E-mail address: mariamelviu@gmail.com (M. Melendo-Viu).