

ECG Contest

ECG, November 2018

ECG de noviembre de 2018

José Luís Martins,* Anabela Gonzaga, and José Santos

Department of Cardiology, Baixo Vouga Hospital Centre, Aveiro, Portugal



A 32-year-old woman with a history of smoking presented to the hospital with complaints of mild chest pain that started 16 hours prior to arrival during a bike ride. Vital signs on arrival at the Emergency Department were blood pressure 103/52, pulse 85 bpm, respiration 14 breaths per minute, and oxygen saturation 99%. The initial electrocardiogram was recorded (Figure).

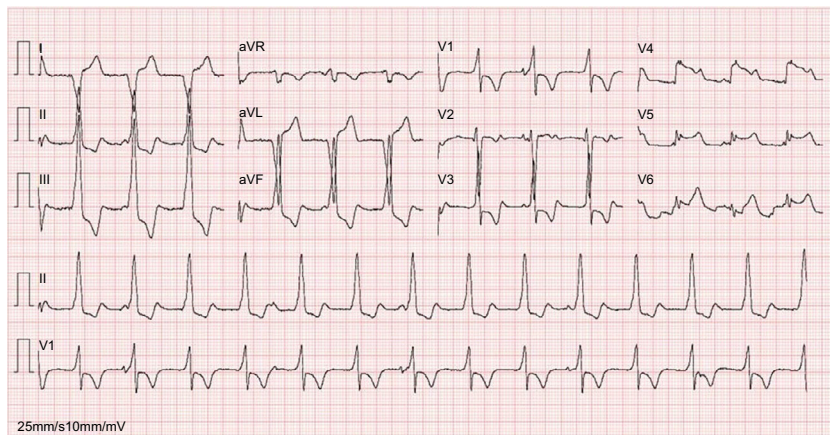


Figure.

What do you think is the correct diagnosis?

- 1) Pre-excitation syndrome (Wolff Parkinson White syndrome)
- 2) Accelerated idioventricular rhythm
- 3) Atrioventricular dissociation (complete atrioventricular block)
- 4) Early phase of anterolateral ST segment elevation myocardial infarction

Suggest a solution to this ECG Contest at <http://www.revespcardiol.org/en/electroreto/71/11>. The answer will be published in the next issue (December 2018). #EKGchallenge.

* Corresponding author:
E-mail address: zeluismartins@gmail.com (J.L. Martins).