

ECG Contest

ECG, October 2014



ECG de octubre de 2014

Concepción Alonso-Martín

Unidad de Arritmias, Servicio de Cardiología, Hospital de la Santa Creu i Sant Pau, Barcelona, Spain

The patient was a 63-year-old man with a history of dyslipidemia under treatment with simvastatin, Barrett's esophagus being treated with omeprazole, recent occupational stress being treated with lorazepam, and hypertension for which he was taking enalapril. The only noteworthy findings in his echocardiogram were a nondilated left ventricle with an ejection fraction of 73%, moderate septal hypertrophy (14 mm), and degenerative aortic valve disease with moderate regurgitation. He sought medical attention complaining of episodes of rapid-onset syncope. During his stay in the emergency department, he experienced 2 episodes that required electrical cardioversion.

Figures 1–3 show the rhythm strips recorded from lead III during the episodes, 12-lead electrocardiogram during tachycardia and the baseline electrocardiogram at hospital admission.

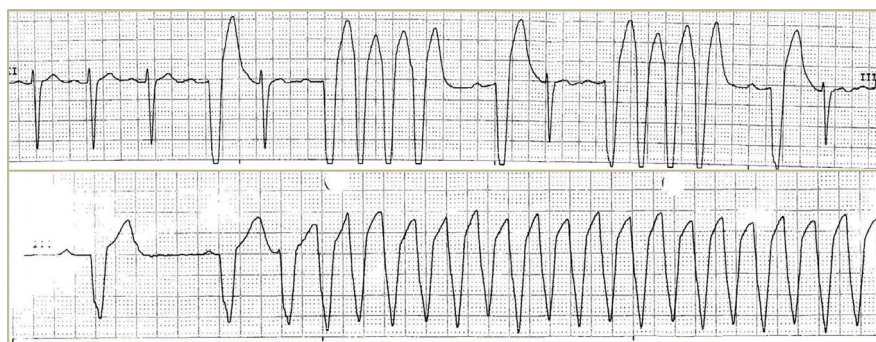


Figure 1.

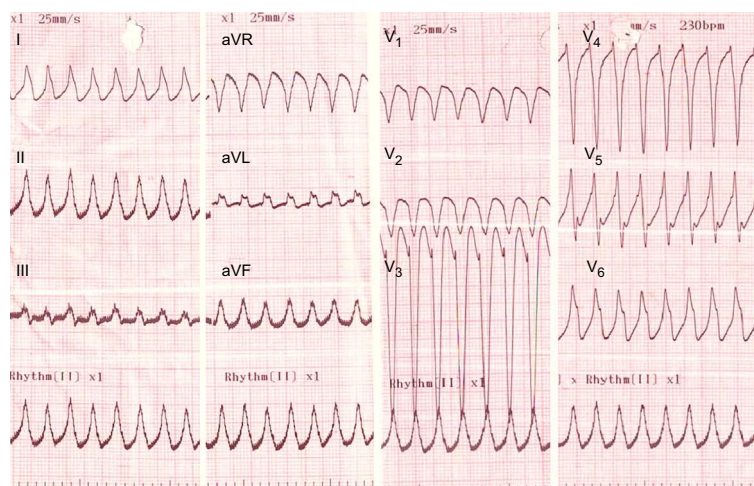


Figure 2.

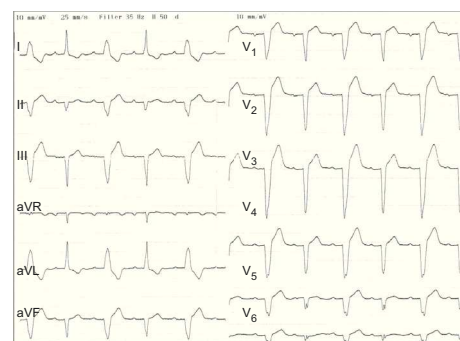


Figure 3.

Suggest a solution to this ECG Contest at <http://www.revespcardiol.org/es/electroreto/67/10> (only Spanish) #ECGOCT14. The answer will be published in the next issue (November 2014).

E-mail address: calonso@santpau.cat