

ECG Contest

ECG, September 2016

ECG de septiembre de 2016



Adolfo Fontenla,* Álvaro Lozano, and María López-Gil

Unidad de Arritmias, Servicio de Cardiología, Hospital Universitario 12 de Octubre, Madrid, Spain

A 29-year-old woman, with no antecedents of interest, was referred to our unit for an electrophysiological study. For several years, she had had palpitations that would appear and disappear suddenly, and her baseline electrocardiogram was consistent with preexcitation (Figure 1). An echocardiogram performed previously was normal. During the electrophysiological study, an episode of atrial fibrillation was accidentally induced (Figure 2), but had no clinical impact (the patient reported no symptoms at the time).

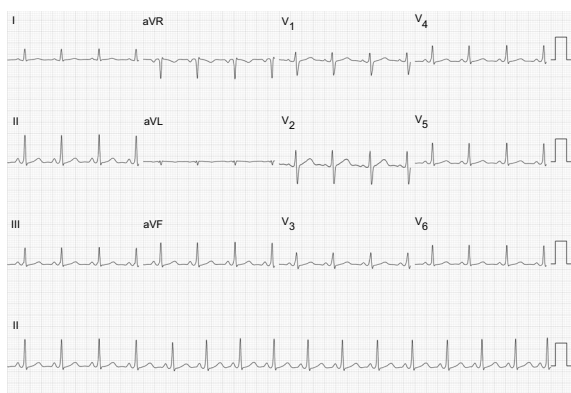


Figure 1.

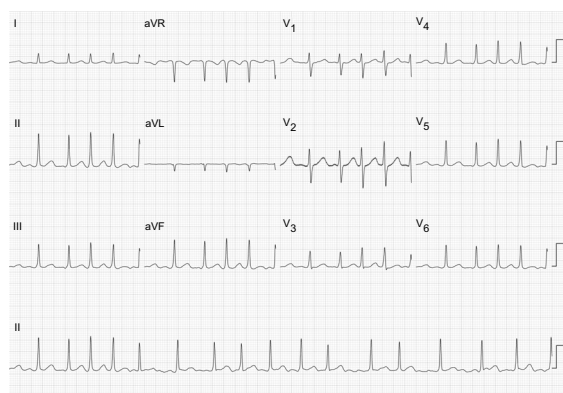


Figure 2.

On the basis of the patient's baseline electrocardiogram, what is your diagnosis?

1. Conventional accessory pathway (bundle of Kent) in left free wall.
2. Anteroseptal conventional accessory pathway (bundle of Kent).
3. Fasciculoventricular pathway.
4. Physiological atrioventricular conduction.

Suggest a solution to this ECG Contest at <http://www.revespcardiol.org/es/electroreto/69/09>. The answer will be published in the next issue (October 2016). #RetoECG.

* Corresponding author:

E-mail address: drfontenla@gmail.com (A. Fontenla).