

CONFLICTS OF INTEREST

A. Martín-García reports personal fees from Daichii Sankyo, personal fees from Bayer, personal fees from Pfizer, personal fees from Novartis, and nonfinancial support from MSD, outside the submitted work. M. Díez-Campelo reports grants and other support from NOVARTIS, during the conduct of the study, as well as grants from CELGENE and from TAKEDA, outside the submitted work.

Marta Alonso-Fernández-Gatta,^{a,b,◇,*} Ana Martín-García,^{a,b,◇} María Díez-Campelo,^c Agustín C. Martín-García,^{a,b} Félix López-Cadenas,^c and Pedro L. Sánchez^{a,b}

^aServicio de Cardiología, Hospital Universitario de Salamanca, Instituto de Investigación Biomédica de Salamanca (IBSAL), Salamanca, Spain

^bCentro de Investigación Biomédica en Red de Enfermedades Cardiovasculares (CIBERCV), Spain

^cServicio de Hematología, Hospital Universitario de Salamanca, Instituto de Investigación Biomédica de Salamanca (IBSAL), Salamanca, Spain

*Corresponding author:

E-mail address: mirti23@hotmail.com

(M. Alonso-Fernández-Gatta).

◇Marta Alonso-Fernández-Gatta and Ana Martín-García contributed equally and should be considered as first authors.

Available online 30 January 2021

REFERENCES

1. Angelucci E, Li PL, Greenberg PL, et al. Safety and Efficacy, Including Event-Free Survival, of Deferasirox Versus Placebo in Iron-Overloaded Patients with Low- and Int-1-Risk Myelodysplastic Syndromes (MDS): Outcomes from the Randomized, Double-Blind Telesio Study. *Blood*. 2018;132:234.
2. Alam MH, Auger D, Smith GC, et al. T1 at 1.5T and 3T compared with conventional T2* at 1.5T for cardiac siderosis. *J Cardiovasc Magn Reson*. 2015;17:102.
3. Sado DM, Maestrini V, Piechnik SK, et al. Noncontrast myocardial T1 mapping using cardiovascular magnetic resonance for iron overload. *J Magn Reson Imaging*. 2015;41:1505–1511.
4. Kawel-Boehm N, Maceira AM, Valsangiacomo-Buechel ER, et al. Normal values for cardiovascular magnetic resonance in adults and children. *J Cardiovasc Magn Reson*. 2015;18:29.
5. Sado DM, White SK, Piechnik SK, et al. Native T1 lowering in iron overload and Anderson Fabry: a novel and early marker of disease. *J Cardiovasc Magn Reson*. 2013;15(Suppl 1):O71.

<https://doi.org/10.1016/j.rec.2020.12.005>
1885-5857/

© 2020 Sociedad Española de Cardiología. Published by Elsevier España, S.L.U. All rights reserved.

Expanding donation niches. Heart transplant from a donor on veno-venous ECMO



Expandiendo los nichos de donación: trasplante cardíaco de un donante con ECMO veno-venoso

To the Editor,

The shortage of donor hearts, lengthening [0]waiting times, and the need for urgent transplants¹ necessitate an expansion of the clinical criteria for heart transplant (HT) to include donors with a nonstandard-risk. This category includes patients on veno-venous extracorporeal membrane oxygenation (V-V ECMO) as bridge therapy to lung transplantation or recovery. Not all of these patients survive, creating a niche of potential donors. We present the case of an adult male patient who underwent successful HT from a brain-dead donor on V-V ECMO.

The donor was a 28-year-old man with labial herpes simplex virus infection who was admitted to hospital with fever, myalgia, and cough. A chest X-ray and computed tomography scan indicated bilateral pneumonia. Blood cultures were negative, and serological analysis detected immunoglobulin M (IgM) antibodies to syncytial respiratory virus. The patient was placed on broad-spectrum antibiotic therapy and required mechanical ventilation. A tracheostomy was performed on day 14 of hospitalization, and the patient was transferred to our hospital. After hospitalization for 19 days, the patient's worsening respiratory profile required respiratory V-V ECMO support (Cardiohelp-Getinge Group, Sweden) with cannulation of the right femoral and jugular veins. The patient was treated according to the local protocol, including continuous anticoagulation with sodium heparin to maintain the activated coagulation time between 160 s and 180 s. On post-HT day 9, the patient developed bilaterally fixed and dilated pupils, and cranial computed tomography detected evidence of hypoxic-ischemic encephalop-

athy. Brain death was confirmed by clinical examination and cerebral computed tomography angiography. An apnea test was inconclusive for hypoxemia.

After obtaining family consent, the patient was painstakingly evaluated as a potential donor. Favorable results were obtained from hemodynamic and respiratory analysis and ancillary tests (table 1). The heart, liver, and kidneys were removed under V-V ECMO support.

The recipient was a 55-year-old man (87 kg, 167 cm) diagnosed with hypertrophic cardiomyopathy and with a previous sternotomy. He had been on the elective HT waiting list for 75 days.

Orthotropic HT was performed by the bacaval method with standard sternotomy. Total ischemia time was 125 min, and the patient showed good postoperative progress. Post-transplant echocardiography detected good biventricular function of the donor organ. The patient was discharged 17 days after admission under treatment with standard doses of mycophenolate mofetil, tacrolimus, and prednisone. Over 48 weeks of follow-up, the patient underwent 6 scheduled endomyocardial biopsies: 4 showing mild cellular rejection (grade 1 R on the ISHLT 2004 working formulation) and 2 showing no evidence of rejection. The patient developed febrile neutropenia in post-HT week 11, with no signs of infection.

The use of V-V ECMO has increased due to the accumulated experience with this procedure and technological advances. The indications for V-V ECMO have expanded as a result, and this approach has become more generally used at more hospitals. The overall incidence of complications is 7.1%, with brain death accounting for 23% of them.²

Published data appear to confirm that organs from brain-dead donors supported by V-V or veno-arterial ECMO perform similarly to those from brain-dead donors without ECMO support.³⁻⁵ Despite the evidence for the safety of organs transplanted from ECMO-supported donors,⁴ there is a continuing reluctance among transplantation teams to use organs from these patients, owing to

Table 1

Donor clinical and hemodynamic characteristics and ancillary test results

Age, y	28
Sex	Male
Weight, kg; height, cm; BMI	85; 180; 26.2
SBP; mmHg; HR; bpm	114; 78
Inotropic medication	No
ECG	Sinus rhythm with negative T waves in leads V2-V6
<i>Analytical parameters</i>	
Creatinine, mg/dL	0.4
ALT; AP; AST; GGT, U/L	50; 38; 16; 88
Lactic acid, mmol/L	1.3
Peak CK, U/L	34
Peak high-sensitivity troponin T, ng/L	54
CRP, mg/L; procalcitonin, ng/mL	18; 0.03
Leucocytes, cells/ μ L; hemoglobin, g/dL; platelets, cells/ μ L	7610; 9.8; 99 800
<i>Arterial gases</i>	
PaO ₂ , mmHg; pCO ₂ , mmHg; HCO ₃ ⁻ , mmol/L; pH	130; 36; 28; 7.5
<i>Echocardiography parameters</i>	
LVEF, %	61
LVEDD; LVESD; IVS, mm	54; 38; 10
Right ventricle size	Normal
Right ventricle function (TAPSE), mm	22
Valve disease	Mild mitral and tricuspid insufficiency
Mitral Doppler flow	Normal
SPAP, mmHg	33
<i>Respiratory parameters</i>	
V-V ECMO FiO ₂ , %	100
Respirator FiO ₂ , %	35
Patient PaO ₂ :FiO ₂	371
V-V ECMO PaO ₂ :FiO ₂	500
<i>Respirator parameters</i>	
Ventilator mode; RF, rpm; TV, mL; PEEP, cmH ₂ O	VC-AC; 10; 320; 10

AF, alkaline phosphatase; ALT, alanine aminotransferase; AST, aspartate aminotransferase; BMI, body mass index; CK, total creatine kinase; CRP, C-reactive protein; ECG, electrocardiogram; FiO₂, fraction of inspired oxygen; GGT, gamma-glutamyl transpeptidase; HCO₃⁻, bicarbonate; HR, heart rate; IVS, interventricular septum; LVEDD, left ventricular end-diastolic diameter; LVEF, left ventricular ejection fraction; LVESD, left ventricular end-systolic diameter; V-V ECMO, veno-venous extracorporeal membrane oxygenation; PaCO₂, partial pressure of arterial carbon dioxide; PaO₂, partial pressure of arterial oxygen; PEEP, positive end-expiratory pressure; RF, respiratory frequency; SBP, systolic blood pressure; SPAP, systolic pulmonary artery pressure; TAPSE, tricuspid annular plane systolic excursion; TV, tidal volume; VC-AC, volume control-assist control.

the difficulty of the apnea test, the frequency of concomitant multiorgan failure, and the lack of information about associated pathophysiological changes.

Patients on V-V ECMO support eventually undergo an increase in lung pressure secondary to hypoxia, and the resulting increase in right ventricular load can affect the systo-diastolic function of the grafted organ.⁶ Appropriate flow rates should be maintained through the ECMO cannulas to guarantee adequate organ perfusion.⁶ Transplant teams should also carry out an exhaustive assessment of the donor heart, confirm stable respiratory parameters and the absence of multiorgan failure, and consider other factors related to the success of HT, such as donor-recipient age match and a short predicted ischemia time to protect the grafted heart from the inflammatory response to ischemia-perfusion.

The clinical and radiological characteristics of our donor are consistent with COVID-19; however, the clinical case occurred in December 2019, before the identification of COVID-19 in Spain or the use of SARS-CoV-2 PCR tests. COVID-19 was later excluded by testing serum samples for antibodies (IgM and IgG). The inverted T

waves in the patient's electrocardiogram were attributed to brain damage.

There are few reports in the literature on the therapeutic transplantation of donor hearts from patients on V-V ECMO support, and there is no standardized protocol for this procedure. The case reported here is the first in Spain unaffected by problems related to graft function, the number and severity of rejections, or complications due to infection. However, it is important to proceed with caution, since this was the case of a single transplant recipient with a short follow-up, and there is little literature on this topic.

María del Val Groba-Marco,^{a,*} Francisco Portela-Torrón,^b Vicente Peña-Morant,^{c,d} José Luis Romero-Luján,^c Eduardo Caballero-Dorta,^a and Antonio García-Quintana^a

^aServicio de Cardiología, Hospital Universitario de Gran Canaria Doctor Negrín, Las Palmas de Gran Canaria, Spain

^bServicio de Cirugía Cardíaca, Hospital Universitario de Gran Canaria Doctor Negrín, Las Palmas de Gran Canaria, Spain

^cServicio de Medicina Intensiva, Hospital Universitario de Gran Canaria Doctor Negrín, Las Palmas de Gran Canaria, Spain

^dUnidad de Donación y Trasplante, Hospital Universitario de Gran Canaria Doctor Negrín, Las Palmas de Gran Canaria, Spain

*Corresponding author:

E-mail address: marivalgroba@hotmail.com (M.V. Groba-Marco).

Available online 18 March 2021

REFERENCES

1. González-Vílchez-F. Almenar-Bonet L, Crespo-Leiro M, et al. Registro Español de Trasplante Cardíaco XXXI Informe Oficial de la Sección de Insuficiencia Cardíaca de la Sociedad Española de Cardiología (1984–2018). *Rev Esp Cardiol.* 2020;73:919–926.
2. Lorusso R, Gelsomino S, Parise O, et al. Neurologic injury in adults supported with veno-venous extracorporeal membrane Oxygenation for respiratory failure: findings

- from the extracorporeal life support organization database. *Crit Care Med.* 2017;45:1389–1397.
3. Migliaccio ML, Sagli G, Cianchi G, et al. Extracorporeal membrane oxygenation in brain-death organ and tissue donors: a single center experience. *Br J Anaesthesia.* 2013;111:673–680.
 4. Bronchart R, Durand L, Legeai C, Cohen J, Guerrini P, Bastien O. Brain dead donors on extracorporeal membrane oxygenation. *Crit Care Med.* 2017;45:1734–1741.
 5. Carter TI, Bodzin AS, Hirose H, et al. Outcome of organs procured from donors of extracorporeal membrane oxygenation support: an analysis of kidney and liver allografts data. *Clin Transplant.* 2014;28:816–820.
 6. Singh G, Tsukashita M, Biscotti M, et al. Heart procurement from a donor on venovenous ECMO support. *ASAIO J.* 2016;62:e24–e26.

<https://doi.org/10.1016/j.rec.2020.12.019>
1885-5857/

© 2020 Sociedad Española de Cardiología. Published by Elsevier España, S.L.U. All rights reserved.

Endocarditis on a Perceval S sutureless prosthesis. A new valve with a new form of clinical presentation



Endocarditis sobre prótesis sin sutura Perceval S. Una nueva válvula con una nueva forma de presentación clínica

To the Editor,

The emergence of the Perceval S sutureless biological aortic prosthesis (LivaNova, Italy) represents an advance in the development of replacement valves, especially for patients with moderate or high risk.¹

This new prosthesis is made of 3 bovine pericardial leaflets, mounted on a flexible, collapsible, external nitinol stent (figure 1). It allows a minimally-invasive approach and shortening of surgical times, as well as a reduction in postoperative morbidity and mortality. Its design improves the hemodynamic profile with better transvalvular gradients at follow-up and fewer cases of patient-prosthesis mismatch, making it the ideal replacement in patients with small aortic annulus or in complicated situations, such as infectious endocarditis.² These advantages have led to its rapid and widespread uptake in multiple European cardiac surgery departments.

Infectious endocarditis is a disease with high morbidity and mortality, the most severe form being prosthetic valvular endocarditis (PVE). PVE occurs in approximately 1% to 6% of patients with a cardiac prosthesis and constitutes 10% to 30% of all cases of infectious endocarditis. Most patients require surgical treatment, but this is often a challenge, with significant perioperative morbidity and mortality.³

In the last 10 years, the Perceval S prosthesis has become the biological replacement valve of choice in our department, and is used in patients older than 70 years and with a moderate-high risk profile, with a mean follow-up close to 7 years and a low complication rate. We performed a retrospective observational study, with hospital ethics approval and patient consent, to analyze the prevalence and presenting characteristics of VPE in this type of prosthesis, with particular attention paid to diagnostic imaging. Since 2015, 670 Perceval S valves have been implanted and 14 cases of PVE have been diagnosed in them (2.1%). This figure represents 6.4% of all the PVE cases treated in our hospital during the same period (n = 220).

Table 1 describes the clinical characteristics, microbiological profile, imaging findings, and outcomes of the 14 patients with PVE. It should be noted that 11 cases were early-onset PVE, occurring > 3 months after surgery, and the most common organism was *Staphylococcus epidermidis* (n = 7).

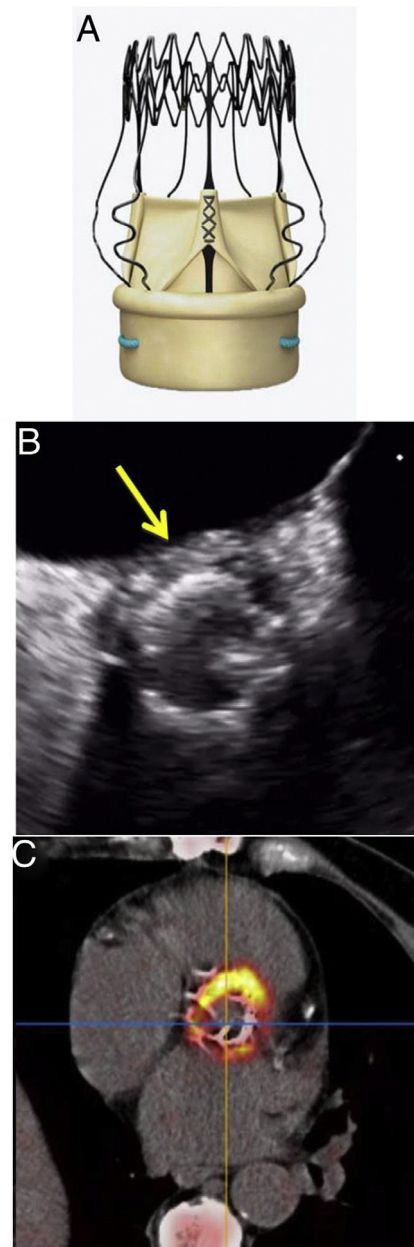


Figure 1. a: Perceval S prosthesis. b: transesophageal echocardiography, abscess. c: ¹⁸F-fluorodesoxyglucose positron-emission tomography/computed tomography, metabolic uptake.