

## Original article

## Findings of a Mixed Transfemoral Aortic Valve Implantation Program Using Edwards and CoreValve Devices

Rosa Ana Hernández-Antolín,<sup>a,\*</sup> Eulogio García,<sup>a</sup> Santiago Sandoval,<sup>a</sup> Carlos Almería,<sup>a</sup> Ana Cuadrado,<sup>b</sup> Javier Serrano,<sup>c</sup> Eduardo de Obeso,<sup>a</sup> Raquel del Valle,<sup>a</sup> Camino Bañuelos,<sup>a</sup> Fernando Alfonso,<sup>a</sup> Fernando Guerrero,<sup>a</sup> Jerónimo Heredia,<sup>a</sup> Juan Carlos Martín Benítez,<sup>d</sup> Juan Carlos García-Rubira,<sup>a</sup> Enrique Rodríguez,<sup>e</sup> and Carlos Macaya<sup>a</sup>

<sup>a</sup>Servicio de Cardiología, Instituto Cardiovascular, Hospital Clínico San Carlos, Madrid, Spain

<sup>b</sup>Servicio de Anestesia, Instituto Cardiovascular, Hospital Clínico San Carlos, Madrid, Spain

<sup>c</sup>Servicio de Cirugía Vascular, Instituto Cardiovascular, Hospital Clínico San Carlos, Madrid, Spain

<sup>d</sup>Servicio de Medicina Intensiva, Instituto Cardiovascular, Hospital Clínico San Carlos, Madrid, Spain

<sup>e</sup>Servicio de Cirugía Cardíaca, Instituto Cardiovascular, Hospital Clínico San Carlos, Madrid, Spain

## ARTICLE INFO

## Article history:

Received 28 January 2010

Accepted 20 July 2010

Available online 16 December 2010

## Keywords:

Percutaneous  
Transfemoral  
Aortic valve  
Implantation  
Replacement  
SAPIEN  
CoreValve  
Vascular complication  
Pacemaker

## ABSTRACT

**Introduction and objectives:** Transfemoral implantation of an Edwards-SAPIEN (ES) or Medtronic CoreValve (MCV) aortic valve prosthesis is an alternative to surgical replacement for patients with severe aortic stenosis and a high surgical risk. The study's aim was to compare results obtained with these two devices.

**Methods:** Prospective observational study of transfemoral prosthesis implantation performed at our center.

**Results:** Of the 76 patients (age  $83 \pm 6$  years, 63% female, logistic EuroSCORE  $18 \pm 9$ ) included, 50 were assigned the ES and 26 the MCV device. There was no difference between the groups in age, sex, functional class, valve area, associated conditions, or EuroSCORE. Implantation was successful in 84% of the ES group and 100% of the MCV group ( $P = .04$ ). There were three cases of tamponade, two aortic dissections and one valve malposition in the ES group. The two groups had similar vascular access complication rates (26% vs. 23%;  $P = \text{NS}$ ), but pacemaker need was greater with the MCV (10% vs. 39%;  $P = .003$ ). Mortality rates at 30 days were 12% and 20% ( $P = \text{NS}$ ) in the ES and MCV groups, respectively, and at 1 year, 24% and 20% ( $P = \text{NS}$ ), respectively. After a follow-up of  $367 \pm 266$  days in the ES group and  $172 \pm 159$  days in the MCV group, three patients died. Clinical improvement was maintained in other patients and no echocardiographic changes were observed.

**Conclusions:** In-hospital mortality, the complication rate and medium-term outcomes were similar with the two devices. The only difference observed was a higher implantation success rate with the MCV, although at the expense of a greater frequency of atrioventricular block.

© 2010 Sociedad Española de Cardiología. Published by Elsevier España, S.L. All rights reserved.

## Resultados de un programa mixto de implantación de prótesis aórtica por vía transfemoral con los dispositivos de Edwards y CoreValve

## RESUMEN

**Introducción y objetivos:** La implantación de prótesis valvular aórtica por vía transfemoral con los dispositivos Edwards-SAPIEN (ES) y Medtronic-CoreValve (MCV) es una alternativa al reemplazo quirúrgico en pacientes con estenosis aórtica severa y alto riesgo quirúrgico. Nuestro objetivo es comparar los resultados obtenidos con uno y otro dispositivo.

**Métodos:** Estudio prospectivo de las prótesis implantadas por vía transfemoral en nuestro centro.

**Resultados:** De los 76 pacientes (edad,  $83 \pm 6$  años; el 63% mujeres; EuroSCORE logístico,  $18 \pm 9$ ), se seleccionó a 50 para ES y a 26 para MCV. No se observaron diferencias entre grupos en edad, sexo, clase funcional, área valvular, enfermedades asociadas o EuroSCORE. Se consiguió implantar la prótesis en el 84% del grupo ES y el 100% del grupo MCV ( $p = 0,04$ ); hubo 3 casos de taponamiento, 2 disecciones aórticas y 1 malposición en la serie ES. Las complicaciones vasculares fueron similares (el 26 frente al 23%), pero la necesidad de marcapasos fue mayor con la MCV (el 10 frente al 39%;  $p = 0,003$ ). Las mortalidades totales a 30 días fueron del 12 y el 20% (sin diferencia significativa) y a 1 año, del 24 y el 20% en los grupos ES y MCV respectivamente. Tras un seguimiento de  $367 \pm 266$  días para ES y  $172 \pm 159$  para MCV, 3 pacientes fallecieron; los demás mantienen la mejoría clínica y no se observan cambios ecocardiográficos.

## Palabras clave:

Percutánea  
Transfemoral  
Válvula aórtica  
Implantación  
Reemplazo  
SAPIEN  
CoreValve  
Complicación vascular  
Marcapasos

\* Corresponding author. Unidad de Hemodinámica y Cardiología Intervencionista, Hospital Clínico San Carlos, C/ Martín Lagos, s/n, Madrid 28040, Spain.

E-mail address: rhernandez\_antolin@hotmail.com (R.A. Hernández-Antolín).

**Conclusiones:** La mortalidad hospitalaria, la tasa de complicaciones y la evolución a medio plazo han sido similares con ambos dispositivos; las únicas diferencias encontradas han sido una tasa de implantación con éxito mayor con la MCV, aunque a expensas de una mayor frecuencia de bloqueo auriculoventricular. © 2010 Sociedad Española de Cardiología. Publicado por Elsevier España, S.L. Todos los derechos reservados.

## Abbreviations

CT: computed tomography  
ES: Edwards-SAPIEN prosthesis  
HSR: high surgical risk  
MCV: Medtronic CoreValve prosthesis  
TA: transapical  
TF: transfemoral

## INTRODUCTION

The percutaneous implantation of an aortic valve prosthesis is an alternative to surgery in patients with severe aortic stenosis and at high surgical risk (HSR). Two types of valve have been developed for percutaneous implantation: a balloon-expandable prosthesis (first implantation performed in 2002<sup>1</sup>) and a self-expanding prosthesis (first implantation performed in 2005<sup>2</sup>). In 2008, the results of the initial feasibility and safety studies<sup>2–7</sup> led to the Edwards-SAPIEN™ (ES) (Edwards Lifesciences LLC, Irvine, California, USA) and Medtronic CoreValve™ System (MCV) (Medtronic CoreValve LLC, Minneapolis, Minnesota, USA) being approved for their use in Europe. By the end of 2009, more than 10 000 prostheses had been implanted, approximately two thirds via the transfemoral (TF) approach and one third via the transapical (TA) approach.

After they were launched, several multicenter registries,<sup>8–10</sup> single-center registries,<sup>11–13</sup> and some Spanish centers<sup>14–17</sup> provided information on these devices. However, very few centers have incorporated both valves. In fact, a search of the literature revealed just two reported series<sup>18,19</sup> with this characteristic. In our hospital, both devices have been implanted via the TF approach; thus, the aim of the present study is to describe the short-term and medium-term results of our TF implantation program, drawing attention to the different aspects of the two devices.

## METHODS

### Beginning the Program

Patient selection commenced in February 2007. In August 2007, the first TF implantation of the Cribier-Edwards prosthesis was performed; this device was superseded by the ES in 2008 and by the ES XT in 2010. In March 2008, the MCV prosthesis program was launched and the first of these devices was implanted in July of the same year.

### Patient Selection

Candidates for inclusion in the study were patients with a valve area <0.6 cm<sup>2</sup>/m<sup>2</sup>, NYHA functional class >2 and at HSR, defined by at least one of the following 4 criteria: logistic EuroSCORE >20%, severe comorbidity (pulmonary, kidney, liver, blood, and cerebrovascular disease, and fragility), age >85 years, or rejected for surgery.

Assessment included transesophageal echocardiogram, coronary angiography, and aortography of the aortic root and iliac bifurcation

and, in some patients, computed tomography (CT) of the iliofemoral axis. The minimal luminal diameter of each arterial segment (distal aorta, common iliac, external iliac, and common femoral) on both sides was measured.<sup>20</sup> Tortuosity and calcification were classified as mild, moderate, or severe.

### Device Selection

The manufacturer's recommendations were followed for each device (Table 1). During the first year, only the ES valve was available, such that when the iliofemoral axis was unsuitable TA implantation was performed. With the incorporation of the MCV, and after performing the first procedures without applying any specific selection criteria, we decided to use the ES in patients with a suitable femoral artery, the MCV in patients with an annulus of 26–27 mm (large for ES, appropriate for MCV) or with femoral arteries of 6–7.5 mm (small for ES, acceptable for MCV), and the TA approach in patients with arteries <6 mm.

The size of each device was selected according to the established recommendations (ES-23 for an annulus of 18–21 mm, ES-26 for an annulus of 22–25 mm, MCV-26 for an annulus of 20–23 mm and MCV-29 for an annulus of 24–27 mm).

### Procedural Logistics

The procedures were performed in the catheterization laboratory following standard aseptic and antiseptic preparation. In all cases, the team consisted of two interventional cardiologists, three nurses, an anesthesiologist (AC) and an echocardiologist (CA), and when the ES was used a vascular surgeon was present. Antibiotic prophylaxis was administered (cefazolin + gentamicin). At the beginning we used sedation as the anesthetic protocol (remifentanyl + propofol); later, this was changed to general anesthesia, but currently we have returned to sedation. Stable blood pressure is essential during implantation, since hypotension inhibits the valve from opening correctly and hypertension favors embolization.

Although the procedure was generally performed under fluoroscopic guidance, conventional 3D transesophageal echocardiography was very useful in measuring the aortic annulus, locating calcium deposits, and assessing post-valvuloplasty opening and regurgitation, positioning during implantation, prosthetic functioning, and the presence of perivalvular leaks, as well as in diagnosing complications (tamponade, aortic dissection).

### Instrumentation

#### Non-Therapeutic Access

Venous access for temporary pacemakers via the femoral approach when using ES (electrode catheter <24 h) and via the jugular approach when using MCV (electrode catheter 48 h). Femoral arterial access using a 6F introducer for pressure monitoring and angiography.

#### Therapeutic Access

When ES was used (except for ES XT), the surgeon exposed the femoral artery and at the end of the procedure sutured the artery

**Table 1**

Anatomical Criteria for Patient Selection for the Percutaneous Implantation of Aortic Valve Prostheses as Recommended by the Manufacturers

	ES	MCV
Aortic annulus (TEE/CT)	18–25	19–27
Height of the sinus of Valsalva (TEE/CT)	–	>10 mm
Sinotubular junction (TEE/CT)	–	30–40
Ascending aorta (TEE/CT)	–	<42
Outflow tract angle-ascending aorta (angiography/CT)	–	<45°
Outflow tract diameter (TEE)	>18	>19
MLD iliofemoral axis (angiography/CT)	>7 mm (ES-23) >8 mm (ES-26)	>6 mm
Tortuosity (angiography/CT)	<moderate	<moderate
Calcification (angiography/CT)	<moderate	<moderate

Abbreviations: CT, computed tomography; ES, Edwards-SAPIEN prosthesis; MCV, Medtronic CoreValve prosthesis; MLD, minimum luminal diameter; TEE, transesophageal echocardiography.

and repaired vascular damage. When the MCV or ES XT was implanted, closure was performed with the Prostar XL™ (Abbot Vascular, Chicago, Illinois, USA) device.

### Valvuloplasty

Balloon valvuloplasty was performed (NuMed Nucleus™, PTV, Numed Inc., Hopkinton, NY, USA) during high-frequency ventricular pacing (PACEL™, St Jude Medical, Minneapolis, Minnesota, USA).

### Preparation of the Valve

Both prostheses are supplied in glutaraldehyde and naturally expanded. The ES prosthesis was mounted on a balloon and the MCV was prepared in frozen serum and gradually compressed until being introduced into its delivery sheath.

### Devices

The ES valve consists of a stainless steel stent to which the valve is sewn (bovine pericardium). It requires a 25F and 28F outer diameter introducer except for the ES XT model, which requires a 20F and 22F introducer. The MCV valve is made of porcine pericardium sewn to a self-expanding nitinol stent. It has three portions: the lower portion has high radial force that enables anchoring; the middle region is designed to avoid obstructing the coronary artery outflow tracts; and the upper portion has a larger diameter that helps to orient the prosthesis. It requires an 18F introducer.

### Implantation

Both devices were advanced using the retrograde approach and positioned under fluoroscopic, angiographic, and echocardiographic guidance. In the case of the ES, the reference line was valve calcium. The best projection is usually the left oblique cranial view. Implantation was performed during ventricular pacing at 180–220 bpm without the possibility of correction once inflation was started.

The MCV valve was released when the distal extreme of the sheath was 3–4 mm below the sinuses of Valsalva in a projection (normally left oblique caudal) in which the three sinuses were seen to be aligned. The device can be repositioned at the beginning of release and can still be reintroduced into its sheath and repositioned again up to release of the distal third.

### Post-Implantation Protocol

In the absence of complications the patients were moved to the cardiovascular critical care unit for 24 h (ES) or 48 h (MCV) and discharged after 5–6 days under treatment with clopidogrel 75 mg and acetylsalicylic acid 100 mg (3 months). Patients with complete atrioventricular (AV) block were implanted with a permanent pacemaker.

### Follow-up

The patients were followed up at 30 days, 3 months, 6 months and 12 months and every year thereafter. In addition, an echocardiogram was performed at 30 days and at each yearly check-up.

### Data Collection

The data were collected prospectively and introduced in a database for their analysis.

### Statistical Analysis

Continuous variables were expressed as mean (standard deviation [SD]) and compared using the Student's *t*-test. Discrete variables were expressed as percentages and compared using the  $\chi^2$ -test with Fisher's correction if needed. Mortality over time was expressed as Kaplan–Meier curves.

## RESULTS

### Patient Selection

Between May 2007 and April 2010 159 patients were assessed: 7 were rejected due to having few symptoms, 12 for symptoms of another disease, 6 for nonsevere aortic stenosis, 7 for the lack of HSR criteria, 2 for contraindications (cognitive deterioration, life expectancy <1 year), 2 for predominant aortic regurgitation, 7 for a too large or too small aortic annulus, and 23 for unsuitable femoral arteries; 7 patients did not complete the assessment and 10 patients died during this period. In total, 76 patients were included: 50 were assigned to the ES and 26 to the MCV.

**Table 2**  
Baseline Clinical Data

	All (n = 76)	ES (n = 50)	MCV (n = 26)	P
Age (year)	83 ± 6	82 ± 6	84 ± 5	.16
Women	48 (63%)	34 (68%)	14 (54%)	.22
Body surface area (m <sup>2</sup> )	1.80 ± 0.2	1.81 ± 0.2	1.77 ± 0.2	.47
NYHA functional class III–IV	58 (76%)	40 (80%)	18 (69%)	.30
Atrial fibrillation	19 (25%)	14 (28%)	5 (19%)	.40
Ejection fraction (%)	62 ± 13	63 ± 14	59 ± 12	.19
Comorbidity				
Coronary artery disease	38 (50%)	25 (50%)	13 (50%)	1
Previous coronary surgery	6 (8%)	5 (10%)	1 (4%)	.66
Previous angioplasty	25 (33%)	15 (30%)	10 (39%)	.46
Ejection fraction <40%	7(9%)	5 (10%)	2 (8%)	1
Mitral regurgitation ≥moderate	8 (11%)	6 (12%)	2 (8%)	.71
Pulmonary hypertension >60 mmHg	27 (36%)	15 (30%)	12 (46%)	.16
Pulmonary disease	15 (20%)	11 (22%)	4 (15%)	.49
Cerebrovascular disease	6 (8%)	4 (8%)	2 (8%)	1
Peripheral vascular disease	2 (2%)	1 (2%)	1 (4%)	1
Renal failure	14(18%)	10 (20%)	4 (15%)	0.76
Age >85 years	30 (39%)	16 (32%)	14 (54%)	.06
Estimated surgical risk				
EuroSCORE	17.7 ± 9	17.3 ± 7.9	18.6 ± 10	.55
STS score	6.34 ± 1.8	6.31 ± 1.9	6.69 ± 2.1	.73
Rejected for surgery	52 (68%)	37 (74%)	15 (58%)	.15
Valve assessment (TEE)				
Mean transaortic gradient	48.6 ± 14.9	47.4 ± 14.4	51.0 ± 15.9	.33
Peak transaortic gradient	79.8 ± 22.8	78.8 ± 23.7	81.8 ± 21.45	.60
Valvular area (cm <sup>2</sup> )	0.5 ± 0.2	0.54 ± 0.16	0.57 ± 0.29	.46
Aortic regurgitation	45 (59%)	26 (52%)	19 (73%)	.08
Annulus diameter (mm)	21.3 ± 2.4	21.6 ± 2.5	20.6 ± 2.2	.09
Ileofemoral axis assessment				
Minimum luminal diameter (mm), left	7.4 ± 0.8	7.6 ± 0.7	6.5 ± 0.6	.009
Minimum luminal diameter (mm), right	7.5 ± 0.8	7.8 ± 0.6	6.5 ± 1.3	.15
Tortuosity > mild	47(62%)	29 (58%)	18 (69%)	.34
Calcification > mild	28 (37%)	16 (32%)	12 (46%)	.23

Abbreviations: ES, Edwards-SAPIEN prosthesis; MCV, Medtronic CoreValve prosthesis; NYHA, New York Heart Association; STS, Society of Thoracic Surgeons; TEE, pre-procedural transesophageal echocardiography.  
Data express n (%) or mean (standard deviation).

## Characteristics of the Patients

Table 2 shows the patient characteristics. The populations were similar except for a smaller iliofemoral diameter in the MCV group.

## Implantation

Procedural information is shown in Table 3. It was not possible to implant the ES prosthesis in seven patients: one due to death (tamponade as a consequence of the right ventricle being perforated by the pacemaker); five because the introducer could not be advanced; and one because the valve could not be passed over the valve. Of the 43 patients with an implanted ES, 1 required a second prosthesis because the first device was positioned too high and in another patient the valve was explanted by aortic dissection.

All the MCV prostheses were successfully implanted. In 1 patient who had a thoracoabdominal aortic stent, the valve remained too high after the distal part was released and so the decision was taken to remove it. Due to the risk of damaging the endoprosthesis, it was decided to release the valve in a safe position and a second valve was implanted in the correct position without adverse events.

## Complications

### Tamponade

In the ES group there were three cases of tamponade; two due to perforation by the pacemaker and one due to aortic dissection.

All three patients required pericardial puncture and drainage but only one died because of this.

### Aortic Dissection

In addition to the case described, one patient presented a localized dissection 8 cm from the valve plane that evolved well with conservative management.

### Malposition

One patient in the ES group required a second valve due to the first valve being positioned too high.

### Arrhythmias

After ES implantation, one patient developed ventricular fibrillation that was initially refractory, but after some minutes of cardiac massage the patient underwent successful cardioversion.

### Stroke

Two patients in the ES group presented neurological abnormalities the first 24 h, one of whom had mild sequelae.

### Atrioventricular Conduction Disorders

In the ES group, five patients (10%) presented complete AV block during the procedure. There was no case of late AV block.

**Table 3**  
Procedural Data

	All (n = 76)	ES (n = 50)	MCV (n = 26)	P
<i>General description of the procedure</i>				
General anesthesia	29 (38%)	22 (44%)	7 (27%)	.16
Surgical access	44 (58%)	44 (88%)	0	.0001
Duration (min)	140 ± 47	131 ± 46	156 ± 44	.03
Duration of fluoroscopy (min)	25 ± 15	24 ± 17	28 ± 8	.27
Contrast (mL)	188 ± 94	165 ± 88	232 ± 89	.002
<i>Implantation and valve function (TEE)</i>				
Valve size		23: 32 (64%) 26: 18 (36%)	26:7 (27%) 29:19 (73%)	
Implantation	68 (90%)	42 (84%)	26 (100%)	.045
Post-procedural gradient (mmHg)	9.6 ± 5	8.8 ± 4	10.9 ± 6	.21
Post-procedural area (cm <sup>2</sup> )	1.7 ± 0.4	1.6 ± 0.3	1.8.0 ± 0.5	.1
Severe post-procedural aortic regurgitation	1 (1.3%)	1 (2%)	0	1
<i>Periprocedural complications (non-exclusive)</i>				
Tamponade	3 (3.9%)	3 (6%)	0	.55
Aortic dissection	2 (2.6%)	2 (4%)	0	.54
Malposition	1 (1.3%)	1 (2%)	0	1
Severe arrhythmia	1 (1.3%)	1 (2%)	0	1
Stroke	2 (2.6%)	2 (4%)	0	.54
Vascular complication	19 (25%)	13 (26%)	6 (23%)	.78
Heart surgery	3 (3.9%)	3 (6%)	0	.55
Vascular surgery	12 (16%)	10 (20%)	2 (8%)	.20
Need for pacemaker	15 (20%)	5 (10%)	10 (38%)	.003
Ventilation >48 h	4 (5%)	4 (8%)	0	.29
Dialysis	3 (3.9%)	3 (6%)	0	.55
<i>In-hospital mortality</i>				
Deaths	12 (16%)	7 (14%)	5 (19%)	.74
Cardiac cause	3 (4%)	2 (4%)	1 (4%)	1
Vascular cause	4 (5%)	2 (4%)	2 (8%)	.63
Pulmonary cause	2 (3%)	1 (2%)	1 (4%)	1
Sepsis	1 (1%)	0	1 (4%)	1
Multiorgan failure	3 (4%)	2 (4%)	0	.55

Abbreviations: ES, Edwards-SAPIEN prosthesis; MCV, Medtronic CoreValve prosthesis; TEE, transesophageal echocardiography.

Data express n (%) or mean (standard deviation).

In the MCV group, 10 patients (38%) needed a pacemaker. The development of AV block was frequently late, progressive and preceded by the development or progression of bundle branch block. The latest AV block we observed occurred 48 h after the procedure.

### Vascular Damage

In the ES group there were 12 vascular bleeding complications (10 due to femoral or iliac rupture or dissection, 2 due to bleeding at the puncture site), of which 9 required vascular surgery and 3 endovascular treatment. Another patient needed iliofemoral bypass due to ischemia. There were three vascular complications in the MCV group: two due to bleeding after closure with the Prostar™ device, and one due to dissection that affected flow,

requiring angioplasty. The vascular complications increased mortality from 12% to 21% although the difference did not reach statistical significance due to the small size of the sample (Fig. 1).

### In-Hospital Mortality

A total of seven patients died in the ES group: two during the procedure (one tamponade, one post-valvuloplasty cardiogenic shock); one during the first 24 h (vascular complications); and four later (three due to multiorgan failure at 7 days, 10 days, and 28 days, and one due to respiratory failure at 65 days). There were three early deaths in the MCV group (two due to vascular complications and one due to post-implantation cardiogenic shock in one patient with very severe left ventricular hypertrophy) and two late deaths: one was due to pneumonia at 6 days (patient with previous lung disease) and one due to urological sepsis at 8 days. No significant differences in mortality were observed between the two series.

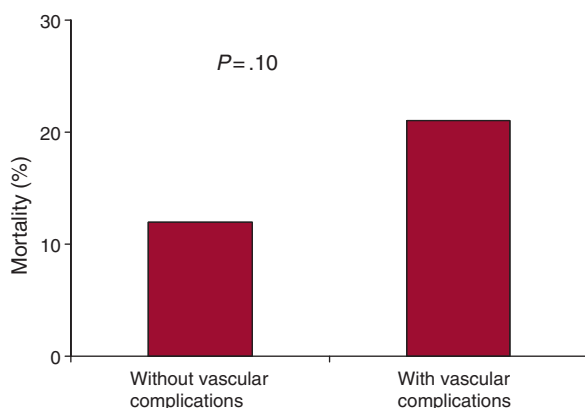
### Learning Curve

Table 4 compares the first and second halves of the ES Group. There was a tendency toward better outcomes in the second half of the group, although only the increase in the implantation rate reached statistical significance.

### Prosthetic Function

Both prostheses left small gradients, although the MCV prosthesis left a slightly larger valve area. Mild periprosthetic aortic regurgitation was frequent with both devices.

In the ES group, there were documented alterations in valve function in five patients: two patients with a correctly positioned,



**Figure 1.** 30-Day mortality among the patients with and without vascular complications.



**Table 4**  
Learning Curve in the Edwards-SAPIEN Series

	Patients 1–25	Patients 26–50	P
<i>Baseline characteristics</i>			
Age (years)	82 ± 6	82 ± 6	.70
Women	19 (76%)	15 (60%)	.22
Functional class III/IV	21 (84%)	19 (76%)	.48
Peak gradient (mmHg)	78 ± 23	79 ± 30	.86
Mean gradient (mmHg)	48 ± 16	46 ± 15	.71
Valvular area (cm <sup>2</sup> )	0.58 ± 0.1	0.49 ± 0.2	.06
Coronary disease	15 (60%)	10 (40%)	.16
EuroSCORE	19 ± 7	16 ± 8	.13
Iliofemoral axis diameter	7.5 ± 0.7	7.7 ± 0.6	.76
Tortuosity ≥ moderate	4 (20%)	4 (20%)	.33
Calcification ≥ moderate	7 (35%)	6 (39%)	.14
<i>Procedure</i>			
Implantation	18 (72%)	24 (96%)	.049
Post-procedural gradient TEE (mmHg)	8.9 ± 3	8.8 ± 5	.97
Post-procedural aortic regurgitation ≥ moderate (TEE)	3 (15%)	2 (10%)	1
Duration of fluoroscopy (min)	24 ± 10	24 ± 21	.96
Contrast (mL)	198 ± 105	131 ± 51	.007
<i>Complications (non-exclusive)</i>			
Tamponade	3 (12%)	0	.24
Aortic dissection	1 (4%)	1 (4%)	1
Heart surgery	3 (12%)	0	.24
Vascular surgery	7 (28%)	3 (12%)	.16
Complete atrioventricular block	2 (8%)	3 (12%)	1
Dialysis	2 (10%)	1 (4%)	.34
In-hospital mortality	5 (20%)	2 (8%)	.67

TEE, transesophageal echocardiography.

Data express n (%) or mean (standard deviation).

well-expanded valve had moderate periprosthetic regurgitation caused by poor valve malposition due to calcium nodules; in two patients the valve was insufficiently expanded, leading to poor valve coaptation with central regurgitation in both patients, one of whom had a 20-mmHg gradient. Finally, in one patient with an apparently well-expanded and correctly positioned ES-23, a 39-mmHg peak gradient with a mean of 22 mmHg was documented at the level of the valve. Of the 26 patients with an MCV prosthesis, 2 presented moderate periprosthetic aortic regurgitation.

### Medium-Term Results

The majority of the patients improved their functional class to class I or II (Table 5). No changes were observed in area or aortic

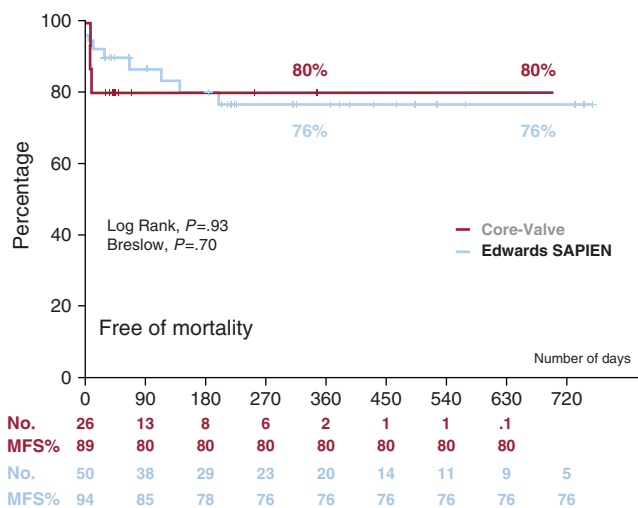
**Table 5**  
Medium-term Course of the Patients Discharged With a Prosthesis

	All (n=58)	ES (n=37)	MCV (n=21)	P
<i>1-month follow-up</i>				
Functional class	1.38 ± 0.6	1.45 ± 0.9	1.31 ± 0.5	.20
Functional class III/IV	2 (4%)	2 (5%)	0	1
Gradient (mmHg)*	7.9 ± 3	7.1 ± 3	10.5 ± 5	.08
Valve area (cm <sup>2</sup> )*	1.7 ± 0.4	1.6 ± 0.3	2.0 ± 0.5	.04
Regurgitation ≥ moderate*	1 (2%)	1 (3%)	0	1
30-day post-discharge mortality	0	0	0	–
<i>Final follow-up</i>				
Mean follow-up (days)	281 ± 244	343 ± 265	172 ± 159	.003
Functional class	1.34 ± 0.6	1.41 ± 0.8	1.17 ± 0.4	.16
Functional class III/IV	3 (7%)	3 (11%)	0	.29
Valve area (cm <sup>2</sup> )*	1.7 ± 0.4	1.7 ± 0.3	1.9 ± 0.4	.01
Regurgitation ≥ moderate*	2 (3.4%)	2 (5.4%)	0	.53
Death (since day 30)	3 (5%)	3 (8%)	0	.55
Cardiac cause	1 (2%)	1 (3%)	0	1
Non-cardiac cause	2 (3%)	2 (5%)	0	.53

Abbreviations: ES, Edwards-SAPIEN prosthesis; MCV, Medtronic CoreValve prosthesis.

Data express n (%) or mean ± standard deviation.

\* Gradient, area, and regurgitation were assessed via transthoracic echocardiography.



**Figure 2.** Kaplan-Meier survival curve for each device. MFS indicates mortality-free survival.

regurgitation except for reduced regurgitation in two patients with ES. Neither were changes observed in the two patients with significant gradients, both of whom remained in a good functional status. The clinical situation of the patient with localized aortic dissection remained satisfactory.

After discharge, three patients in the ES group died: two due to pneumonia at 3 months and 6 months, and one due to aortic dissection (not previously documented by transesophageal echocardiography or post-implantation aortogram) at 4 months. We have no further details of the aortic dissection, as the necropsy was performed in another hospital. Figure 2 shows survival curves with both prostheses.

### DISCUSSION

The present series describes our initial experience of the TF implantation of aortic prostheses in which only patients at HSR were included. The baseline characteristics and the results obtained are within ranges similar to other studies<sup>5,8,10–19</sup> although there are wide variations between them.

The novelty of the study lies in the use of two commercial devices which, despite the limited number of patients, allowed us

to compare their differences in the same environment and hospital and using the same operators. To date, only two mixed series have been reported. One compiled the joint experience of two hospitals in Toulouse<sup>19</sup> that included 21 MCV and 24 ES; and one conducted in Munich<sup>18</sup> that included 105 MCV and 4 ES by TF implantation.

The motivation for using two devices in a single center was based on the fact that there is no evidence, at present, to consider one prosthesis as superior to the other regarding periprocedural mortality, functioning or durability, and most of the learning curve is common to both devices.

### Increased Number of Patients Treatable by the Transfemoral Approach

The availability of both devices means that more patients can be treated via the TF approach, not because of differences in the anatomy of the aortic annulus, but because the MCV device can be used in smaller diameter femoral arteries. In the Rouen series,<sup>20</sup> only 71% of the patients who needed an ES-23 and 39% of those who needed an E-26 had a suitable femoral diameter for TF implantation. Similarly, in the Canadian ES registry,<sup>10</sup> only 50% of the patients could be treated via the TF approach. In the Munich mixed series,<sup>18</sup> 80% of the patients were treated via the TF approach and in the Toulouse series, 71%.<sup>19</sup> In our series, if only the ES valve had been available we would have been able to treat no more than half of the patients who were treated with the MCV valve via the TF approach.

### Specific Aspects of the Procedure With Both Devices

The problem with the ES valve is its size (22–24F) which can lead to vascular problems and implantation failures. In our case, implantation failure decreased from 28% to 4% in the last part of the series when stricter selection criteria were applied. The ES-XT device (18F) markedly reduces difficulties in advancing the device and, potentially, vascular complications.

The other difficulty presented by the ES prosthesis is its correct positioning. This requires good radiological landmarks and correct performance of the pacing–inflation–deflation sequence; transesophageal echocardiography could be of potential use in this regard.

The MCV prosthesis poses fewer access problems and its gradual release enables correct positioning at the beginning of release. In cases of malposition, the implantation of a second valve in the correct position is a possible option with both devices.

### Complications

As in other series, vascular complications were frequent with both devices. These involved dissection and vascular rupture (ES), and bleeding in the puncture area due to failed percutaneous closure (MCV and ES XT). It should be pointed out that in the only study we found that provides information on the size of the femoral arteries – the Toulouse series<sup>19</sup> – the diameter of the artery in their ES group was 8.9 mm vs. 7.8 mm in our ES group, and 7.8 mm in their MCV group vs. 6.5 mm in ours. The strictest patient selection criteria,<sup>21–24</sup> experience in managing the devices, early diagnosis of complications, and their management by percutaneous techniques all contribute to reducing the number of complications and their clinical impact.<sup>21–24</sup>

Cardiac complications (perforations, dissections) were severe but infrequent and the majority were not directly related to the implantation procedure.

AV conduction disorders were more frequent with the MCV prosthesis.<sup>8–9,13,17</sup> In some cases, the disorder occurred during the

procedure, whereas in others this occurred later, with more than one-third of the patients needing a pacemaker. Larger size, low implantation, ventricular hypertrophy, and previous conduction disorders are factors that have led to conduction disorders in other series.<sup>25</sup> If the time required for the temporary pacemaker must be extended, patient stay in special units is longer, probe and catheter withdrawal is delayed, and there is an increased likelihood of infection, which was the direct cause of two of the five deaths in patients who had been implanted with an MCV without complications.

With the ES valve, AV block is less frequent<sup>11–13,26</sup> and there is no tendency toward progression, thus enabling the early withdrawal of the temporary pacemaker lead.

### In-Hospital Mortality

Mortality in our series was somewhat higher than in recently published series,<sup>26</sup> but with no difference between the two devices. Of the 12 deaths (1 due to perforation by the pacemaker lead, 5 due to vascular complications, 1 due to respiratory failure, 2 due to infections, 2 due to cardiogenic shock), only 1 was directly related to the valve. Analysis of the causes of mortality suggests that instruments should be handled with extreme caution, intubation avoided (at least in patients with pulmonary disease), probe and catheter time reduced to prevent infections, and vascular complications prevented or treated as early as possible, as a complication is often followed by multiorgan failure leading to the death of the patient.

The operator's degree of experience is an important factor in the success rate, complications, and procedural mortality,<sup>12</sup> but so is the level of coordination among the entire multidisciplinary team involved in the assessment, intervention and post-procedural management of these patients.

The procedure still involves appreciable risk, whichever of these devices is used. A consensus document produced by expert representatives of the European Association of Cardio-Thoracic Surgery, the European Association of Percutaneous Cardiovascular Interventions and the European Society of Cardiology<sup>27</sup> recommended strict adherence to the initial guidelines for severe symptomatic aortic stenosis and HSR.

### CONCLUSIONS

The TF implantation of an aortic valve prosthesis is a procedure that has already been incorporated into clinical practice for patients with severe symptomatic aortic stenosis and at HSR. The use of the two commercial devices can increase the percentage of patients treated using the TF approach. Although there are technical features common to each device, such as their preparation and implantation, they have many other points in common, such as patient selection, instrumentation during the procedure, and the prevention, diagnosis and treatment of complications. Vascular complications are frequent with both devices. In the case of the ES these are due to dissection or femoral rupture caused by the high profile of the device, and in the case of the MCV these are caused by failed percutaneous closure. AV block is more frequent with the MCV prosthesis and may occur later, in contrast to early AV block caused by the ES device. Although the procedural morbidity and mortality rate with each device is acceptable in these types of patients, the risk of severe complications and the lack of data on the durability of these commercial devices suggest that their use should be restricted to high-risk patients. The results of randomized studies currently underway will clarify the efficacy and safety of the various aortic valve replacement techniques (surgical, TA or TF) in the treatment of these patients.

## ACKNOWLEDGEMENTS

We would like to thank Dr Pepa Pérez-Vizcayno for her invaluable help in processing patient data and the nurses of the Cardiac Catheterization Unit of the San Carlos Hospital for their involvement and enthusiasm in the development of this new technique.

## CONFLICTS OF INTEREST

Dr. E. García is proctor of Edwards Lifesciences.

## REFERENCES

- Cribier A, Etchaninoff H, Bash A, Borenstein N, Tron C, Bauer F, et al. Percutaneous transcatheter implantation of an aortic valve prosthesis for calcific aortic stenosis. First human case description. *Circulation*. 2002;106:3006–8.
- Grube E, Laborde JC, Gerckens U, Felderhoff T, Sauren B, Buellesfeld L, et al. Percutaneous implantation of the CoreValve self-expanding valve prosthesis in high-risk patients with aortic valve disease: the Siegburg first-in-man study. *Circulation*. 2006;114:1616–24.
- Cribier A, Etchaninoff H, Tron C, Bauer F, Agatiello C, Nercolini D, et al. Treatment of calcific aortic stenosis with the percutaneous heart valve: mid-term follow-up from the initial feasibility studies: the French experience. *J Am Coll Cardiol*. 2006;47:1214–23.
- Webb JG, Chandavimol M, Thompson CR, Ricci DR, Carere RG, Munt BI, et al. Percutaneous aortic valve implantation retrograde from the femoral artery. *Circulation*. 2006;113:842–50.
- Webb JG, Pasupati S, Humphries K, Thompson C, Altwegg L, Moss R, et al. Percutaneous transarterial aortic valve replacement in selected high-risk patients with aortic stenosis. *Circulation*. 2007;116:755–63.
- Lichtenstein SV, Cheung A, Ye J, Thompson CR, Carere RG, Pasupati S, et al. Transapical transcatheter aortic valve implantation in humans: initial clinical experience. *Circulation*. 2006;114:591–6.
- Walther T, Simon P, Dewey T, Wimmer-Greinecker G, Falk V, Kasimir MT, et al. Transapical minimally invasive aortic valve implantation: multicenter experience. *Circulation*. 2007;116:1240–5.
- Piazza N, Grube E, Gerckens U, Den Heijer P, Linke A, Luha O, et al. Procedural and 30-day outcomes following transcatheter aortic valve implantation using the third generation (18F) CoreValve revalving system: results from the multicentre, expanded evaluation registry 1-year following CE mark approval. *EuroIntervention*. 2008;4:242–9.
- Grube E, Buellesfeld L, Mueller R, Sauren B, Zickmann B, Nair D, et al. Progress and current status of percutaneous aortic valve replacement: results of three device generations of the CoreValve revalving system. *Circ Cardiovasc Interv*. 2008;1:167–75.
- Rodés-Cabau J, Webb JB, Anson C, Ye J, Dumont E, Feindel C, et al. Transcatheter aortic valve implantation for the treatment of severe symptomatic aortic stenosis in patients at very high or prohibitive surgical risk. Acute and late outcomes of the multicenter Canadian experience. *J Am Coll Cardiol*. 2010;55:1080–90.
- Otten AM, Van Domburg RT, Van Gameren M, Kappetein AP, Takkenberg JJ, Bogers AJ, et al. Population characteristics, treatment assignment and survival of patients with aortic stenosis referred for percutaneous valve replacement. *EuroIntervention*. 2008;4:250–5.
- Webb JG, Altwegg L, Boone R, Cheung A, Ye J, Lichtenstein S, et al. Transcatheter aortic valve implantation. Impact on clinical and valve-related outcomes. *Circulation*. 2009;119:3009–16.
- Himbert D, Descoutures F, Al-Attar N, lung B, Ducrocq G, Détaint D, et al. Results of transfemoral and transapical aortic valve implantation following a uniform assessment in high-risk patients with aortic stenosis. *J Am Coll Cardiol*. 2009;54:303–11.
- García E, Pinto AG, Sarnago F, Pello AM, Paz M, García-Fernández MA, et al. Implantación percutánea de prótesis valvular aórtica: experiencia inicial en España. *Rev Esp Cardiol*. 2008;61:1210–4.
- Moreno R, Calvo L, Filgueiras D, López T, Sánchez-Recalde A, Jiménez-Valero S, et al. Implantación percutánea de prótesis valvulares aórticas en pacientes con estenosis aórtica severa sintomática rechazados para cirugía de sustitución valvular. *Rev Esp Cardiol*. 2008;61:1215–9.
- Rodríguez JE, Maroto L, Cobiella J, Silva J, Bañuelos C, Hernández-Antolín R, et al. Implantación de prótesis aórticas vía transapical. Experiencia inicial. *Rev Esp Cardiol*. 2009;62:933–6.
- Avanzas P, Muñoz-García A, Segura J, Pan M, Alonso Briaies JH, Lozano I, et al. Implante percutáneo de la prótesis valvular aórtica autoexpandible CoreValve en pacientes con estenosis aórtica severa: experiencia inicial en España. *Rev Esp Cardiol*. 2010;63:141–8.
- Bleiziffer S, Ruge H, Mazzitelli D, Schreiber C, Hutter A, Laborde JC, et al. Results of percutaneous and transapical transcatheter aortic valve implantation performed by a surgical team. *Eur J Cardiothorac Surg*. 2009;35:615–21.
- Tchetche D, Dumonteil N, Sanguet A, Descoutures F, Luz A, Garcia O, et al. Thirty-day outcome and vascular complications after transarterial aortic valve implantation using both Edwards Sapien and Medtronic CoreValve bioprostheses in a mixed population. *EuroIntervention*. 2010;5:659–65.
- Etchaninoff H, Kerkeni M, Zajarías A, Tron C, Godin M, Sanchez Giron C, et al. Aorto-iliac angiography as a screening tool in selecting patients for transfemoral aortic valve implantation with the Edwards SAPIEN bioprosthesis. *EuroIntervention*. 2009;5:438–42.
- Al-Attar N, Himbert D, Descoutures F, lung B, Raffoul R, Messika-Zeitoun D, et al. Transcatheter aortic valve implantation: selection strategy is crucial for outcome. *Ann Thorac Surg*. 2009;87:1757–62.
- Kahlert P, Al-Rashid F, Weber M, Wendt D, Heine T, Kottenberg E, et al. Vascular access site complications after percutaneous transfemoral aortic valve implantation. *Herz*. 2009;34:398–408.
- Ducrocq G, Francis F, Serfaty JM, Himbert D, Maury JM, Pasi N, et al. Vascular complications of transfemoral aortic valve implantation with the Edwards SAPIEN prosthesis: incidence and impact on outcome. *EuroIntervention*. 2010;5:666–72.
- Masson JB, Kovac J, Schuler G, Ye J, Cheung A, Kapadia S, et al. Transcatheter aortic valve implantation: review of the nature, management, and avoidance of procedural complications. *JACC Cardiovasc Interv*. 2009;2:811–20.
- Jilaihawi H, Chin D, Vasa-Nicotera M, Jeilam M, Spyt T, Ng GA, et al. Predictors for permanent pacemaker requirement after transcatheter aortic valve implantation with the CoreValve bioprosthesis. *Am Heart J*. 2009;157:860–6.
- Rodés-Cabau J. Avances en la implantación percutánea de válvulas en posición aórtica. *Rev Esp Cardiol*. 2010;63:439–50.
- Vahanian A, Alfieri O, Al-Attar N, Antunes M, Bax J, Cormier B, et al. Transcatheter valve implantation for patients with aortic stenosis: a position statement from the European Association of Cardio-Thoracic Surgery (EACTS) and the European Society of Cardiology (ESC) in collaboration with the European Association of Percutaneous Cardiovascular Interventions (EAPCI). *EuroIntervention*. 2008;4:193–9.