

Our study has the limitations derived from its design and the small number of patients included, as it evaluates an uncommon treatment. Nonetheless, it may be an indication of typical clinical practice.

In conclusion, this study is the first to provide data on patients initially treated with iP2Y₁₂ monotherapy. This therapeutic strategy is not commonly used in clinical practice but is a reasonable choice for patients who cannot receive DAPT containing aspirin, as the outcome at 36 months was similar to that of patients receiving DAPT. Furthermore, the new iP2Y₁₂ agents could be an option when APM is needed, particularly after the acute phase has passed.

CONFLICTS OF INTEREST

I.J. Núñez-Gil has participated in lectures for AstraZeneca and Lilly, and has served as an advisor for AstraZeneca. E. Cerrato is a speaker for AstraZeneca Italy and has received research grants from AstraZeneca Spain.

Iván Javier Núñez-Gil,^{a,*} Andrés Aldazábal,^a Enrico Cerrato,^{b,c} Pablo Salinas,^a María José Pérez-Vizcayno,^a and Antonio Fernández-Ortiz^a

^aUnidad de Cardiología Intervencionista, Instituto Cardiovascular, Hospital Clínico San Carlos, Madrid, Spain

^bDepartamento de Cardiología Intervencionista, Hospital Infermi, Rivoli, Turin, Italy

^cDepartamento de Cardiología, Hospital Universitario San Luigi, Orbassano, Turin, Italy

*Corresponding author:

E-mail address: ibnsky@yahoo.es (I.J. Núñez-Gil).

Available online 31 October 2017

REFERENCES

1. Park TK, Song YB, Gwag HB, et al. Aspirin versus clopidogrel following dual antiplatelet therapy on the era of drug eluting stents. *J Am Coll Cardiol*. 2014;63:A1612.
2. Abraham NS, Members WC, Hlatky MA, et al. ACCF/ACG/AHA 2010 Expert Consensus Document on the Concomitant Use of Proton Pump Inhibitors and Thienopyridines: A Focused Update of the ACCF/ACG/AHA 2008 Expert Consensus Document on Reducing the Gastrointestinal Risks of Antiplatelet Therapy and NSAID Use. *Circulation*. 2010;122:2619–2633.
3. Ferreira-González I, Marsal JR, Ribera A, et al. Double antiplatelet therapy after drug-eluting stent implantation: risk associated with discontinuation within the first year. *J Am Coll Cardiol*. 2012;60:1333–1339.
4. Mehran R, Baber U, Steg PG, et al. Cessation of dual antiplatelet treatment and cardiac events after percutaneous coronary intervention (PARIS): 2 year results from a prospective observational study. *Lancet*. 2013;382:1714–1722.
5. Storey RF, Angiolillo DJ, Patil SB, et al. Inhibitory effects of ticagrelor compared with clopidogrel on platelet function in patients with acute coronary syndromes: the PLATO (PLATelet inhibition and patient Outcomes) PLATELET substudy. *J Am Coll Cardiol*. 2010;56:1456–1462.
6. Vega-Hernández B, Bangüeses-Quintana R, Samaniego-Lampón B, Lozano Martínez-Luengas Íaue, Gala-Ortiz G, Segovia-Martínez de Salinas E. Rapid desensitization to aspirin in patients with coronary artery disease: a single center experience. *Rev Esp Cardiol*. 2016;69:795–797.

<http://dx.doi.org/10.1016/j.rec.2017.10.001>

1885-5857/

© 2017 Sociedad Española de Cardiología. Published by Elsevier España, S.L.U. All rights reserved.

Functional and Morphological Assessment of Left Anterior Descending Artery in Patients With Tako-tsubo Syndrome



Análisis morfológico y funcional de la arteria descendente anterior de pacientes con síndrome de tako-tsubo

To the Editor,

Tako-tsubo syndrome (TKS) is a clinical syndrome characterized by reversible left ventricular dysfunction in the absence of epicardial coronary obstruction. Although several pathogenic mechanisms have been proposed (ie, multivessel epicardial spasm, catecholamine-induced myocardial stunning, spontaneous coronary thrombus lysis, and acute microvascular spasm), its causes are still unknown.^{1,2} Possible causes of TKS are the presence of vulnerable plaques or flow alteration, but they have not been well elucidated.

In our study, we sought to perform a functional and morphological assessment of the left anterior descending artery (LAD) in TKS patients by using optical coherence tomography (OCT) and pressure-temperature wire.

From January 2016 to May 2017, 14 consecutive TKS patients, admitted to 2 institutions and defined accordingly to Mayo Clinic diagnostic criteria,¹ were included. The study was approved by the ethics committee of our center and each patient provided written informed consent. A pressure-temperature guidewire (Certus, St Jude) was introduced in the LAD at the level of the second diagonal branch. After induction of hyperemia with adenosine (140 µg/kg/min), fractional flow reserve and the index of microcirculatory resistance (IMR) were measured as previously shown.³ Fractional flow reserve and IMR were considered abnormal if < 0.80

and > 22, respectively.³ OCT acquisition was then performed using a commercially available system for intracoronary imaging (C7XR Fourier-Domain System; LightLab Imaging, Westford, Massachusetts, United States) on the LAD (at least 50 mm) during continuous injection of contrast medium (3 mL/s, iodixanol 370, visipaque, GE Health Care, Cork, Ireland) through the guide catheter with an injection pump. The presence of coronary plaque on OCT pullback was analyzed offline by 2 independent investigators (LightLab Imaging, Westford, Massachusetts, United States).

Thirteen patients (92.8%) were women, with a mean ± standard deviation age of 66.1 ± 11.5 years. Coronary angiography showed no significant stenosis of at least 50% in the LAD. OCT and pressure-temperature wire analysis were performed in 14 and 12 patients, respectively. OCT analysis showed a normal 3-layer vessel wall, without atherosclerotic plaque, images of plaques rupture, plaques erosion, or intraluminal thrombus. None of the patients had fractional flow reserve ≤ 0.80, with a mean value of 0.96 ± 0.18, while 10 (83.3%) patients had microvascular dysfunction with IMR ± standard deviation of 33.8 ± 11.4 (Table).

The physiopathology of TKS is unknown, but can be related to intracoronary thrombus, either emerging from a ruptured thin-cap fibroatheroma or plaque erosion in the LAD, which is responsible for the typical left ventricle appearance. Coronary thrombus or at least the coronary plaque, which has led to thrombus formation, may be undetectable by coronary angiography, but may be seen on OCT.⁴ Nevertheless, our OCT analysis did not show any coronary plaque or thrombotic remnants on LAD, also excluding the presence of any atherosclerotic coronary plaque. This is in contrast with a recent study that showed a high prevalence of atherosclerotic plaques in these patients without any plaque rupture or thrombi.⁵ Unlike that study, our patients were younger with fewer

Table

Baseline Clinical Characteristics of the Tako-tsubo Syndrome Patients

Patient	Age, y	Sex	Cardiovascular risk factors	Stressful event	Ballooning pattern	Initial EF %	Discharge EF%	Time since symptom to pressure-temperature wire measurement (hours)	FFR	IMR	OCT
1	67	M	Smoking	Physical	Apical	40	56	NA	NA	NA	Normal
2	71	F	None	Physical	Apical	40	55	4	0.96	51.8	Normal
3	50	F	Smoking	Emotional	Apical	60	59	NA	NA	NA	Normal
4	55	F	Smoking	Emotional	Apical	34	43 (55, 1 month after discharge)	12	0.96	43.3	Normal
5	70	F	Hypertension, hypercholesterolemia	Emotional	Apical	40	51 (63, 1 month after discharge)	8	0.97	39.2	Normal
6	86	F	Hypertension	Physical	Apical	35	55	18	0.94	33	Normal
7	72	F	None	Emotional	Apical	50	60	8	0.96	37.2	Normal
8	68	F	Hypertension, hypercholesterolemia	Emotional	Apical	45	50 (65, 1 month after discharge)	120	0.92	26.9	Normal
9	63	F	Hypertension	Emotional	Midventricular	35	45 (55, 1 month after discharge)	18	0.98	19	Normal
10	47	F	Hypertension, hypercholesterolemia	Emotional	Apical	30	60	4	0.95	25.6	Normal
11	61	F	Hypertension	Physical	Apical	40	60	254	0.96	10.9	Normal
12	83	F	Hypertension, hypercholesterolemia	Emotional	Apical	40	60	27	0.98	37	Normal
13	59	F	Hypertension, hypercholesterolemia	Emotional	Apical	35	65	11	0.98	39	Normal
14	64	F	Hypercholesterolemia	Emotional	Apical	55	60	12	0.96	43	Normal

EF, ejection fraction; F, female; FFR, fractional flow reserve; IMR, index of microcirculatory resistance; M, male; NA, not available; OCT, optical coherence tomography.

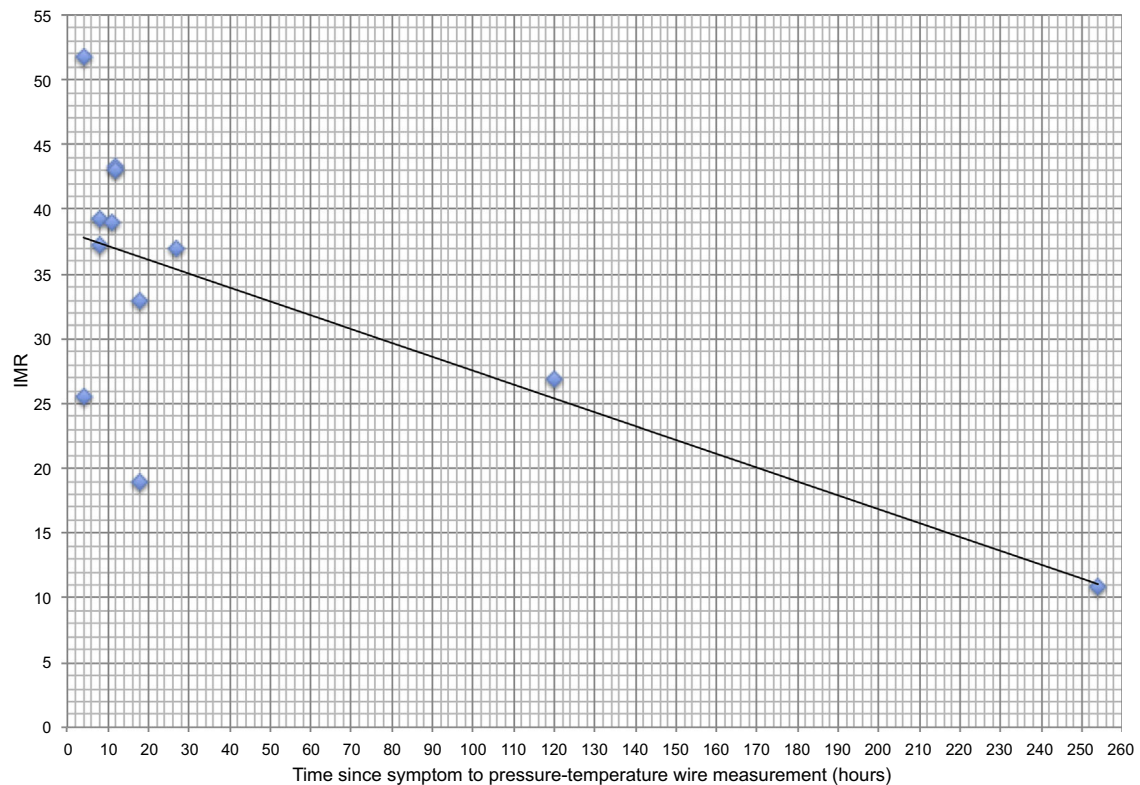


Figure. Correlation between IMR and time since symptoms onset to IMR measurement. IMR, index microcirculation resistance.

cardiovascular risk factors, suggesting that the presence of atherosclerotic plaques could be a finding with no causal relationship with TKS. Despite the lack of epicardial lesions, we show that some degree of microvascular dysfunction may be present. In the absence of

atherosclerotic alteration on epicardial vessels, this dysfunction can be caused either by thrombi or by intense and temporary spasms in the coronary microcirculation. Thrombi embolism from the epicardial vessel can be excluded by our OCT findings. A significant

negative correlation was also found between the extent of microvascular dysfunction and the time from symptom onset to IMR analysis ($R = -0.69$; $P = .012$), in line with previous data⁶ (Figure). In particular, a normal IMR value was found in a patient studied 10 days after the appearance of initial symptoms, suggesting the reversibility of this microvascular dysfunction.

In conclusion, our study shows that LAD of TKS patients may exhibit some degree of microvascular dysfunction in the absence of atherosclerotic or vulnerable plaque. Future studies are needed to further determine the causes of this dysfunction.

FUNDING

G. Jiménez Brítez received a grant from Coronary and Structural Course in Barcelona 2015 for this study.

Gustavo Jiménez Brítez,^a Manel Sabaté,^a Carlos Robles,^a Pablo Elpidio García-Granja,^b Ignacio J. Amat-Santos,^b and Salvatore Brugaletta^{a,*}

^aInstituto Cardiovascular, Hospital Clinic de Barcelona, Institut d'Investigacions Biomèdiques August Pi i Sunyer (IDIBAPS), Barcelona, Spain

^bDepartamento de Cardiología, CIBERCV, Hospital Clínico Universitario de Valladolid, Instituto de Ciencias del Corazón (ICICOR), Valladolid, Spain

*Corresponding author:

E-mail address: sabrugal@clinic.ub.es (S. Brugaletta).

Available online 18 September 2017

REFERENCES

1. Galiuto L, De Caterina AR, Porfidi A, et al. Reversible coronary microvascular dysfunction: a common pathogenic mechanism in apical ballooning or Tako Tsubo syndrome. *Eur Heart J*. 2010;31:1319–1327.
2. Núñez Gil JJ, Andrés M, Almendro Delia M, et al. Characterization of Tako-tsubo Cardiomyopathy in Spain: Results from the RETAKO National Registry. *Rev Esp Cardiol*. 2015;68:505–512.
3. Kim HS, Tremmel JA, Nam CW, et al. Quantitative comparison of microcirculatory dysfunction in patients with stress cardiomyopathy and ST-segment elevation myocardial infarction. *J Am Coll Cardiol*. 2011;58:2430–2431.
4. Alfonso F, Núñez-Gil JJ, Hernández R. Optical coherence tomography findings in Tako Tsubo cardiomyopathy. *Circulation*. 2012;126:1663–1664.
5. Eitel I, Stiermaier T, Graf T, et al. Optical Coherence Tomography to evaluate plaque burden and morphology in patients with takotsubo syndrome. *J Am Heart Assoc*. 2016;5:e004474.
6. Rivero F, Cuesta J, García-Guimaraes M, et al. Time Related Microcirculatory Dysfunction in Patients with takotsubo cardiomyopathy. *JAMA Cardiol*. 2017;2:699–670.

<http://dx.doi.org/10.1016/j.rec.2017.08.013>

1885–5857/

© 2017 Sociedad Española de Cardiología. Published by Elsevier España, S.L.U. All rights reserved.

Experience With the Absorb Bioresorbable Vascular Scaffold in Various Scenarios of Congenital Heart Disease



Experiencia con el armazón vascular bioabsorbible Absorb en varios escenarios de cardiopatías congénitas

To the Editor,

Percutaneous treatment in children with congenital heart disease has continued to evolve in recent years. Stent implantation plays an important role in some of these diseases.¹ However, because vessel growth is rapid in infants, there is a need for subsequent stent redilations, surgical removal, or complicated surgical reintervention. This problem could be resolved by a bioresorbable stent.²

The ideal bioresorbable stent in pediatric patients would provide sufficient radial force and acceptable flexibility for deployment into distal arteries, should be low profile, and would disappear without creating a significant local inflammatory response or systemic toxicities.

The bioresorbable vascular scaffold (BVS) (Abbott) is the most advanced, well-studied bioresorbable stent.³ The product is available in multiple sizes and it fully reabsorbs within 3 years and provides mechanical support for up to 6 to 12 months.⁴ Due to the features described, the Absorb-BVS, could meet the needs of pediatric patients.

The aim of our study was to describe our experience with BVS in the setting of various vascular lesions in children with congenital heart disease.

A retrospective, interventional and clinical follow-up study was conducted. The primary outcome measures were procedural success and complication rates. Informed consent was obtained in all patients.

BVS implantation was performed in 8 patients as an alternative to surgical intervention or bare-metal stent implantation, bridging the patient in some cases to a future more definitive surgical

intervention. The median age was 3.8 months (10 days–6.3 years) and the median weight was 3.95 kg (range, 2.3–20). The demographic data and types of vessel obstruction are summarized in the Table.

Based on the type of lesion, vascular access was gained via the femoral vein ($n = 5$) or the femoral artery ($n = 2$) and there was 1 hybrid procedure through the right ventricular free wall. Vessel lesion morphology and critical diameter were assessed angiographically. If there was pre-existing critical vessel obstruction and as a guide for proper implantation, we performed balloon predilation of the vessel in 5 patients. After the decision to implant a stent was confirmed, the Absorb-BVS was implanted. The stent sizes (mm) used were 3.5 x 12 ($n = 5$), 2.5 x 12 ($n = 1$), and 3 x 12 ($n = 2$). Vascular stenting was achieved in all patients. No recoil of the stent was observed. In 6 patients, subsequent stent overdilation was necessary to achieve the maximum diameter of the native vessel. The angiographic result was satisfactory in all patients (Figure). There were no procedure-related complications. Improvement in hemodynamic parameters or clinical recovery was achieved in all patients in the acute follow-up.

Patients underwent serial echocardiographic and clinical follow-up to evaluate hemodynamic status and the patency of the stented area. The median follow-up period was 82.1 days (range, 3–155). Angiographic reevaluation was performed in 2 patients. In patient No. 2, a balloon overdilation was performed 71 days after implantation; however, we were unable to achieve clear improvement and 5 days later the patient was accepted for total surgical correction. Patient No. 5, was reevaluated 142 days after the procedure to check vessel integrity and growth. Angiography showed the permeability and lumen integrity of the stented vessel. Four more patients underwent successful corrective surgery (Table).

With the concept of temporary scaffolding, biodegradable stents might solve one of the greatest challenges in pediatric congenital heart disease intervention: adaptation to growth.¹ So far, there is little published information on BVS use in pediatric patients.⁵ BVS