

vascular surgery, which means that hybrid procedures are becoming increasingly important.

Although this technique has been described in some isolated cases,^{2,3} we present the first report in Spain of a hybrid procedure involving pneumology, thoracic surgery, and interventional cardiology to resolve a postoperative fistula.

In this case, closure using an Amplatzer® was proposed as an alternative after closure by bronchoscopy with a tissue sealant had failed, as published elsewhere.² Nevertheless, this could become a first-line technique in this condition as experience with the procedure is gained. One case has already been described in which the technique was used as the first-line option³; in patients like ours who have previously received chemotherapy and radiotherapy, and in whom surgery may be more complex, it is even more justified to consider it as a first-line option.

In short, this technique can provide a solution to complications stemming from other medical and surgical specialties and is an example of the possibilities offered by hybrid procedures between various specialties and different techniques.

José Antonio Fernández-Díaz,^a Cristina García-Gallo,^b
Javier Goicolea-Ruigómez,^{a,*} and Andrés Varela-de Ugarte^c

^aUnidad de Cardiología Intervencionista, Hospital Universitario Puerta de Hierro, Majadahonda, Madrid, Spain

^bServicio de Neumología, Hospital Universitario Puerta de Hierro, Majadahonda, Madrid, Spain

^cServicio de Cirugía Torácica, Hospital Universitario Puerta de Hierro, Majadahonda, Madrid, Spain

*Corresponding author:

E-mail address: jgoicolea@hotmail.com (J. Goicolea-Ruigómez).

Available online 23 May 2011

REFERENCES

1. Darling GE, Abdurahman A, Yi QL. Risk of a right pneumonectomy: role of bronchopleural fistula. *Ann Thorac Surg*. 2005;79:433.
2. Boudoulas KD, Elinoff J, Resar JR. Bronchopulmonary fistula closure with an Amplatzer multi-fenestrated septal occluder. *Catheter Cardiovasc Interv*. 2010;75:455–8.
3. Kramer MR, Peled N. Use of Amplatzer device for endobronchial closure of bronchopleural fistulas. *Chest*. 2008;133:1481–4.

doi:10.1016/j.rec.2010.12.012

Heart Transplantation in an HIV-1-Infected Patient With Ischemic Cardiomyopathy and Severe Pulmonary Hypertension

Trasplante cardíaco en un paciente infectado por VIH-1 con miocardiopatía isquémica e hipertensión pulmonar grave

To the Editor,

We report the case of a 39-year-old homosexual male patient diagnosed through routine testing in 1998 as infected with human immunodeficiency virus type 1 (HIV-1). He had not developed any AIDS-defining disease and had no history of intravenous drug abuse, hepatitis C or B viral infection. His CD4+ T-cell count at the time of presentation was 758 cells/ μ L; the

nadir CD4+ T-cell count was 512 cells/ μ L. Plasma RNA HIV-1 viral load was always undetectable (<50 copies/mL). He was treated with a fixed-dose formulation of 3 nucleoside analog reverse transcriptase inhibitors: zidovudine, lamivudine and abacavir (Trizivir®).

In August 2000 he suffered the first clinical manifestation of coronary artery disease (CAD) when he was admitted for an inferior ST-elevation acute myocardial infarction (STEMI). In August 2004, after a new anterior NSTEMI, his left ventricular ejection fraction was 20%. From this moment on, the patient developed progressive shortness of breath and symptoms of right heart failure. He required several hospitalizations despite optimized therapy, and was referred to our heart failure and heart transplantation (HTX) unit for evaluation. Right heart catheterization showed non-reversible

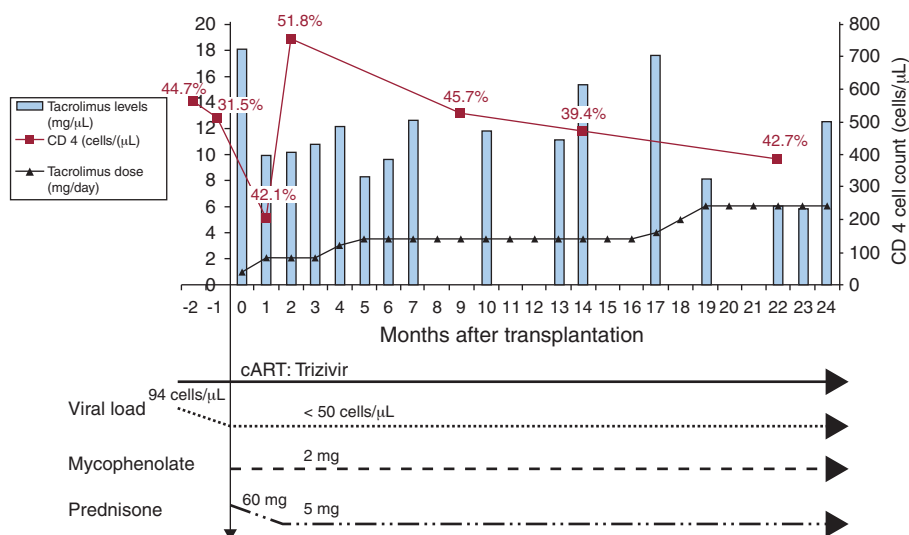


Figure 1. CD4+ T-cell count and percentage of lymphocytes, HIV-1 viral load, antiretroviral regimen and immunosuppressant drugs from heart transplantation to 24 months follow-up. cART, combined antiretroviral therapy.

pulmonary arterial hypertension (PAH) that precluded HTX consideration. Treatment with sildenafil citrate 20 mg TID was initiated and gradually up-titrated to 100 mg TID. After achieving target doses, a new right heart catheterization showed improved pulmonary resistance with reversible PAH. The pre-transplant study did not show any formal contraindication for HTX. Because of the patient's critical end-stage heart failure, young age, excellent response to combined antiretroviral therapy (cART) and lack of comorbidities, he was listed for HTX July 19, 2006. On September 7, 2007, the patient underwent successful elective orthotopic HTX.

The post-operative course was uncomplicated, standard induction was done with basiliximab 20 mg within 24 h of HTX and at 4 days post-transplant. Routine immunosuppression treatment with methylprednisolone, tacrolimus and mycophenolate mofetil was initiated the day of surgery. The dose of tacrolimus required to achieve the target level of 10–15 mg/dL was low during the first 6 months after transplantation (2 mg daily) and increased with time to the standard dose (6 mg daily). The cART was restarted on day 3 after HTX. Postoperatively, consistent improvement in PAH allowed the progressive withdrawal of sildenafil citrate until discontinuation.

It is now 3 years from HTX and the patient has improved remarkably. He has resumed work and leads an active life. Over this time, the patient had 1 episode, at 2 months after HTX, of acute rejection (International Society for Heart and Lung Transplantation grade 3A) requiring treatment with high-dose corticosteroids. Left heart catheterization at 1 year after HTX showed normal coronary arteries. He has not developed any focal or disseminated bacterial, viral, or fungal infection or any AIDS-defining disease. Weekly cytomegalovirus pp65 antigenemia testing was always negative. Under the cART regimen in addition to standard doses of immunosuppressant drugs, no pharmacokinetic interaction was detected. The CD4+ T-cell count evolution over time ranged between 201 and 754 cells/ μ L (Fig. 1).

The survival and quality of life in patients infected with HIV has dramatically changed since the introduction of cART in 1996.¹ However, as HIV-1-related mortality decreases, cardiovascular diseases have become the primary cause of mortality in these patients. Antiretroviral regimes may cause dyslipemia, insulin resistance, and type 2 diabetes mellitus and have been associated to accelerated CAD.² In this population, the incidence of CAD is increased 2-fold and the expected number of patients with end-stage heart failure secondary to ischemic heart disease is likely to increase. To our knowledge, ours is the first report of an HIV-infected heart recipient with ischemic cardiomyopathy. From the reported cases, 1 patient had advanced AIDS before HTX and survived only 3.5 years after.³ The other 5 transplant recipients,

similar to our case, were on cART regimes and had undetectable virus load, no AIDS-related manifestations, and uncomplicated post-operative courses. All of these patients suffered non-ischemic dilated cardiomyopathy.⁴

Although the first experiences with cardiac transplantation in very selected HIV-1-infected patients show very encouraging results, further reports and longer follow-ups are needed to elucidate possible HTX candidates when HIV infection coexists.

FUNDING

Partially supported by the cooperating network of AIDS research teams of the *Fondo de Investigación Sanitaria* (FIS) and grant ISCIII-RETIC RD06/006 from the *Instituto de Salud Carlos III*, Madrid, Spain. Dr. J.M. Miró received a Research Grant from the *Institut d'Investigacions Biomèdiques August Pi i Sunyer* (IDIBAPS).

María Angeles Castel,^{a,*} Félix Pérez-Villa,^a Eulalia Roig,^a and José María Miró^b

^a*Departamento de Cardiología, Instituto del Tórax, Hospital Clínic, Institut d'Investigacions Biomèdiques August Pi i Sunyer (IDIBAPS), Universidad de Barcelona, Barcelona, Spain*

^b*Servicio de Enfermedades Infecciosas, Instituto Clínic de Medicina y Dermatología, Hospital Clínic, Institut d'Investigacions Biomèdiques August Pi i Sunyer (IDIBAPS), Universidad de Barcelona, Barcelona, Spain*

* Corresponding author:

E-mail address: macastel@clinic.ub.es (M.A. Castel).

Available online 4 May 2011

REFERENCES

1. The Antiretroviral Therapy Cohort Collaboration. Life expectancy of individuals on combination antiretroviral therapy in high-income countries. *Lancet*. 2008;372:293–9.
2. The Data Collection on Adverse Events of Anti-HIV Drugs (DAD) Study Group. Combination antiretroviral therapy and the risk of myocardial infarction. *N Engl J Med*. 2003;349:1993–2003.
3. Calabrese LH, Albrecht M, Young J, McCarthy P, Haug M, Jarcho J, et al. Successful cardiac transplantation in an HIV-1-infected patient with advanced disease. *N Engl J Med*. 2003;348:2323–8.
4. Uriel N, Jorde UP, Cotarlan V, Colombo PC, Farr M, Restaino SW, et al. Heart transplantation in human immunodeficiency virus-positive patients. *J Heart Lung Transplant*. 2009;28:667–9.

doi:10.1016/j.rec.2010.12.013

Closure of Ventricular Septal Defect After Surgical Septal Myectomy by Hybrid Procedure in an Adult Patient

Cierre de comunicación interventricular tras miectomía septal quirúrgica mediante procedimiento híbrido en un paciente adulto

To the Editor,

Iatrogenic ventricular septal defect (VSD) is a rare complication following septal myectomy that can cause a rapid postoperative hemodynamic deterioration. We report the case of a 76-year-old dyslipidemic, hypertensive woman who presented with a several-

month history of progressive dyspnea. The diagnosis was severe degenerative aortic stenosis, severe hypertrophy of the basal septum (22 mm) with a subaortic gradient of 30 mmHg, and a mild double mitral valve lesion. On the basis of these findings and a EuroSCORE of 6, the decision was made to perform double valve replacement, mitral and aortic, with bioprostheses, as well as septal myectomy.

The postoperative course was indolent and the patient developed complete atrioventricular block that required implantation of a permanent pacemaker. Transthoracic and transesophageal echocardiography (TEE) led to the diagnosis of a VSD measuring approximately 5 mm following myectomy. This defect produced severe pulmonary hypertension (85 mmHg) with moderate-to-severe tricuspid insufficiency and a situation of low output (Fig. 1). Due to the progressive hemodynamic