

## High-definition Intravascular Ultrasound Vs Optical Coherence Tomography: Preliminary Experience



### Ecografía intravascular de alta definición frente a tomografía de coherencia óptica: experiencia inicial

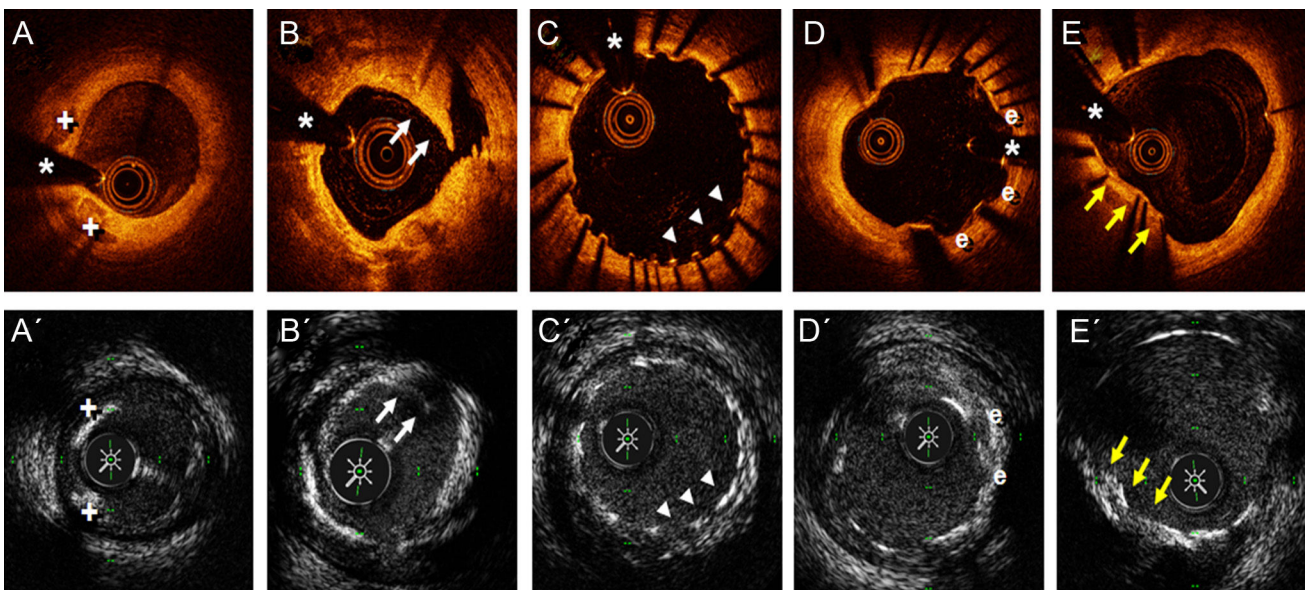
#### To the Editor,

High-definition intravascular ultrasound (HD-IVUS) that uses 60 MHz transducers is the latest advance in the development of this imaging technique. HD-IVUS allows not only higher spatial resolution, but also faster acquisition speed (withdrawal speed of up to 10 mm/s, at 60 images/s) than conventional 40 MHz IVUS.<sup>1-3</sup> However, currently there is little evidence to advocate its clinical use.<sup>1</sup> The aim of the present study was to prospectively analyze the usefulness of HD-IVUS in a small series of consecutive patients, by comparing the findings with those obtained from optical coherence tomography (OCT).

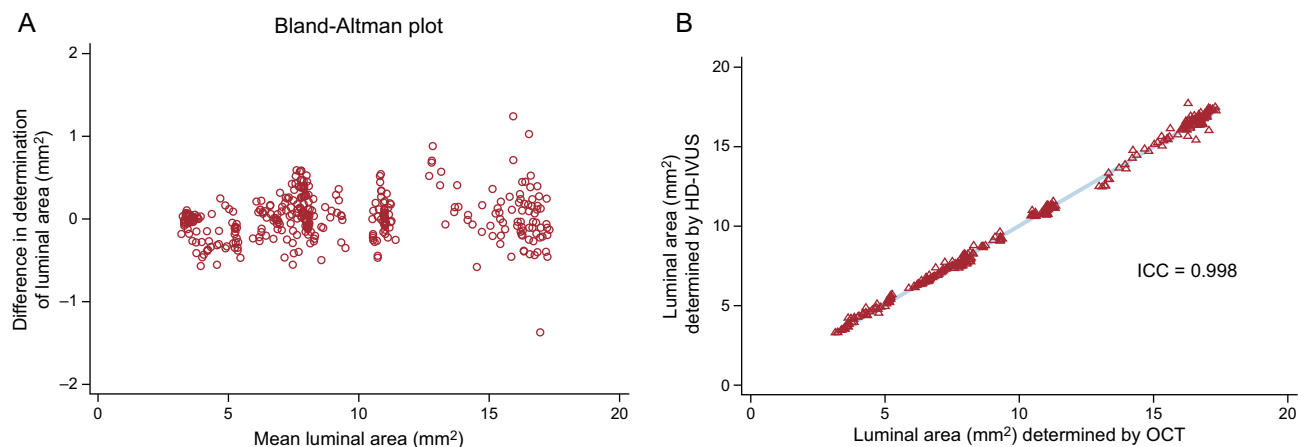
We selected 4 consecutive patients who, after providing signed, informed consent, were systematically examined with HD-IVUS and OCT in the proximal and medial segments of 2 coronary arteries (8 arteries in total). One of the 4 patients underwent percutaneous coronary intervention with stent implantation, after which both imaging techniques were repeated. For the HD-IVUS study, we used a Kodama catheter (ACIST Medical Systems; Eden Prairie, Minnesota, USA) at 10 mm/s, and for OCT, we used a Dragonfly OPTIS catheter (St Jude Medical; St Paul, Minnesota, USA) with an angiographic coregistration system. For quantitative analysis, we selected different 5 mm-long segments of coronary artery and looked at the potentially relevant OCT findings in each artery studied (presence of atherosclerotic plaque, stented segment) or postintervention findings. As a reference, we used different markers (branches, stent edge) to ensure that exactly the same coronary segments were analyzed with both techniques. In these segments, we determined, frame by frame, both the luminal

area (LA) and the atheroma characteristics with both techniques. In stented segments, we assessed strut endothelialization, possible stent malapposition or underexpansion, and the occurrence of dissections after implantation. Quantitative data were compared using the Bland-Altman method. The mean age was  $67 \pm 12$  years and 3 of the 4 patients were male. In 3 patients, the indication for coronary angiography was angina with a positive stress test, whereas the fourth patient underwent a scheduled follow-up angiography 9 months after revascularization. In 3 patients, we evaluated the left anterior descending and right coronary arteries, and in the fourth patient, the left anterior descending and the circumflex arteries. **Figure 1** shows some of the images acquired with both techniques at the same position. In general, both techniques allowed us to correctly evaluate the presence of normal segments, detect atherosclerotic plaques and determine their characteristics, and detect the presence of calcium. Due to its higher resolution, OCT proved superior to HS-IVUS for identification of small intimal flaps after intervention, as well as in the evaluation of the degree of strut endothelialization and the presence of evaginations in the stent at follow-up. However, in all patients, both techniques allowed us to correctly identify stent malapposition and underexpansion. For quantitative analysis, a total of 400 frames of the selected segments were analyzed with both techniques. **Figure 2A** illustrates, with a Bland-Altman plot, the excellent concordance for LA determination. **Figure 2B** shows (for illustrative purposes) the data on the linear relationship between the 2 techniques for LA determination, evaluated quantitatively with determination of the intraclass correlation coefficient.

Until now, only isolated cases have been published of coronary images obtained with HD-IVUS.<sup>1</sup> The present study is the first small series to evaluate this new technology. HD-IVUS achieves a far superior image quality with an acquisition time 10 times faster than conventional IVUS. Unlike previous studies that demonstrated that conventional IVUS tended to overestimate LA compared with OCT,<sup>4</sup> in our study this phenomenon did not occur with HD-IVUS, and there was excellent concordance for LA measurement between HD-IVUS and OCT; however, due to the lower spatial



**Figure 1.** The upper row of images shows the findings from optical coherence tomography, and the lower row of images shows the findings from high-definition intravascular ultrasound. A and A' show an area of fibrocalcified plaque in the left anterior descending artery, where 2 calcified nodules are demarcated (+). B and B' show the immediate result after semicompliant balloon predilatation of a severely calcified lesion in the circumflex artery, with an image of an intimal flap (arrows) compatible with dissection. C and C' show the result at 9 months post implantation of a drug-eluting stent in the proximal right coronary artery, demonstrating the absence of strut endothelialization in 2 thirds of the circumference, as well as an area of malapposition (arrowheads). D and D' show the development of evaginations (e) in a drug-eluting stent implanted 9 months earlier. E and E' show an area of underexpansion in a drug-eluting stent implanted 9 months earlier, due to the presence of a highly-calcified eccentric plaque (arrows). \*Artefact from guidewire.



**Figure 2.** A: Bland-Altman plot showing the excellent concordance between HD-IVUS and OCT for luminal area determination. B: (illustrative only) the close linear relationship between the 2 techniques for luminal area determination, determined quantitatively from the ICC. HD-IVUS, high-definition intravascular ultrasound; ICC, intraclass correlation coefficient; OCT, optical coherence tomography.

resolution, HD-IVUS was inferior for evaluating adequate device endothelialization. However, by avoiding some of the classic limitations of OCT (aorto-ostial lesions, shadows from thrombotic material, need for contrast) and improving the resolution of conventional IVUS, HD-IVUS may represent a new tool of great interest in both clinical practice and research.

Marcos García-Guimaraes, Javier Cuesta, Fernando Rivero, Teresa Bastante, Amparo Benedicto, and Fernando Alfonso\*

Servicio de Cardiología, Hospital Universitario de La Princesa, Madrid, Spain

\* Corresponding author:

E-mail address: [falf@hotmail.com](mailto:falf@hotmail.com) (F. Alfonso).

Available online 27 April 2017

## REFERENCES

- Chin CY, Maehara A, Fall K, Mintz GS, Ali ZA. Imaging comparisons of coregistered native and stented coronary segments by high-definition 60-MHz intravascular ultrasound and optical coherence tomography. *JACC Cardiovasc Interv.* 2016;9:1305–1306.
- Nakagawa K, Tanaka S, Kitahara H, et al. Validation of high speed pullback of a novel high-definition intravascular ultrasound system. TCT 2014 [abstract]. *J Am Coll Cardiol.* 2014;64 Suppl:B102.
- Kobayashi Y, Kitahara H, Tanaka S, et al. Precision of a novel high-definition 60 MHz IVUS in quantitative measurement: comparison with conventional 40 MHz IVUS and optical coherence tomography. TCT 2014 [abstract]. *J Am Coll Cardiol.* 2014;64 Suppl:B105–B106.
- Kim IC, Nam CW, Cho YK, et al. Discrepancy between frequency domain optical coherence tomography and intravascular ultrasound in human coronary arteries and in a phantom in vitro coronary model. *Int J Cardiol.* 2016;221:860–866.

<http://dx.doi.org/10.1016/j.rec.2017.03.025>  
1885-5857/

© 2017 Sociedad Española de Cardiología. Published by Elsevier España, S.L.U. All rights reserved.

## Selection of the Best of 2017 in Heart Failure in Elderly Patients



### Selección de lo mejor del año 2017 en insuficiencia cardiaca del paciente anciano

#### To the Editor,

Frailty is a clinical syndrome characterized by decreased physiological reserve and resistance to stressors; it is thus a state of vulnerability associated with higher risk of adverse outcomes. It is more frequent in patients with comorbidity and chronic disease. In the cardiovascular disease field, most evidence on this entity is derived from studies evaluating frailty according to frailty phenotype criteria (Fried criteria). This scale considers frailty to be a biological syndrome defined by the presence of at least 3 of the following 5 domains: exhaustion, low physical activity, unintentional weight loss, slowness, and impaired grip strength. Its major limitation lies in its application to acute patients because 2 of the criteria require that the patient perform physical performance tests. A prospective cohort study included 465 patients with a mean age of 82 years who attended 3 Spanish hospital emergency departments due to acute heart failure (HF) (excluding patients with

severe functional dependency or previous diagnosis of dementia). Frailty was evaluated using 5 self-reported questions: a) exhaustion: “Do you frequently feel that everything you do is an effort?”; b) muscular strength: “Do you have difficulty standing up from a chair?”; c) slow gait speed: “Do you have significant difficulty in walking outside of your home?”; d) physical activity: “Do you not practice physical activity (walking) on a regular basis (3–4 times per week)?”; and e) weight loss: “Have you unintentionally lost weight in the past year?”. Patients were considered frail if they answered in the affirmative to 3 or more questions. In total, 36.3% of patients had frailty. These patients showed more than double the rate of 30-day all-cause death for patients attended in the emergency department.<sup>1</sup> In addition, a recent meta-analysis linked frailty with the future occurrence of cardiovascular events in the elderly population. Twenty-one studies (18 cohorts) were selected, most performed in the community, with a total of 31 343 individuals aged 65 years or older; 17.9% were frail. Cross-sectional analysis of 10 cohorts (16 400 individuals) showed that prefrailty and frailty were associated with higher risk of all types of cardiovascular disease. Analysis of the 6 prospective cohorts (18 307 individuals), with a median follow-up of 4.4 (range, 1.0–11.4) years, found earlier onset of cardiovascular disease (particularly HF) and higher mortality in prefrail and frail patients.<sup>2</sup>