

Incessant Atrial Tachycardia and a Cerebral Tumor

Joaquim Vilaplana Palomer

Servicio de Cardiología, Unidad de Arritmias, Hospital Universitario Doctor Josep Trueta, Girona, Spain

We report the case of an asymptomatic 78-year-old woman in whom incessant atrial tachycardia refractory to many pharmacological treatments appeared. Months after the appearance of atrial tachycardia, clinical neurological symptoms of a cerebral cystic tumor appeared. Treatment of the tumor resolved the rhythm disorder.

Key words: *Incessant atrial tachycardia. Cerebral cystic arachnoid tumor.*

Full English text available at: www.revespcardiol.org

Taquicardia auricular incesante y tumoración cerebral

Se presenta un caso de una paciente de 78 años, asintomática, que fue diagnosticada de taquicardia auricular incesante, refractaria a varios regímenes terapéuticos farmacológicos y que al cabo de unos meses presentó un cuadro clínico neurológico debido a una tumoración cerebral quística de situación parieto-occipital derecha que, una vez tratada, condujo a la normalización del ritmo cardíaco.

Palabras clave: *Taquicardia auricular incesante. Quiste cerebral aracnoidal.*

INTRODUCTION

Supraventricular tachycardia of atrial origin is rare in adults, comprising 15% of all supraventricular tachycardias versus 25% in children; it is usually seen at an early age, and shows no sex-related predominance. The clinically incessant forms account for around 2% of all such tachycardias. In many cases there is no evidence of an associated structural pathology, though the clinical significance of this entity depends on this factor and on the severity of the tachycardia.^{1,2} Up to now effective treatment has been quite difficult and in some cases physicians have resorted to surgery;³ but this has changed with the advent of radiofrequency ablation.⁴

Arrhythmias often appear in central nervous system diseases, though the specific association for this type of tachycardia is unknown. We describe a patient with interrelated electrocardiographic and clinical characteristics of both diseases.

CLINICAL CASE

A 78-year-old woman with no history of heart disease or any other pathological process was seen in the outpatient clinic for a routine check-up. Cardiac arrhythmia was detected at this visit and she was referred to our center. The patient was completely asymptomatic and the physical examination was unremarkable. The only evaluable cardiologic feature was a relatively rapid and irregular pulse rate. The resting ECG demonstrated short runs of atrial rhythm, usually a few beats, originating in the high right atrium, alternating with one or two beats of sinus rhythm, and occasionally accompanied by premature supraventricular contractions of the same morphology. Heart rate was 120-140 beats/min and the findings were consistent with incessant atrial tachycardia. The PR, QRS and QTc intervals were normal. Extracardiac causes that could explain or favor the arrhythmia were ruled out and the patient denied any concomitant pharmacological treatment or toxic habits. Several subsequent studies with Holter monitoring confirmed the same cardiac rhythm abnormality, with a slight decrease in the rate and a slight increase in extrasystoles at night and during rest (Figure 1). A complete analytical study, including a repeat thyroid function test to investigate mild multinodular thyroid hyperplasia, was normal, as were the chest X-ray and echocardiogram.

Despite the absence of symptoms and given the sustained character of the arrhythmia, pharmacological treatment was attempted with several antiarrhythmic

Correspondence: Dr. J. Vilaplana Palomer, Servicio de Cardiología, Hospital Universitario Doctor Josep Trueta, Avda. de Francia, s/n, 17007 Girona, Spain
E-mail: jvilaplanap@comg.es

Received 9 January 2002.

Accepted for publication 27 November 2002.

ABBREVIATIONS

CVA: cerebrovascular accident
cAMP: cyclic adenosine monophosphate
PSVC: premature supraventricular contractions
ICP: intracranial pressure
BP: blood pressure
IAT: incessant atrial tachycardia

agents excluding amiodarone, administered sequentially and in association (class II, IB, IA, and IV), without success. There were no changes in cardiac rhythm. Invasive studies were not performed because of the patient's good clinical status and her refusal to undergo such testing.

More than one year after we first saw her, she was admitted urgently to the hospital for clinical symptoms of spatial disorientation and mental confusion of several hours' duration, which slowly remitted with some degree of amnesia. Cranial computed tomography (CT) scanning disclosed a right temporo-parieto-occipital lesion approximately 6×3 cm in size and showing a mass effect, consistent with a diagnosis of arachnoid cyst (Figure 2). The patient was evaluated by the neurosurgery service, which indicated fluid drainage by fistulizing the cyst to the pericranium, a procedure that was completed without complications. Radiologic study confirmed total resolution of the abnormal ima-

ge (Figure 3). On subsequent follow-up examinations starting a few weeks later, the runs of tachycardia were seen to gradually normalize and medical treatment was progressively tapered. At the time of writing the patient was leading a normal life and a stable sinus rhythm had been maintained.

DISCUSSION

In 1888, the English neurologist John Bristow, and in 1900, the German physician Augustus Hoffman, pointed to the nervous system as the only cause for certain tachycardias, presumably those of supraventricular origin.¹ In 1922 and 1924, Gallavardin defined two types of ectopic atrial tachycardia: "tachycardie à centre excitable" related with emotional states and "extrasistolie à paroxysmes tachycardiques" or tachycardia in short runs, a frequent condition with a significant vegetative component in apparently normal individuals.⁵ The repetitive atrial forms described by Parkinson and Papp in 1947 initially referred to the same signs.

According to its presentation on surface ECG, monomorphic atrial tachycardia is defined as an organized rhythm originating in the atria and composed of ectopic P-waves of the same shape and specific characteristics that indicate their origin and allow their differentiation from other types of supraventricular paroxysmal tachyarrhythmias.^{6,7} In the incessant clinical presentation, the runs are usually short but highly repetitive, with a degree of initial acceleration depending on the duration. Among these runs one or more si-

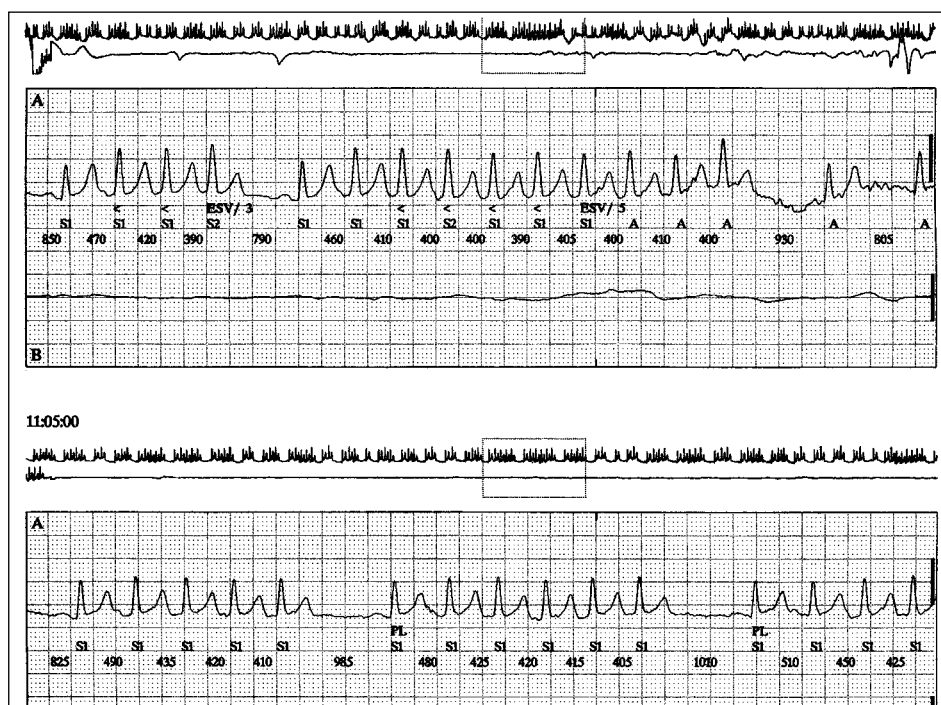


Fig. 1. Holter recording showing short runs of tachycardia.

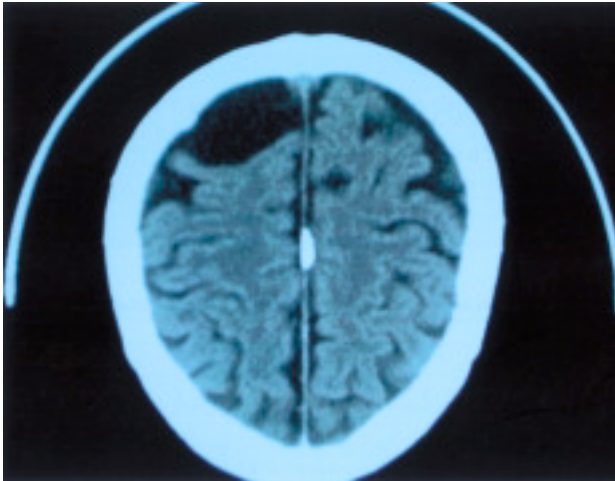


Fig. 2. Cranial CT image before the procedure.

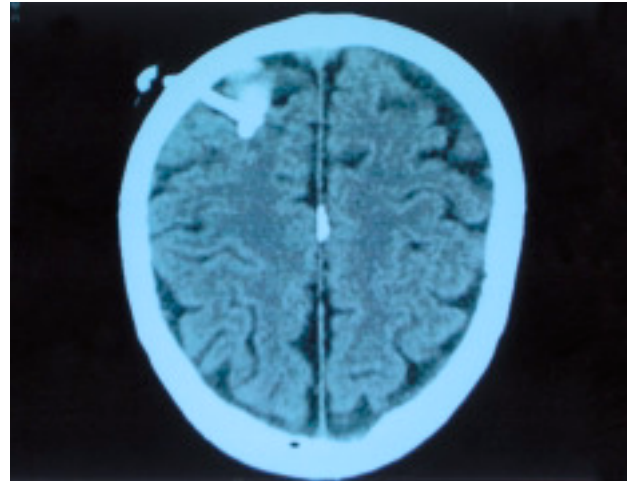


Fig. 3. Cranial CT image after drainage of the cystic tumor.

nus beats may be observed.² Much shorter runs, sometimes interspersed with ectopic beats of the same morphology, correspond more closely to the purely repetitive forms, considered incessant because of their persistence.⁸

The mechanisms involved in the so-called focal tachycardias include an increase in automaticity and the activity triggered by late potentials. Focal tachycardia sometimes shares the characteristics of both the reentrant and the automatic forms.^{1,5,9,10} The focal type is also the most frequent in adults, although the exact prevalence is unknown. The response to various electrophysiologic maneuvers and antiarrhythmic drugs are clues to their differentiation, and recently a type with different characteristics (possibly due to early potentials) and responsive to lidocaine was described.¹¹ Poor intercellular coupling has been postulated in automatic forms.¹² Observation of cardiac rhythm variability has led to the suggestion that these incessant forms are under the same influence and autonomic regulation as the sinus node. Specific histological alterations including fibrosis and myocyte alterations were demonstrated in one surgical case,³ but the preferential origin in the terminal crest and other parts of the right atrium and even the pulmonary veins suggests that the cause may lie in a simple prolongation of, or remnants of, specialized embryonic tissue or increased innervation. Augmented automaticity due to unknown causes, or a mechanism also mediated by catecholamine independent of adenosine monophosphate (C-AMP) in triggered arrhythmias, would reflect a sympathetic-parasympathetic imbalance in the ectopic foci.^{9,10}

In the central nervous system, signals from the cerebral cortex and hypothalamus can affect the activity of almost all the autonomic centers of the lower brain stem, which, among other functions, control the heart rhythm. The presence of a specific stimulus or lesion would secondarily cause a direct, reciprocal, increased

sympathetic and decreased parasympathetic relation in the ipsilateral hemisphere. Chronotropic cardiac organization has been demonstrated in the posterior insular cortex of the rat. In humans, stimulation of the right insula would increase sympathetic activity and stimulation of the left insula would decrease it.¹³ Stimulation of the posterior and lateral hypothalamus increases blood pressure and the heart rate, whereas in the anterior preoptic area of the hypothalamus, in which parasympathetic tone predominates, the opposite occurs.¹⁴ The reticular formation, which has a direct functional relationship with the posterior hypothalamus, and the corticospinal tract are responsible for transmitting the sympathetic impulses to the medulla.¹⁵

Cardiac rhythm alterations are common in neurologic diseases, because of a direct effect on the cardiac muscle or an effect induced by neurohormonal abnormalities. In acute cerebrovascular disease, the principal mechanism seems to be implicit alteration of the autonomic nervous system, with or without myocardial injury.^{16,17} Whether the discharge is sympathetic or parasympathetic depends on the site of the lesion and, when it is present, on the degree and speed of the increase in intracranial pressure. The overall vegetative response results from the balance between the secondary discharge at the site of stimulation and the increase in intracranial pressure. This alone would temporarily depress of sinus node activity and favor other foci of activity. Studies in animals have demonstrated that continuous rhythmic activity at the centers of cardiac regulation can be modified, and heart rate fluctuations have been observed with the presence of repetitive forms. Together with gradual elevations in intracranial pressure, sympathetic mediation has been associated with premature atrial contractions, short runs, and repetitive sinus and atrial patterns, among other arrhythmias.¹⁸ In these studies it has also been observed that stimulation in the mesencephalic region seems to be

the origin of the electrical changes observed in repolarization.

In ischemic cerebrovascular accidents, trauma or cerebral tumors, all types of arrhythmias have been described, with a predominance of ventricular types and atrial fibrillation; but supraventricular arrhythmias are specifically related with right brain hemisphere involvement, with premature supraventricular contractions and atrial tachycardia, although these are referred to as paroxysmic.^{17,19,20} We believe that the same mechanism was involved in our patient. We do not know whether there was a progressive increase of intracranial pressure due to the size of the tumor, but we do know that there was compression of structures from the right posterior parietal region (area of spatial localization), producing the vegetative response with an excessive, sustained sympathetic discharge.

Despite the close relation between many arrhythmias and the nervous system, physicians often consider this system only as a triggering or modulating factor in terms of functional or stress. When faced with an arrhythmia such as that occurring in the case presented here, in an adult patient and with no apparent cause, it may be necessary to systematically rule out a potential nervous system condition, particularly a central process, as the cause of the problem.

REFERENCES

1. Kastor JA. Atrial Tachycardia. Arrhythmias. Philadelphia: WB Saunders, 2000; p. 164-5.
2. Bayés de Luna A. Taquicardia auricular monomórfica. Electrocardiografía Clínica. Barcelona: Espaxs, 1999; p. 158-60.
3. Moro Serrano C, Rofilanchas J, Tamargo J, Ledesma C, Novo L, Martín Luengo C. Taquicardia automática auricular incesante; análisis electrofisiológico y anatómico de un caso operado con éxito. Rev Esp Cardiol 1986;39:344-8.
4. Vacca M, Sáenz L, Mont L, Rubin JM, Madariaga R, Brugada J. Eficacia a largo plazo de la ablación con radiofrecuencia de la taquicardia auricular. Rev Esp Cardiol 2001;54:29-36.
5. Gallavardin L. Extrasistolia auricular à paroxysmes tachycardiques prolongés. Archs Mal Coeur 1922;15:774.
6. Hernández D, Dantiago J, Collin L, Iturralde P, Guevara M, González-H J. Utilidad del electrocardiograma de superficie para el diagnóstico de las taquicardias con QRS estrecho: correlación con los registros intracavitarios. Rev Esp Cardiol 2001;54:965-72.
7. Tang C, Scheinman M, Van Hare G, Epstein L, Fitzpatrick A, Randall J, et al. Use of P wave configuration during atrial tachycardia to predict site of origin. J Am Coll Cardiol 1995;26:1315-24.
8. Vilardell M, Canal V, Fontarnau J, Martínez de Arenzana S, Bayés Genis A. Salvas de Gallavardin. Taquicardia paroxística repetitiva. Rev Lat Cardiol 1999;20:25-6.
9. Stein KM, Suneet M, Slotwiler DJ, Markowitz SM, Iwai S, Lerman BL. Atrial tachycardia: Update. Cardiac Electrophysiol Rev 2001;5:290-3.
10. Chen SA, Chiang CE, Yang CJ, Cheng CC, Wu TJ, Wang SP, et al. Sustained atrial tachycardia in adults patients. Circulation 1994;90:1262-78.
11. Chiale P, Franco A, Sela H, Militello C, Elizari M. Lidocaine-sensitive atrial tachycardia. J Am Coll Cardiol 2000;36:1637-45.
12. Lesh MD, Kalman JM, Saxon LA, Dorostkar PC. The role of atrial anatomy in clinical atrial arrhythmias. J Electrocardiol 1996;29(Suppl):101-13.
13. Oppenheimer S. The anatomy and physiology of cortical mechanisms of cardiac control. Stroke 1993;24(Suppl):13-5.
14. Guyton A. Sistema nervioso. Control vegetativo del hipotálamo. Tratado de Fisiología Médica: McGraw-Hill, 1992; p. 863-4.
15. Houshang J, Attar J, Gutierrez M, Bellet S, Ravens JR. Effects of stimulation of Hypothalamus and reticular activating system on production of cardiac arrhythmias. Circ Res 1963;12:14-21.
16. Zipes P, Jalife J. Arrhythmias in patients with neurological disorders. Cardiac electrophysiology: From cell to bedside. Philadelphia: WB Saunders, 2000; p. 592.
17. Mikolich R, Jacobs C, Fletcher F. Cardiac arrhythmias in patients with acute cerebrovascular accidents. JAMA 1981;246:1314-7.
18. Smith M, Ray CT. Cardiac arrhythmias, increased intracranial pressure, and the autonomic nervous system. Chest 1972;61:125-33.
19. Lane RD, Wallace JD, Petrosky PP, Schwartz GE, Gradman AH. Supraventricular tachycardia in patients with right hemisphere strokes. Stroke 1992;23:362-6.
20. Serrano-Castro V, Gil-Peralata A, González-Marcos JR, Moreno-Rojas A, Pedrote A, Errazquin P. Cardiac disease in intracerebral hematomas. Rev Neurol 1998;26:800-3.