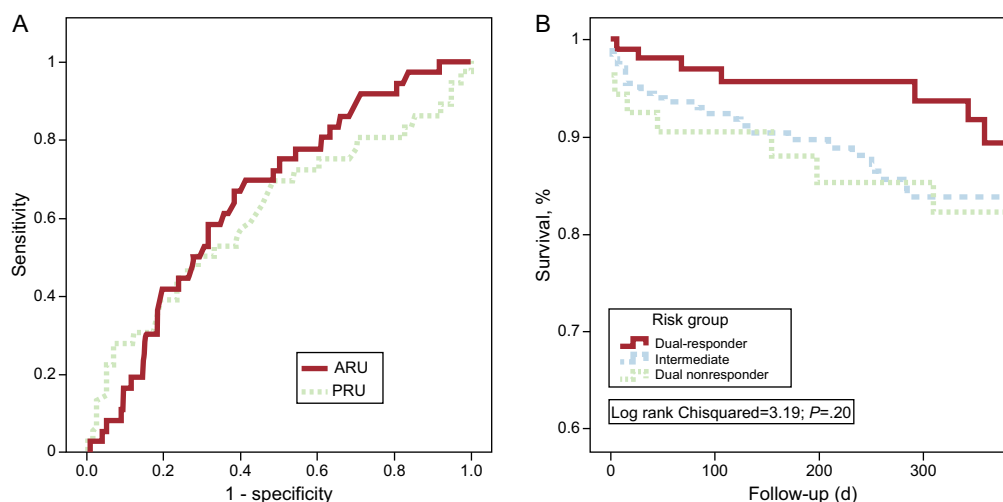

**Figure.** A: ROC (receiver operating characteristic) curve for ARU (resistance to acetylsalicylic acid) and PRU (resistance to adenosine diphosphate receptor blockers) and the combined variable. B: Kaplan-Meier curve for response to antiplatelet agents.

general efficacy than that of PRU. Further larger-scale studies are needed to confirm these findings.

## FUNDING

The present study was financed through FFIS-Caja Murcia grant 10/006.

Luciano Consuegra-Sánchez,<sup>a,\*</sup> Derek Dau,<sup>a</sup> Leticia Jaulent,<sup>a</sup> Daniel Fernández-Bergés,<sup>b</sup> Francisco Picó,<sup>a</sup> and Manuel Villegas<sup>a</sup>

<sup>a</sup>Servicio de Cardiología, Hospital General Universitario de Santa Lucía, Cartagena, Murcia, Spain

<sup>b</sup>Sección de Cardiología, Departamento de Medicina Interna, Hospital Don Benito-Villanueva, Don Benito, Badajoz, Spain

\* Corresponding author:

E-mail address: lconsue@gmail.com (L. Consuegra-Sánchez).

Available online 23 November 2012

## REFERENCES

1. Angiolillo DJ, Ferreiro JL. Inhibición del receptor plaquetario P2Y<sub>12</sub> de adenosina difosfato plaquetario: efectos beneficiosos y limitaciones de las estrategias terapéuticas actuales y perspectivas futuras. *Rev Esp Cardiol.* 2010;63:60–76.
2. Krasopoulos G, Brister SJ, Beattie WS, Buchanan MR. Aspirin «resistance» and risk of cardiovascular morbidity: systematic review and meta-analysis. *BMJ.* 2008;336:195–8.
3. Vivas D, Bernardo E, García-Rubira JC, Azcona L, Núñez-Gil I, González-Ferrer JJ, et al. Can resistance to aspirin be reversed after an additional dose? *J Thromb Thrombolysis.* 2011;32:356–61.
4. Price MJ, Puri S, Robbins M, Teirstein P, Garratt K, Bertrand O, et al. Standard vs high-dose clopidogrel based on platelet function testing after percutaneous coronary intervention: The GRAVITAS randomized trial. *JAMA.* 2011;305:1097–105.
5. Trenk D, Stone GW, Gawaz M, Kastrati A, Angiolillo DJ, Muller U, et al. A randomized trial of Prasugrel versus Clopidogrel in patients with high platelet reactivity on Clopidogrel after elective percutaneous coronary intervention with implantation of Drug-Eluting Stents: Results of the TRIGGER-PCI (Testing platelet reactivity in patients undergoing elective stent placement on clopidogrel to guide alternative therapy with prasugrel) Study. *J Am Coll Cardiol.* 2012;59:2159–64.
6. Bonello L, Tantry US, Marcucci R, Blindt R, Angiolillo DJ, Becker R, et al. Consensus and future directions on the definition of high on-treatment platelet reactivity to adenosine diphosphate. *J Am Coll Cardiol.* 2010;56:919–33.

<http://dx.doi.org/10.1016/j.rec.2012.08.009>

## Infected Ascending Aorta Prostheses. Is Prosthesis Removal Always Necessary? How Long Should Antibiotics Be Given?

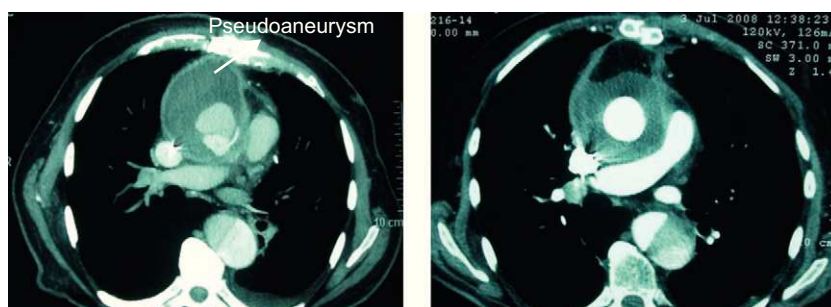
**Infección de prótesis de aorta ascendente. ¿Es necesario retirar la prótesis siempre? ¿Cuánto tiempo con tratamiento antibiótico?**

### To the Editor,

We report two cases of infected ascending aorta prostheses, evaluate the treatment received, and review the related literature.

The first case is a 77-year-old man, smoker, with a history of hypertension and gastric ulcer. Seven months after surgery for a type A aortic dissection, with replacement of the supracoronary ascending aorta by a Dacron prosthesis, the patient presented purulent drainage through the sternotomy. Computed tomography study showed an aortic pseudoaneurysm that had fistulized to the skin through the sternum (Fig. 1). The patient was reoperated through a median sternotomy with extracorporeal circulation via

the femoral vessels. Following vent placement through a left minithoracotomy, deep hypothermia and circulatory arrest were established, the purulent material was cleaned, and an anastomotic dehiscence was repaired, while retaining the original Dacron prosthesis. The prosthesis and retrosternal space were then covered with abdominal omentum (omentoplasty). Blood cultures were negative, and culture of the fistula drainage and periprosthetic and pseudoaneurysm material yielded *Staphylococcus epidermidis*. The patient initially received 6 weeks of intravenous treatment with vancomycin, rifampicin, and gentamicin, then oral linezolid and rifampicin for 4 weeks. Owing to hematologic toxicity, linezolid was discontinued and treatment was changed to trimethoprim-sulfamethoxazole, and rifampicin for 26 weeks. Antibiotic therapy was then stopped, and there was no clinical, analytic, microbiologic, or radiologic (computed tomography and technetium-labeled autologous leukocytes) (Fig. 1) evidence of infectious activity. After 36 months of follow-up, there was no evidence of relapse.



**Figure 1.** Case 1. Before and after surgical repair.

The second case is a 57-year-old man with no previous illnesses, and prolonged fever. Nineteen months before consulting, the patient had undergone surgery to treat an aneurysm of the ascending aorta and aortic insufficiency, involving implantation of a CarboSeal 27 valved Dacron tube graft, with reimplantation of the coronary ostia. Chest computed tomography disclosed a large pseudoaneurysm of the ascending aorta (Fig. 2). Prosthesis replacement was not considered a viable option because of the technical complexity of the procedure and the high surgical risk. The patient was reoperated through a median sternotomy, with extracorporeal circulation via the femoral vessels. Deep hypothermic circulatory arrest was established. Multiple thrombi were removed from the pseudoaneurysm and an anastomotic dehiscence was repaired, while retaining the previously implanted valved tube graft. Omentoplasty was carried out to cover the original prosthesis. Blood cultures were negative, and *S. epidermidis* was isolated on culture of the periprosthetic and aneurysm material. The patient was treated with intravenous vancomycin and gentamicin during 6 weeks, and with linezolid for an additional 18 weeks. At that time, linezolid was discontinued due to hemotoxicity, and according to the antibiogram, no alternative oral antibiotic option was available. Nonetheless, the patient showed no clinical, analytic, microbiologic, or radiologic signs of infectious activity (Fig. 2), and treatment was stopped. After 36 months of follow-up, there was no evidence of a relapse.

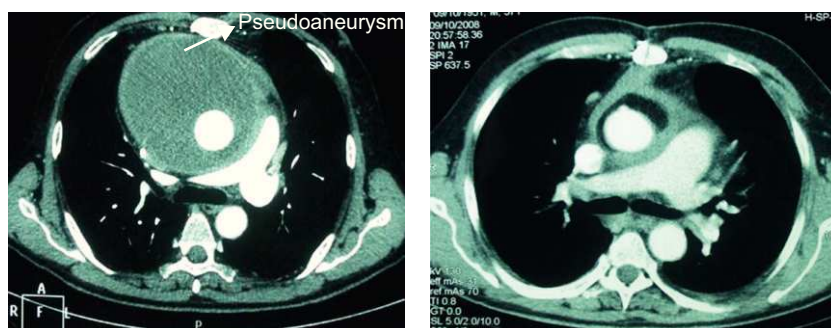
Two cases of infected ascending aorta prostheses are presented. In both patients, echocardiographic study soon after prosthesis implantation showed an absence of pseudoaneurysms, thus indicating that the mechanism for pseudoaneurysm formation was an infectious process. The patients' clinical course was favorable following local surgical debridement and repair, retention of the original prosthesis and covering with omentum, and prolonged antibiotic therapy.

Infection of the ascending aorta prosthesis is an uncommon (0.9%-2%) but serious condition, with an associated mortality rate

higher than 40%.<sup>1</sup> The recommended treatment is replacement of the infected prosthesis together with antibiotic therapy, but sometimes, graft replacement is not feasible. There are reported cases in which the infected prosthesis has been retained with therapeutic success; the most widely accepted technique for this purpose is local surgical debridement and repair, supported by omentoplasty.<sup>2,3</sup> This option, which should be considered a last resort, is useful when prosthesis replacement is technically impossible or when infection occurs in patients of advanced age or those with severe comorbidities.<sup>4</sup> In these cases, retaining the graft originates a high risk of recurrent infection. Therefore, the area should be cleaned and infected necrotic tissue debrided, the anterior mediastinum should be irrigated with antiseptic solutions, and omentum or muscle flap transposition should be carried out to create a barrier and close dead space to control the infection.<sup>2</sup> The use of omentoplasty provides the vascularity, easy transposition, and considerable filling potential of the omentum.

There is no consensus as to the optimal antibiotic treatment for infected ascending aorta prostheses or duration of this therapy. In empirical regimens, coverage against methicillin-resistant *Staphylococcus aureus* and coagulase-negative staphylococci is mandatory, since *Staphylococcus* spp. are the most common microorganisms isolated.<sup>5</sup> Some authors recommend intravenous antibiotic therapy followed by suppressive oral antibiotics for life.<sup>4</sup> Our patients received antibiotic therapy of limited duration and have shown no signs of recurrent infection after 3 years of follow-up; hence, we consider that the therapy was adequate. Although the optimum treatment duration remains uncertain, it would be reasonable to administer 4 to 6 weeks of intravenous therapy followed by oral suppressive therapy during at least 24 weeks. Treatment withdrawal can then be evaluated, providing there are no signs of recurrent infection.

There is no definitive evidence regarding treatment for infected ascending aorta prostheses. In the two patients presented, maintaining the prosthesis using the strategy described, followed



**Figure 2.** Case 2. Before and after surgical repair.

by adequate prolonged antibiotic therapy and close follow-up, proved to be an effective approach.

Radka Ivanova-Georgieva,<sup>a,\*</sup> Gemma Sánchez,<sup>b</sup> Rocío Arnedo,<sup>a</sup> Josefa Ruiz-Morales,<sup>a</sup> María José Mataró,<sup>b</sup> and José María Melero<sup>b</sup>

<sup>a</sup>Unidad de Gestión Clínica de Enfermedades Infecciosas, Hospital Clínico Virgen de la Victoria, Málaga, Spain

<sup>b</sup>Unidad de Gestión Clínica de Cirugía Cardíaca, Hospital Clínico Virgen de la Victoria, Málaga, Spain

\* Corresponding author:

E-mail address: [dradabg@yahoo.com](mailto:dradabg@yahoo.com) (R. Ivanova-Georgieva).

Available online 11 November 2012

## REFERENCES

1. Coselli J, Koksoy C, LeMaire SA. Management of thoracic aortic graft infections. *Ann Thorac Surg.* 1999;67:1990–3.
2. Samoukovic G, Pierre-Luc B, Lachapelle K. Successful treatment of infected ascending aortic prosthesis by omental wrapping without graft removal. *Ann Thorac Surg.* 2008;86:287–9.
3. Akowuah E, Narayan P, Angelini G, Bryan AJ. Management of prosthetic graft infection after surgery of the thoracic aorta: removal of the prosthetic graft is not necessary. *J Thorac Cardiovasc Surg.* 2007;134:1051–2.
4. LeMaire S, Coselli J. Option of managing infected aortic grafts. *J Thorac Cardiovasc Surg.* 2007;134:839–43.
5. Fitzgerald SF, Kelly C, Humphreys H. Diagnosis and treatment of prosthetic aortic graft infections: confusion and inconsistency in the absence of evidence or consensus. *J Antimicrob Chemother.* 2005;56:996–9.

<http://dx.doi.org/10.1016/j.rec.2012.08.004>

## Simplified Approach for Ablation of Nodal Reentrant Tachycardia in a Patient With Tricuspid Atresia and Extracardiac Fontan Palliation

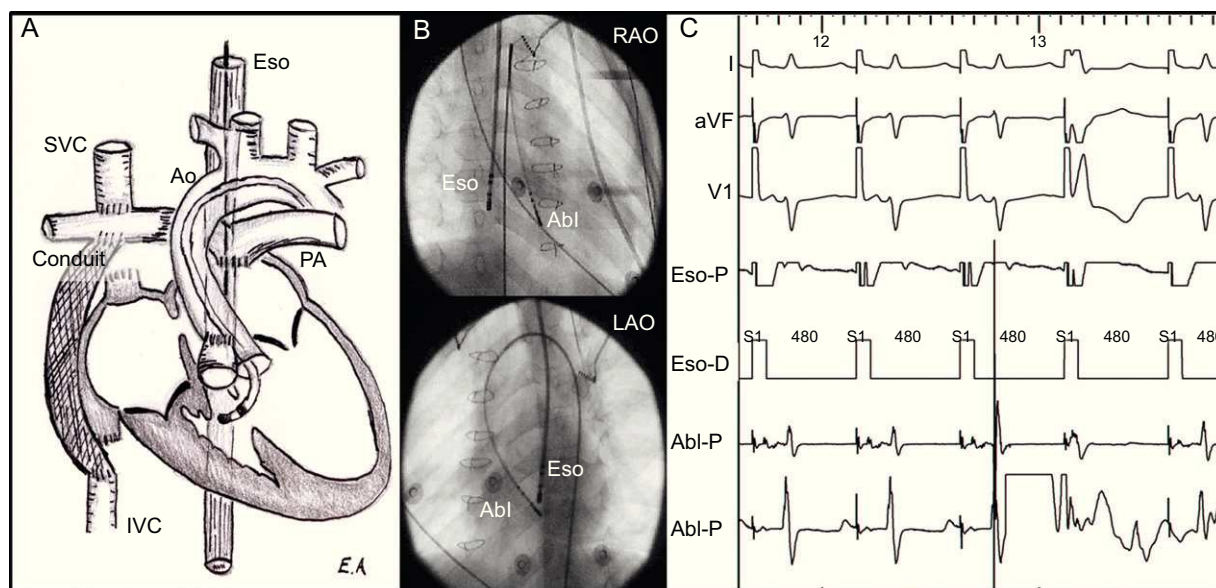
*Abordaje simplificado para la ablación de la taquicardia por reentrada intranodal en paciente con atresia tricuspídea y Fontan extracardiaco*

To the Editor,

Fontan palliation was first described for the treatment of tricuspid atresia, but the indications have since been extended to other complex congenital defects such as univentricular hearts.<sup>1</sup> Since the original atriopulmonary connection procedure—which was associated with a high incidence of atrial arrhythmias, among other disadvantages—the technique has been improved and extracardiac cavopulmonary connection is currently used.<sup>1</sup> This approach is simple, the hemodynamic outcomes are excellent, and the percentage of arrhythmias during follow-up is low.<sup>2</sup> However, atrial arrhythmias are not completely eliminated and the venous

access routes to the heart are lacking, making percutaneous techniques much more difficult to carry out.

We report the case of a 4-year-old boy weighing 19.5 kg, who had a univentricular heart due to tricuspid atresia. The position of the great vessels was normal, and there was an obstructive bulboventricular foramen. He had undergone a bidirectional Glenn procedure and ligation of the pulmonary artery when aged 2 years. Subsequently, extracardiac Fontan palliation was performed. Three months after the last intervention, he started to experience episodes of supraventricular tachycardia, with poor hemodynamic tolerance, which required repeated admission to the emergency room. The episodes remitted with intravenous adenosine. Despite treatment with sotalolol, the crises became more frequent. An electrophysiological study was therefore ordered and was performed under general anesthetic. Given that there was no venous connection with the cardiac chambers, a 5-mm ablation catheter was introduced by a retroaortic approach (Therapy<sup>®</sup>, St. Jude Medical) into the left ventricle. Another 7-mm catheter (Celsius<sup>®</sup>, Biosense-Webster) was introduced through the esophagus to record atrial activity (Figs. 1A and B). The conduction



**Figure 1.** A: Anatomical schematic. B: Position of the ablation catheters. C: Electrogram at the application point. Abl, ablation catheter; Ao, aorta; Eso, esophagus; IVC, inferior vena cava; LAO, left anterior oblique; PA, pulmonary artery; RAO, right anterior oblique; SVC, superior vena cava.