

Scientific letters

NEW MODELS OF PERCUTANEOUS AORTIC VALVE PROSTHESIS

Initial Experience With the Low-profile Percutaneous Aortic Valve SAPIEN 3

*Experiencia inicial con la válvula aórtica percutánea de muy bajo perfil SAPIEN 3*

To the Editor,

Transfemoral transcatheter aortic valve implantation (TAVI) is an established therapy for patients with severe inoperable aortic stenosis or high surgical risk.

Since the first TAVI implantation in humans in 2002,¹ various models of this prosthesis have been developed, with progressive technical improvements and a reduction in the profile of the delivery system. One of the latest generations of this type of valve is the Edwards-SAPIEN 3 (Edwards Lifesciences; Irvine, California, United States), a prosthesis designed for easy placement within the valve plane and an improved outcome of the intervention.

This valve system has been designed with 14-F (for 23 and 26 mm valves) and 16-F (29 mm valves) delivery systems, due to the simplified structure of the chrome-cobalt mesh, the reduced thickness of the struts and the improved folding system, while maintaining the radial strength and circularity of the stent. It also incorporates an inner and outer polyethylene terephthalate skirt designed to minimize residual perivalvular leaks. The delivery system has a double joint, which improves control over the positioning of the valve with a central radiopaque marker in the ball; this marker facilitates alignment within the valve plane.

In this article, we describe our initial experience of transfemoral TAVI using the Edwards-SAPIEN 3 prosthesis, analyzing the first 5 interventions carried out in Spain by the same operator in 2 centers.

Clinical characteristics and procedures are described in the Table. In all patients, a guidewire was advanced from the contralateral femoral at the beginning of the procedure, according to a previously described technique.² The Prostar XL (Abbott Vascular, Santa Clara, California, United States) percutaneous closure system was used. Valvuloplasty was performed in 2 patients (at the manufacturer's request in 1, because it was the first time this procedure had been performed in Spain) and direct implantation in the remaining 3, following a previously described protocol.^{3–5} The procedure was successfully completed in all patients without significant residual periprosthetic aortic

insufficiency, and with a good immediate hemodynamic response. In 1 patient, a coated Advanta (Grifolds) stent was implanted due to incomplete closure of the arteriotomy in the right common femoral artery. In 4 of these 5 patients (1, 2, 3, and 4), we would have had great difficulty in guaranteeing the success of the intervention using the previous prosthesis model, given the vascular access. In another patient, pericardiocentesis was performed due to perforation by the pacemaker lead. In a final patient, severe damage to the proximal circumflex (not detected in the initial coronary angiography) was identified by post-implantation aortographic inspection, and we decided to perform immediate angioplasty with stenting, catheterizing the common trunk via the valve structure.

The mean hospital stay was 5.4 (SD, 3.6) (range, 3–12) days. No patient required pacemaker implantation following the procedure. Thirty-day mortality was zero and all patients remained in functional class I. Figures A–C show angiographic images of the various sizes of prostheses implanted.

Implantation of the Edwards SAPIEN 3 is simpler than with previous Edwards models, although we note some practical considerations. The valve should be placed in a slightly deeper position in the outflow tract of the left ventricle than previous prostheses because the lower half is shortened during the final phase of inflation due to the design of the cells (Figure). Moreover, the structure of the prosthesis is longer, so it is advisable to make a proper assessment of the distance between the valve plane and the left coronary ostium.

This new prosthesis also has additional advantages over previous valves: the reduced diameter of the delivery system extends the range of patients who can undergo the transfemoral approach; moreover, the lower profile of the prosthesis favors direct implantation in most patients. Another of its most attractive features is the reduced residual periprosthetic aortic insufficiency, given the widely recognized relationship between this parameter and patient mortality during follow-up.⁶ Although some incidents occurred during the procedure and had to be resolved, it should be stressed that these were very high-risk patients with an average EuroSCORE I of >40 (42.5%), and who maintained an excellent clinical status after 30 days.

In conclusion, the SAPIEN 3 percutaneous aortic valve is an important advance in a new generation of valves that will broaden the spectrum of candidate patients for this therapeutic strategy, and is progressively establishing itself as a clear alternative to surgical valve replacement.

Table

Description of Patients and Procedure for Transfemoral Implantation of the Edwards-SAPIEN 3 Aortic Prosthesis

	Age, years	Sex	CD	EuroSCORE, %	LVEF, %	Valve area	Gradient (GP máx.)	Basal AI	Valvular calcification	Ring size	Valve size	Direct implantation	Residual AI	Incidents
1	94	M	No	61.3	65	0.5	106	2	4	19	23	No	1	Advanta stent AFD
2	80	M	Yes	16.5	65	0.7	71	1	2	25	29	Yes	0	Pericardiocentesis
3	86	F	No	55	25	0.8	90	0	4	20	23	No	0	No
4	91	F	Yes	63.1	25	0.9	47	2	3	19	23	Yes	0	No
5	80	M	No	16.5	65	0.4	80	2	4	22	26	Yes	0	No

CD, coronary disease; LVEF, left ventricular ejection fraction; AI, aortic insufficiency; F, female; M, male.

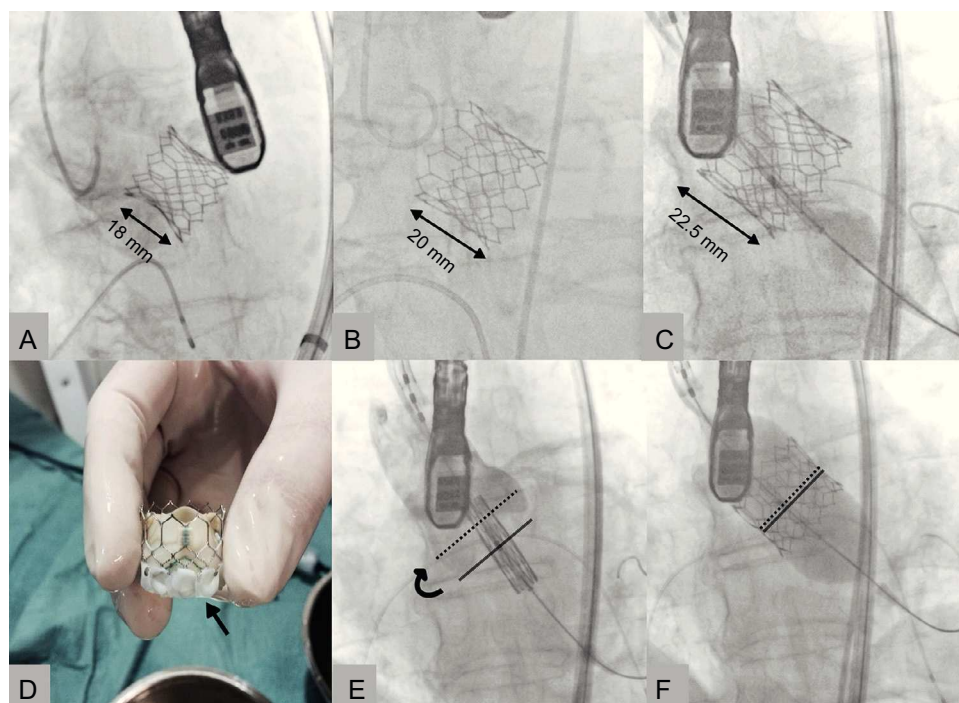


Figure. Edwards-SAPIEN 3 prostheses implanted, 23 (A), 26 (B) and 29 mm (C). Placement of the valve at the level of the ring (E) with elevation of the valve after inflation of the balloon (F). The solid line indicates the central zone of the prosthesis, marked by the radiopaque line of the balloon. The dotted line indicates the ideal final position that this marker should reach. Image of a 23 mm prosthesis before implantation, with polyethylene terephthalate outer skirt (D, arrow).

Eulogio García,^{a,b,*} Leire Unzué,^a Eduardo García,^b Jorge Solís,^a Rodrigo Teijeiro,^b and Belén Tarancón^b

^aServicio de Cardiología, Hospital Universitario Madrid-Montepíncipe, Boadilla del Monte, Madrid, Spain

^bServicio de Cardiología, Hospital Moncloa, Madrid, Spain

* Corresponding author:

E-mail address: ejgarcia1@telefonica.net (E. García).

Available online 27 September 2014

REFERENCES

1. Cribier A, Eltchaninoff H, Bash A, Borenstein N, Tron C, Bauer F, et al. Percutaneous transcatheter implantation of an aortic valve prosthesis for calcific aortic stenosis: first human case description. *Circulation*. 2002;106:3006–8.

2. García E, Almería C, Unzué L, Jiménez P, Cuadrado A, Macaya C. Transfemoral implantation of Edwards Sapien XT aortic valve without previous valvuloplasty: Role of 2D/3D transeophageal echocardiography. *Catheter Cardiovasc Interv*. 2014 Feb 21. <http://dx.doi.org/10.1002/ccd.25417> [Epub ahead of print].
3. García E, Martín-Hernández P, Unzué L, Hernández-Antolín RA, Almería C, Cuadrado A. Utilidad de colocar una guía desde la femoral contralateral para facilitar el tratamiento percutáneo de complicaciones vasculares en los TAVI. *Rev Esp Cardiol*. 2014;67:410–2.
4. García E, Hernández-Antolín R, Martín P, Rodríguez JC, Almería C, Cuadrado AM. Implantación de prótesis aórtica Edwards-SAPIEN XT transfemoral sin valvuloplastia previa. *Rev Esp Cardiol*. 2013;66:150–1.
5. García E, Martín P, Hernández P, Rodríguez V, Fernández A, Gama V, et al. Feasibility and safety of transfemoral implantation of Edwards-SAPIEN XT prosthesis without balloon valvuloplasty in severe stenosis of native aortic valve. *Cardiovasc Interv*. 2014;83:791–5.
6. Zahn R, Gerckens U, Linke A, Sievert H, Kahlert P, Hambrecht R, et al. Predictors of one-year mortality after transcatheter aortic valve implantation for severe symptomatic aortic stenosis. *Am J Cardiol*. 2013;112:272–9.

SEE RELATED ARTICLE:

<http://dx.doi.org/10.1016/j.rec.2014.07.004>, *Rev Esp Cardiol*. 2014;67:878–80.

<http://dx.doi.org/10.1016/j.rec.2014.04.014>

NEW MODELS OF PERCUTANEOUS AORTIC VALVE PROSTHESIS

Initial Experience With the DirectFlow Percutaneous Aortic Valve in Spain



Experiencia inicial en España con la prótesis aórtica percutánea DirectFlow

To the Editor,

Percutaneous implantation of an aortic prosthesis in patients with severe aortic stenosis and high surgical risk has been proven to be more effective than medical treatment¹ and similar or superior² to conventional surgery according to the experience

gained with the Edwards-SAPIEN (Edwards Lifesciences; Irvine, California, United States) and Medtronic CoreValve (Medtronic; Minneapolis, Minnesota, United States) prostheses in clinical trials^{1,2} and clinical practice registers.³

The DirectFlow^{4,5} prosthesis (DirectFlow Medical; Santa Rosa, California, United States) has recently been marketed; its potential advantages over existing devices are the possibility of repositioning/recapturing the device, hemodynamic stability during the procedure, and a low rate of significant aortic failure.

The DirectFlow prosthesis (Figure) does not have any metal components and its structure is a system of communicating vessels, which when filled with liquid, make 2 rings (fluid entry via