

Image in cardiology

Intra-atrial Right Coronary Artery: An Unknown Disorder

Arteria coronaria derecha intraauricular: una entidad por conocer

Belén Díaz Antón,* Ana Fidalgo Argüelles, and Leticia Fernández Frieria

Unidad de Imagen Cardíaca, Departamento de Cardiología, Hospital Universitario HM Montepíncipe-CIEC, Boadilla del Monte, Madrid, Spain

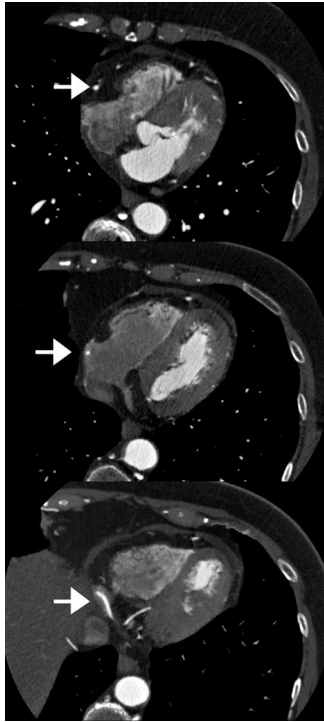


Figure 1.

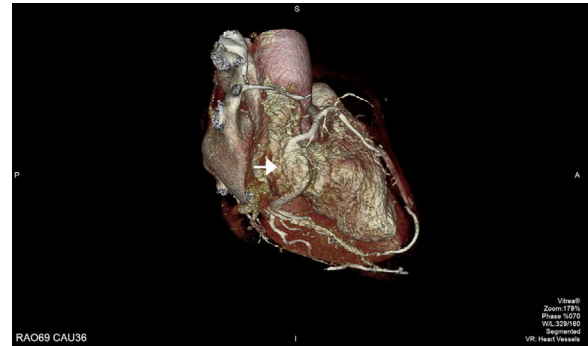


Figure 2.

We present the case of a patient with a coronary anomaly incidentally diagnosed by noninvasive coronary angiography performed to investigate atypical chest pain.

After the right coronary artery passed the acute angle of the heart, it was seen to enter the right atrium, continue an intra-atrial path for 1.5 cm, and thereafter, return to a subepicardial position and follow its usual course (Figures 1 and 2; arrows indicate the course of the right coronary artery). A follow-up single-photon emission computed tomography scan ruled out myocardial ischemia.

This coronary artery anomaly, of an apparently benign nature and asymptomatic, has only been described to date in small autopsy and surgery series. Its prevalence and origin are unknown. It is believed that anomalies of this type, following an intra-atrial course, would pose technical problems for performing the anastomosis in aortocoronary bypass surgery. In addition, there is a possibility that the arterial segment located within the atrium could be inadvertently injured in the procedure, during cannulation of the inferior vena cava or coronary sinus.

The clinical significance and prognosis of this coronary anomaly is uncertain, and additional reported cases will be needed to better understand it. To this end, computed tomography is the ideal noninvasive imaging technique to precisely identify this condition. In patients about to undergo cardiac surgery, knowledge of this anomaly will help to minimize potential risks and complications during the intervention.

* Corresponding author:
E-mail address: b.diazanton@gmail.com (B. Díaz Antón).
Available online 14 October 2017