

## Intracoronary Stem Cell Transplantation in Acute Myocardial Infarction

Francisco F. Avilés,<sup>a</sup> José A. San Román,<sup>a</sup> Javier García Frade,<sup>b</sup> Mariano Valdés,<sup>c</sup> Ana Sánchez,<sup>d</sup> Luis de la Fuente,<sup>a</sup> María J. Peñarrubia,<sup>b</sup> María E. Fernández,<sup>d</sup> Paula Tejedor,<sup>a</sup> Juan M. Durán,<sup>a</sup> Carolina Hernández,<sup>a</sup> Ricardo Sanz,<sup>a</sup> and Javier García Sancho<sup>d</sup>

<sup>a</sup>Instituto de Ciencias del Corazón (ICICOR), Hospital Clínico Universitario, Valladolid, Spain.

<sup>b</sup>Servicio de Hematología, Hospital Universitario Río Hortega, Valladolid, Spain.

<sup>c</sup>Servicio de Cardiología, Hospital Virgen de la Arrixaca, Murcia, Spain.

<sup>d</sup>Instituto de Biología y Genética Molecular, Facultad de Medicina, Universidad de Valladolid, Valladolid, Spain.

**Introduction and objectives.** Experimental and clinical studies suggest that necrotic myocardium may have the capacity to regenerate. We have started a clinical study to demonstrate that the intracoronary implantation of stem cells is feasible and safe. The results in our first 5 patients are presented here.

**Patients and method.** We included patients with anterior acute myocardial infarction and isolated stenosis of the left anterior descending artery that was successfully repaired by primary or facilitated angioplasty. Patients received an intracoronary infusion of bone marrow-derived cells 10-15 days after the infarction. The follow-up protocol included low-dose dobutamine echocardiography, magnetic resonance studies and ECG Holter monitoring.

**Results.** The procedure was carried out with no complications. No patient had a cardiac event during the first 6 months. One patient had a transient ischemic attack without sequelae. No arrhythmias were found. Left ventricular end-diastolic volume remained the same at 6 months (159 [25] ml, 157 [16] ml), left ventricular end-systolic volume decreased (77 [22] ml, 65 [16] ml), and the ejection fraction increased (53 [7]%, 58 [8]%) although no statistically significant differences were found. In the 3 patients in whom dobutamine echocardiography ruled out viability, we found a significant reduction in both volumes.

**Conclusions.** Intracoronary bone marrow-derived cell transplantation after an acute myocardial infarction seems to be safe and feasible, and might lead to favorable remodeling.

**Key words:** Stem cells. Acute myocardial infarction. Remodeling.

Full English text available at: [www.revespcardiol.org](http://www.revespcardiol.org)

SEE EDITORIAL ON PAGES 191-3

Correspondence: Dr. F.F. Avilés.  
Instituto de Ciencias del Corazón (ICICOR). Hospital Clínico Universitario.  
Ramón y Cajal, 3. 47005 Valladolid. España.  
E-mail: faviles@secardiologia.es

Received 29 August, 2003.

Accepted for publication 4 December, 2003.

## Regeneración miocárdica mediante la implantación intracoronaria de células madre en el infarto agudo de miocardio

**Introducción y objetivos.** Trabajos experimentales y clínicos sugieren que el tejido necrótico tiene la capacidad de regenerarse. Nuestro grupo ha comenzado un estudio clínico para demostrar que la implantación intracoronaria de células madre es un procedimiento factible y seguro. Presentamos los resultados de nuestros primeros 5 pacientes.

**Pacientes y método.** Se ha incluido a pacientes con un infarto agudo de miocardio anterior y una lesión única en la descendente anterior reparada mediante angioplastia primaria o facilitada. A los 10-15 días del infarto, se procedió a la extracción de médula ósea. El implante celular se hizo por vía intracoronaria. El protocolo de seguimiento incluye ecocardiografía con dobutamina, resonancia magnética y Holter de ECG basal y a los 6 meses.

**Resultados.** Ningún paciente ha tenido un evento cardíaco tras 6 meses de seguimiento. En un paciente se observó un accidente isquémico transitorio sin secuelas. No se han demostrado arritmias en ninguno de los pacientes. El volumen telediastólico no varió a los 6 meses (159 ± 25 y 157 ± 16 ml), el volumen telesistólico disminuyó (77 ± 22 y 65 ± 16 ml) y la fracción de eyección aumentó (53 ± 7 y 58 ± 8%), aunque no hubo diferencias significativas. En los 3 pacientes en los que la ecocardiografía con dobutamina descartó viabilidad, sí hubo una disminución significativa de los volúmenes.

**Conclusiones.** El implante intracoronario de células madre en pacientes que han tenido un infarto agudo de miocardio parece un método seguro y factible, y podría dar lugar a un remodelado favorable.

**Palabras clave:** Células madre. Infarto agudo de miocardio. Remodelado.

## INTRODUCTION

Prognosis for patients with myocardial infarction has improved spectacularly in the last 30 years thanks to the success of strategies that limit necrosis, increase electrical stability of the myocardium and improve ventricular ejection.<sup>1</sup> However, the proportion of patients with myocardial infarction who achieve optimal arterial revascularization and an adequate tissue reperfusion is still very low because treatment is sometimes contraindicated, not always effective, and practical problems may arise.<sup>2,3</sup> Thus ventricular dysfunction due to post-infarction remodeling is still the main cause of heart failure and the main reason why heart failure remains so prevalent.<sup>4</sup>

Understandably therefore, research into acute myocardial infarction focuses both on improving the applicability and efficacy of reperfusion strategies. The search for therapies that increase resistance of the myocardium to severe ischemia or that allow regeneration of damaged myocardium is also important.

Although it is not clear whether implantation of bone-marrow-derived stem cells into the infarcted region is the next step towards reduction of myocardial remodeling and mortality in patients with myocardial infarction, recent results seem promising. It seems possible that the adult heart has the capacity to regenerate and experimental findings based on this approach seem sufficiently promising to justify the development of rigorous clinical studies to further investigate the feasibility and efficacy of such treatment. Not so long ago, it was assumed that mammalian hearts were so differentiated that regeneration was not possible. Recent results, however, suggest that the adult myocardium has a certain capacity for regeneration apparently due to the action of extracardiac stem cells, possibly derived from bone marrow. There is also evidence that the capacity of cardiac regeneration could be stimulated by hematopoietic cells. In an experiment in rats, bone-marrow-derived stem cells colonized necrotic tissue and proliferated strongly after direct injection into the infarcted region or mobilization by administration of stimulation factors, leading to regeneration of the different structures that comprise the cardiac syncytium.<sup>5</sup> Studies suggest that this is also possible in humans.<sup>6</sup> The findings of Quaini et al in a study of the hearts of 8 women that had been transplanted into men seem conclusive.<sup>7</sup> Up to 10% of the myocytes and vascular endothelium cells had Y chromosomes and were proliferative.

We started a clinical study a year ago to assess the feasibility and safety of implantation of bone-marrow-derived stem cells in the infarcted region in the first few days after acute myocardial infarction. This paper presents the results for the first 5 patients.

## PATIENTS AND METHOD

### Inclusion Criteria

The study was performed in the Instituto de Ciencias del Corazón (ICICOR) of the Hospital Clínico Universitario de Valladolid and in the Servicio de Cardiología of the Hospital Virgen de la Arrixaca de Murcia. The study included patients who suffered their first anterior acute myocardial infarction and who underwent fibrinolysis and stent angioplasty within 24 hours (known as facilitated angioplasty) or primary angioplasty. In addition, patients had to have a single lesion of the left anterior descending artery with satisfactory arterial repair (TIMI 3 flow and residual stenosis less than 30%) and a well-defined region of infarct-related asynergy. Exclusion criteria were: age less than 18 years or greater than 75 years and women of a fertile age; cardiogenic shock; suspicion or evidence of mechanical complication; those with implantable defibrillators or candidates for such a device; history of cancer in the last 5 years; and any disease that may have affected survival during follow-up. After explaining the details of the protocol, the patient signed the informed consent. The protocol was approved by the ethics committees of both centers.

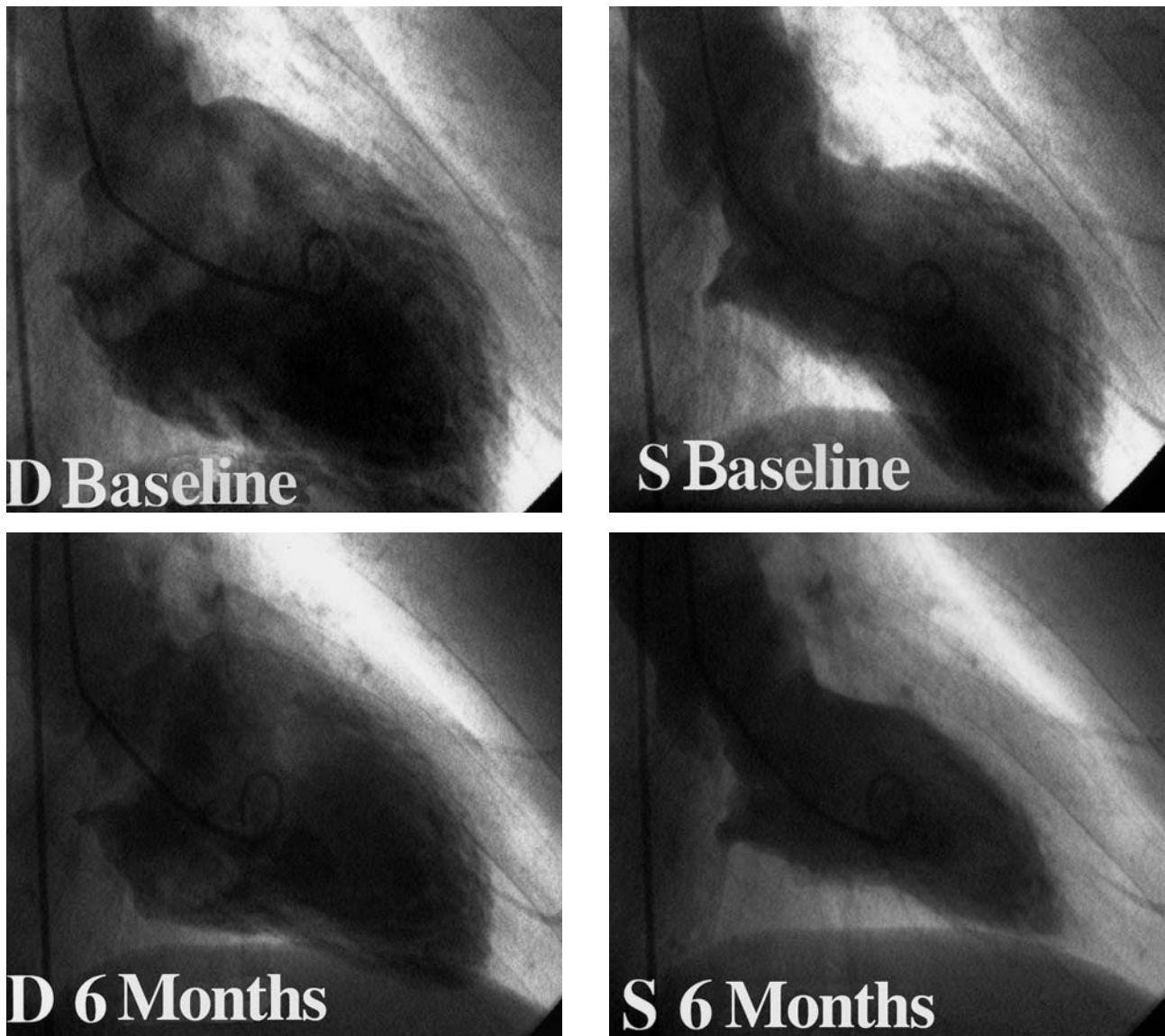
### Follow-up Protocol

The protocol included carrying out the following tests: markers of myocardial damage (creatinine kinase, creatine kinase MB isoenzyme and troponin T) for 24 hours after the procedure; low-dose dobutamine echocardiography before implantation and after 6 months; magnetic resonance imaging before implantation and after 6 months; Holter ECG after 3 weeks and 6 months; and clinical visits with laboratory analysis, ECG and chest x-ray after 3 weeks and 6 months. The first patient also underwent a catheterization study and ventriculography after 6 months (Figure 1).

### Cell Implantation

Bone-marrow cells were extracted 10-15 days after infarction. The skin was disinfected with povidone-iodine before puncture of the iliac crest with a trocar connected to a 20-mL syringe for extraction of the cells. Approximately 5 mL of bone marrow were aspirated on each puncture.

The mononuclear fraction was separated by centrifuging with Ficoll reagent before lysing the erythrocytes with water. The cell suspension was resuspended in RPMI-1640 with 2% plasma (from the same patient). The number of cells was adjusted to 1  $10^6$ /mL and the mononuclear fraction was transferred to a teflon bag and incubated overnight at 37°C under 5% CO<sub>2</sub>. The cells were centrifuged and



**Figure 1.** Ventriculography at baseline (akinesia in anterior region) and after 6 months (with clear improvement in contractility of anterior region) for patient 1. D indicates diastole; S, systole.

heparinized the following day, and their viability was assessed with trypan blue.

Intracoronary implantation of the cells into the infarcted region was performed after 10-15 days. The left coronary artery was cannulated with the catheter-guide and a coaxial balloon catheter was introduced into the stented segment then inflated to 2-4 atmospheres. The wire guide was then withdrawn and the opening used for infusion of the cells. The suspension of stem cells was introduced into a 50-mL syringe connected to the infusion catheter. Two-minute periods of left coronary artery occlusion with slow infusion of the suspension (1 mL/min) were alternated with periods of 1 minute of reperfusion.

### Immunophenotypic Analysis

The different subpopulations of progenitor cells in the infusion were quantified with an immunophenotypic analysis. Direct immunofluorescence techniques were used in a FACScalibur cytometer (Becton Dickinson Biosciences, BDB) to detect the following surface markers: CD45-FITC, CD117-PE, CD 34 PC5 and CD 133-1-APC (CD45 and CD117 from BDB, CD34 from Immunotech and CD133-1 from Miltenyi Biotec). Samples were acquired with the Cell QUEST program (BDB) and data analyzed with Paint-A-GATE PRO (BDB).



## Stress Echocardiography With Dobutamine

The apical 4-chamber view was used for basal end-diastolic and end-systolic left ventricular planimetry of the endocardial border. This procedure was repeated for the apical 2-chamber view. The echocardiographic software calculated the volumes and ejection fraction using the Simpson disc method. The patient was continually monitored by two-dimensional echocardiography during infusion of intravenous dobutamine and for 10 minutes after infusion had finished. The initial dose of dobutamine was 5 mg/kg/min. After 3 minutes, the dose was increased to 10 g/kg/min, and, finally, a third dose of 20 g/kg/min was administered for a further 3 minutes. The left ventricle was divided into 16 segments: septal proximal anterior, septal medial anterior, septal proximal posterior, septal medial posterior, septal apical posterior, anterior proximal, anterior medial, anterior apical, lateral proximal, lateral medial, lateral apical, posterior proximal, posterior medial, inferior proximal, inferior medial and inferior apical. The long and short axis parasternal and 4-, 3- and 2- chamber apical views were used for the study. The motion of each segment was classified from 1 to 4 as follows: 1-normal; 2-hypokinetic; 3-akinetic; and 4-dyskinetic.

There were two responses to administration of dobutamine: negative, that is, no change between basal examination and dobutamine stress examination, and positive for viability, that is, an improvement in contractility in the region with basal alterations in contractility (infarcted region).

A 12-lead ECG was recorded and blood pressure measured before the infusion and every 3 minutes until 10 minutes after the test had finished.

The test was aborted in any of the following circumstances: *a*) maximum heart rate reached according to age and sex for untrained persons; *b*) intense angina; *c*) limiting symptoms such as dyspnea or dizziness; *d*) ST-segment depression by more than 3 mm; *e*) decrease in systolic blood pressure by more than 20 mmHg; *f*) systolic blood pressure above 210 mm Hg, and *g*) frequent or complex ventricular arrhythmias.

## Magnetic Resonance Imaging

All studies were performed with a 1.5T ECG gated imaging system (General Electric Signa 4.0) with surface and phased array body coils. Measurement of the different parameters was performed according to an established procedure.<sup>8</sup> Segmentation of the left ventricle was the same as for the echocardiographic study. The wall motion score index was calculated by summing the scores for each of the segments and dividing by 16.

## Statistics

Continuous variables were expressed as mean (SD) and categorical variables as their absolute value and percentage. Continuous variables were compared with the Student *t* test for paired data. Variables that did not have a normal distribution were compared with the Wilcoxon test for paired data. The Fisher exact test was used for categorical variables. A value of *P* < .05 was considered statistically significant. The data were analyzed with the SPSS 10.0 statistical package.

## RESULTS

The follow-up protocol has been completed for 5 patients (mean age, 65 [10] years), all of whom were male. Tenecteplase was administered to all patients at 1.75 (0.35) hours after onset of pain. The maximum level of creatine kinase (CK) was 1307 (452) UI/L and that of the CK MB isoenzyme was 150 (73) UI/L. In 1 patient, there were no significant lesions. Stent angioplasty was performed in the 4 remaining patients (primary in 1 and facilitated in 3) at 59 (56) hours after onset of symptoms. There were no events between the angioplasty (or catheterization) and the implantation of stem cells. Catheterization was repeated in 1 patient after 6 months because he complained of atypical chest pain and the absence of coronary disease was confirmed. The ventriculography findings of this patient are shown in Figure 1.

## Cell Implantation

Implantation of the mononuclear fraction of the bone marrow was performed 12 (5) days after infarction (range, 5-20 days). Each patient received 52 10<sup>6</sup> (34 10<sup>6</sup>) mononuclear cells (range, 11 10<sup>6</sup> to 90 10<sup>6</sup> cells). The characteristics of the injected cells were as follows: percentage of CD34<sup>+</sup>, 1.25% (0.80)%; CD117<sup>+</sup>, 1.72% (1.18)%; CD133<sup>+</sup>, 0.75% (0.60)%.

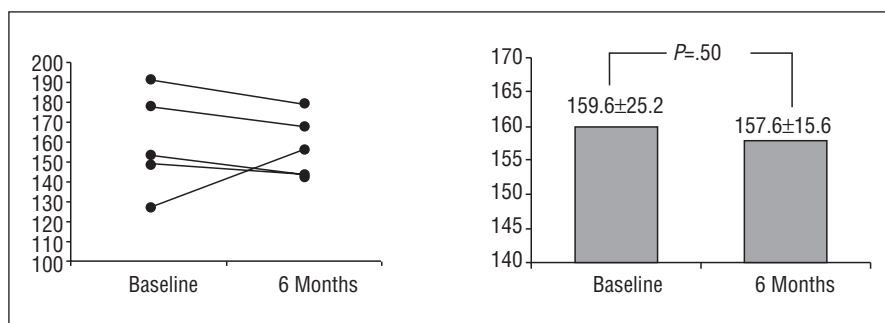
## Clinical Evolution

The levels of myocardial markers after cell implantation were normal. Subsequent clinical evolution of the patients was satisfactory. After 6 months of follow up, no cardiac event had been reported. The Holter ECG did not show any evidence of ventricular arrhythmias. One patient had a transient ischemic attack 1 month after implantation without sequelae.

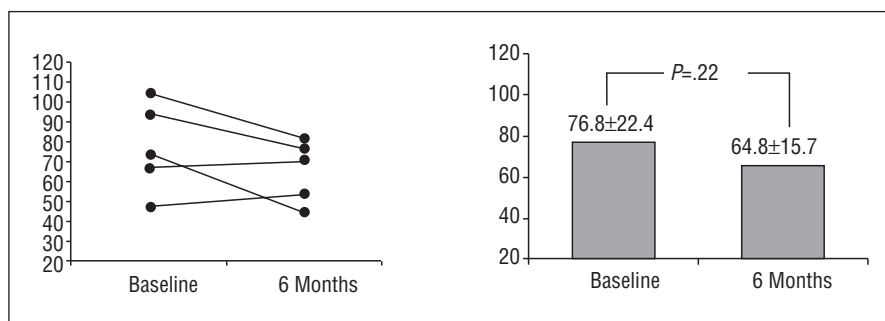
## Viability

During administration of dobutamine, heart rate

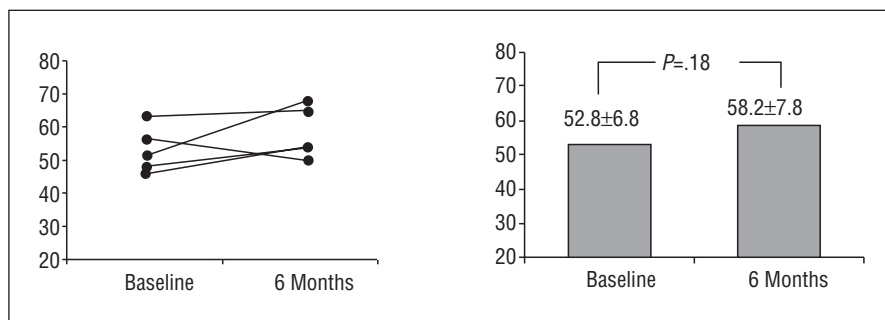
**Figure 2.** Evolution of left ventricular end-diastolic volume in the group of 5 patients.



**Figure 3.** Evolution of left ventricular end-systolic volume in the group of 5 patients.



**Figure 4.** Evolution of the left ventricular ejection fraction in the group of 5 patients.



increased slightly (from 56 [8] bpm to 59 [14] bpm under stressed conditions;  $P=NS$ ) and blood pressure decreased slightly (from 105 [12]/57 [5] mm Hg to 97 [21]/53[6] mm Hg under stressed conditions;  $P=NS$ ). There were no effects or complications.

In the initial tests, administration of low and medium doses of dobutamine caused an increase in contractility in infarcted regions in 2 patients. The echocardiogram was negative for viability for the remaining 3 patients.

The administration of dobutamine in the baseline study led to an increase in ejection fraction of 2.4 (37.7)%, which had changed to 11.6 (4.3)% after 6 months ( $P=.04$ ).

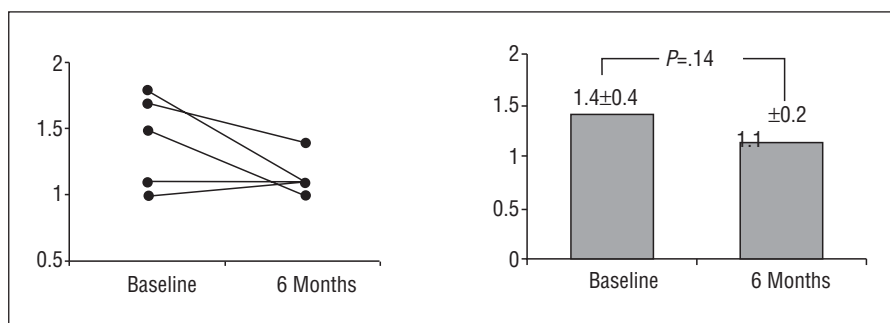
## Remodeling

The following baseline parameters were derived from magnetic resonance imaging for the left ventricle: end-diastolic volume, 159 (25) mL, end-

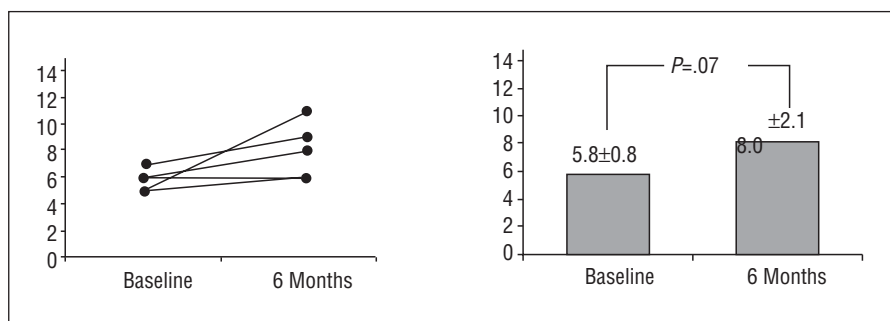
systolic volume 77 (22) mL, and ejection fraction, 53 (7)%. After 6 months, end-diastolic volume had hardly changed (157 [16] mL;  $P=NS$ ), whereas end-systolic volume decreased (65 [16] mL;  $P=NS$ ) and the ejection fraction increased (58 [8]%;  $P=NS$ ), though these changes were not significant. Figures 2, 3, and 4 show the evolution of the ventricular parameters in the population studied.

Analysis of the 3 patients with echocardiograms with negative dobutamine test for viability yields the following results: end-diastolic volume decreased (from 173 [21] mL at baseline to 163 [18] mL after 6 months;  $P=.03$ ), end-systolic volume decreased (from 90 [15] mL at baseline to 67 [20] mL after 6 months;  $P=.025$ ) and ejection fraction increased (from 48% [2] at baseline to 59% [8] after 6 months of follow up).

At baseline, 22 out of the 80 segments of the 5 patients showed asynergy. The baseline wall motion score index of the region was 1.4 [0.4]. After 6 months, 10 segments had decreased contractility and



**Figure 5.** Evolution of wall motion score index in the group of 5 patients.



**Figure 6.** Evolution of end-diastolic thickness of the infarcted region in the group of 5 patients.

the wall motion score index of the region was 1.1 (0.2) ( $P=NS$ ; Figure 5).

Finally, the end-diastolic thickness of the infarcted wall was studied and the minimum was measured in regions of asynergy. The end-diastolic thickness increased from 5.8 (0.8) mm at baseline to 8.0 (2.1) mm after 6 months ( $P=.07$ ; Figure 6).

## DISCUSSION

Our preliminary results suggest that intracoronary implantation of bone-marrow-derived stem cells from the same patient into regions that have suffered acute myocardial infarction is a feasible and safe technique. There were no complications during the stay in hospital or during the 6 months of follow up. Moreover, analysis of the evolution of the ventricular parameters in patients without viability before implantation suggests that tissue that was thought to be irreversibly damaged may regain functionality.

Patients with viability demonstrated by dobutamine echocardiography may have evolved favorably because the initial akinesia of the tissue was reversible (myocardial stunning) and so was viable. Nevertheless, the improvement in patients with negative viability by echocardiography in the dobutamine stress test was unexpected according to the perhaps obsolete idea that necrotic tissue cannot regain contractile function. The lack of viability or, at least, contractile capacity of the infarcted regions is supported by the negative result in the dobutamine echocardiography. It could be argued that dobutamine echocardiography is not a precise

technique for the diagnosis of viability. Thallium imaging or positron emission tomography may have detected greater viability through identification of metabolic activity. However, comparative studies have shown that dobutamine echocardiography has similar sensitivity and greater specificity than thallium imaging in the identification of stunned myocardium after a myocardial infarction.<sup>9</sup> An akinetic region that does not improve with infusion of low doses of dobutamine has a probability of less than 15% of recovering contractile capacity. In contrast, favorable evolution cannot be attributed to greater contractility of regions that are normal at baseline because the wall motion score index decreased during follow up, indicating that asynergic regions at baseline have better functionality.

Another clinically interesting aspect is that the improvement in ventricular function due to administration of medium doses of dobutamine was significantly greater after 6 months. Although we cannot draw firm conclusions, these results do suggest that implantation of stem cells increases the capacity of the myocardium to respond to inotropic stimuli and so treatment might increase patients' exercise capacity.

Finally, we should highlight the increase in end-diastolic thickness in our patients. An end-diastolic thickness below 5.5 mm has been associated with a very low probability of improvement.<sup>10</sup> It is reasonable to think that thickness increased because there were more myocytes in this region.

Only 7 groups have published results obtained after implantation of stem cells in humans in a total of 72 patients, but all studies confirm that the technique

feasible and safe.<sup>11-17</sup> Only 2 of these studies implanted cells in patients with acute myocardial infarction.<sup>12,13</sup> Intracoronary injection was used in both studies although, unlike our study, the procedure was performed between 4 and 9 days after onset of acute signs and symptoms. Some authors suggest that the stem cells may participate in the inflammatory process instead of the formation of myocardium and revascularization if implanted too soon after infarction, but this possibility has not been proven.<sup>12</sup> The only study performed to date in which cardiomyocytes were implanted in rats immediately after infarction, after 2 weeks, and after 4 weeks, supports this suggestion because only implantation after 2 weeks was effective.<sup>18</sup> Additionally, these findings might suggest that once healing has started, the benefit may also be lower.

The follow-up results of the 7 studies mentioned above agree with our results. All suggest that there is clinical improvement and improvement of the perfusion parameters and ventricular function measured by exercise tolerance testing,<sup>16,17</sup> simple photon emission tomography,<sup>11,14,16,17</sup> angiography,<sup>13,16</sup> dobutamine echocardiography,<sup>12,13</sup> isotopic ventriculography,<sup>12</sup> positron emission tomography<sup>13</sup> or magnetic resonance imaging.<sup>15</sup>

Menasche et al<sup>19</sup> used myoblasts derived from skeletal muscle for the first time and these authors have recently published their study of a group of 10 patients with prior infarction and an ejection fraction less than 35% in whom the implantation coincided with revascularization by coronary artery bypass grafting.<sup>20</sup> The ejection fraction improved and congestive symptoms decreased but is it not clear whether implantation of myoblasts was responsible for the improvement. It may be important that several patients had sustained ventricular tachycardia 2 to 3 weeks after the procedure, suggesting that implantation of myoblasts can be arrhythmogenic.

Of course, we should be prudent and recognize that we are only at the start of an exciting journey towards a cell therapy that can prevent and treat postinfarction ventricular dysfunction.<sup>21</sup> And, as always with such tentative journeys, there are more questions than answers. We still do not even know if the cells remain in the necrotic region, though the contribution of Pagnini et al<sup>22</sup> has provided some clarification. These authors showed for the first time that myoblasts not only survive in the human heart, but that they form viable grafts. We also do not know what they do in the necrotic tissue. Do they replace it? Do they increase the number of cells with contractile capacity? Do they stimulate angiogenesis? Do they prevent subsequent expansion and remodeling? Finally, many practical questions remain that can only be answered by randomized clinical studies. For example, would the association of drugs

favor myocardial regeneration? Would it be more effective to implant into hearts with chronic dysfunction? Would it be more effective to administer the granulocyte colony-stimulating factor, perhaps locally, to favor regeneration of heart stem cells?

## REFERENCES

1. Rogers WJ, Canto JG, Lambrew CT, Tiefenbrunn AJ, Kinkaid B, Shultz DA, et al. Temporal trends in the treatment of over 1.5 million patients with myocardial infarction in the US from 1990 to 1999: The National Registry of Acute Myocardial Infarction 1, 2, and 3. *J Am Coll Cardiol* 2000;36:2056-63.
2. Hasdai D, Behar S, Wallentin L, Danchin N, Gitt AK, Boersma E, et al. A prospective survey of the characteristics, treatments and outcomes of patients with acute coronary syndromes in Europe and the Mediterranean basin. The Euro Heart Survey of Acute Coronary Syndromes. *Eur Heart J* 2002;23:1190-201.
3. Stone G, Peterson MA, Lansky A, Dangas G, Mehran R, Leon MB. Impact of normalized myocardial perfusion after successful angioplasty in acute myocardial infarction. *J Am Coll Cardiol* 2002;39:591-7.
4. Cowie MR, Wood DA, Coats AJS, Thompson SG, Poole-Wilson PA, Suresh V, et al. Incidence and aetiology of heart failure: a population based study. *Eur Heart J* 1999;20:421-8.
5. Orlic D, Kajstura J, Chimenti N, Janokui I, Anderson SM, Li B, et al. Bone marrow cells regenerate infarcted myocardium. *Nature* 2001;410:701-5.
6. Beltrami AP, Urbanek K, Kajstura J, Yan SM, Finato N, Bussani R, et al. Evidence that human cardiac myocytes divide after myocardial infarction. *N Engl J Med* 2001;344:1750-7.
7. Quaini F, Urbanek K, Beltrami AP, Finato N, Beltrami CA, Nadal-Guinard B, et al. Chimerism of the transplanted heart. *N Engl J Med* 2002;346:5-15.
8. Lorenz CH, Walker ES, Morgan VL, Klein SS, Graham TP. Normal human right and left ventricular mass, systolic function, and gender differences by cine magnetic resonance imaging. *J Cardiovasc Magn Reson* 1999;1:7-21.
9. Schinkel AF, Bax JJ, Geleijnse ML, Boersma E, Elhendy A, Roelandt JR, et al. Noninvasive evaluation of ischaemic heart disease: myocardial perfusion imaging or stress echocardiography? *Eur Heart J* 2003;24:789-800.
10. Baer FM, Voth E, Schenckler CA, Theissen P, Schicha H, Sechtem U. Comparison of low-dose dobutamine-gradient-echo magnetic resonance imaging and positron emission tomography with [18F] fluorodeoxyglucose in patients with chronic coronary artery disease. *Circulation* 1995;91:1006-15.
11. Hamano K, Nishida M, Hirata K, Mikamo A, Li TS, Harada M, et al. Local implantation of autologous bone marrow for therapeutic angiogenesis in patients with ischemic heart disease: clinical trial and preliminary results. *Jpn Circ J* 2001;65:845-7.
12. Strauer BE, Brehm M, Zeus T, Köstering M, Hernández A, Sorg RV, et al. Repair of infarcted myocardium by autologous intracoronary mononuclear bone marrow cell transplantation in humans. *Circulation* 2002;106:1913-8.
13. Assmus B, Schächinger V, Teupe C, Britten M, Lehmann R, Döbert N, et al. Transplantation of progenitor cells and regeneration enhancement in acute myocardial infarction (TOPCARE-AMI). *Circulation* 2002;106:3009-17.
14. Stamm C, Westphal B, Kleine HD, Petzsch M, Kittner C, Klinge H, et al. Autologous bone-marrow stem-cell transplantation for myocardial regeneration. *Lancet* 2003;361:45-6.
15. Tse HF, Kwong YL, Chan JK, Lo G, Ho CL, Lau CP. Angiogenesis in ischaemic myocardium by intramyocardial

- autologous bone marrow mononuclear cell implantation. *Lancet* 2003;361: 47-9.
16. Perin EC, Dohmann HF, Borojevic R, Silva SA, Sousa AL, Mesquita CT, et al. Transendocardial, autologous bone marrow cell transplantation for severe, chronic ischemic heart failure. *Circulation* 2003;107:2294-302.
17. Fuchs S, Satler LF, Kornowski R, Okubagzi P, Weisz G, Baffour R, et al. Catheter-based autologous bone marrow myocardial injection in no-option patients with advanced coronary artery disease. A feasibility study. *J Am Coll Cardiol* 2003;41:1721-4.
18. Li RK, Mickle DA, Weisel RD, Rao V, Jia ZQ. Optimal time for cardiomyocyte transplantation to maximize myocardial function after left ventricular injury. *Ann Thorac Surg* 2001;72: 1957-63.
19. Menasche P, Hagege AA, Scorsin M, Pouzet B, Desnos M, Duboc D, et al. Myoblast transplantation for heart failure. *Lancet* 2001;357:279-80.
20. Menasche P. Cell transplantation for the treatment of heart failure. *Semin Thorac Cardiovasc Surg* 2002;14:157-66.
21. Prósper F, Herreros J, Alegría E. Utilización de células madre para la regeneración miocárdica en la insuficiencia cardíaca. *Rev Esp Cardiol* 2003;56:935-9.
22. Pagani FD, DerSimonian H, Zawadzka A, Wetzel K, Edge AS, Jacoby DB, et al. Autologous skeletal myoblasts transplanted to ischemia-damaged myocardium in humans. Histological analysis of cell survival and differentiation. *J Am Coll Cardiol* 2003;41: 879-88.