

Normal Conventional Electrocardiogram with Negative Pharmacological Stress Test does not Rule Out Brugada Syndrome

Soledad Cabezón Ruiz, Francisco Errazquin Sáenz de Tejada, Alonso Pedrote Martínez, Juan Enrique Morán Risco, Jesús Marín Morgado, and José María Fernández Pérez

Laboratorio de Electrofisiología Cardíaca. Servicio de Cardiología.
Hospital Universitario Virgen del Rocío. Sevilla. España.

The diagnosis of Brugada syndrome, or right bundle-branch block with an elevated ST segment and negative T waves in V1-3, is obscured by the transitory normalization of the electrocardiogram, which can be unmasked by administering sodium-channel blockers. It has been recently reported that the condition can be underdiagnosed if only conventional precordial leads are used. We present the cases of two asymptomatic patients, a mother and son, with a family history of sudden cardiac death in first-degree relatives. Baseline ECGs obtained in conventional leads and one and two intercostal spaces above conventional electrode sites were similar, normal in the mother and «saddle-like» in the son. A flecainide stress test elicited the characteristic pattern of Brugada syndrome in both patients, but only in the high leads. Pharmacological stress testing with conventional precordial lead recordings does not rule out Brugada syndrome. We recommend that ECG recordings should include leads in the second and third intercostal spaces.

Key words: *Brugada syndrome. Ventricular arrhythmia. Electrophysiology.*

El electrocardiograma convencional normal con test de provocación farmacológico negativo no descarta el síndrome de Brugada

El diagnóstico del síndrome de Brugada, bloqueo de rama derecha con segmento ST elevado y ondas T negativas de V1-3, se encuentra dificultado por la normalización transitoria del electrocardiograma, y puede ser desenmascarado por los bloqueadores de los canales de sodio. Recientemente se ha comunicado su posible infravaloración con la sola utilización de las derivaciones precordiales convencionales. Presentamos los casos de 2 pacientes asintomáticos, madre e hijo, con antecedentes familiares de primer grado de muerte súbita. Los ECG basales en las derivaciones precordiales convencionales y en uno y dos espacios intercostales por encima fueron similares, normal en la madre y en «silla de montar» en el hijo. Tras test de flecainida, ambos desarrollaron el patrón electrocardiográfico típico del síndrome de Brugada exclusivamente en las derivaciones superiores. El test de provocación farmacológico con las derivaciones convencionales no descarta el síndrome de Brugada, y es necesario incluir sistemáticamente las derivaciones precordiales en el segundo y tercer espacios intercostales.

Palabras clave: *Síndrome de Brugada. Arritmia ventricular. Electrofisiología.*

Full Spanish text available at: www.revespcardiol.org

INTRODUCTION

Brugada syndrome covers a group of patients at risk of ventricular fibrillation without structural heart disease

and an electrocardiographic pattern of right bundle-branch block (RBBB) and elevation of the ST segment in precordial leads.¹ The condition may be transitory in up to 40% of cases and can be unmasked by sodium channel blockers.² Recently, possible underdiagnosing has been reported, even with pharmacological stress tests, when conventional electrocardiographic leads have been used alone.³ We report two cases in which the syndrome could be diagnosed exclusively using precordial leads placed two and three intercostal spaces (ICS) higher.

Correspondence: Dra. S. Cabezón Ruiz.
Calvo Sotelo, 1. 41809 Albaida del Aljarafe. Sevilla. España.
E-mail: scabezonzruiz@hotmail.com

Received 29 April 2002.
Accepted for publication 4 July 2002.

CLINICAL CASES

Case 1

This 42-year-old woman had a father who died suddenly at the age of 47 years. In a routine ECG, the typical pattern of Brugada syndrome was observed, RBBB with elevation of the ST segment and a downward slope, and negative T waves from V1 to V3. After excluding the existence of structural heart disease, the diagnosis of asymptomatic Brugada syndrome was established, with a characteristic spontaneous electrocardiographic pattern. In light of this finding, an electrophysiological study (EPS) was performed, which disclosed a normal baseline ECG in the conventional leads and two and three ICSs higher (Figures 1A and B). A flecainide test (2 mg/kg during 10 min i.v.) with the precordial V1 to V3 leads in the usual positions did not elicit the typical Brugada pattern (Figure 1C). Nevertheless, by placing the leads one or two spaces higher, the characteristic ECG was observed (Figure 1D). During EPS, which was carried out according to the recommended protocol, sustained ventricular arrhythmia was not induced. At 3 months the patient remained asymptomatic.

Case 2

This 23-year-old man was the son of the patient in case 1. He was also asymptomatic, free of structural heart disease, and had a baseline ECG with a pattern of RBBB and saddle elevation of the ST segment from V1 to V3. The pattern was similar in the conventional

precordial leads and positioned two and three ICSs higher (Figure 2A and B). Again, a flecainide test only elicited the typical pattern of Brugada syndrome in the high leads (Figures 2C and D). During EPS, no sustained ventricular arrhythmias were induced and the patient remains asymptomatic.

This patient had a 19-year-old sister with Brugada syndrome who was diagnosed after a pharmacological stress test using the conventional precordial leads, and a small brother who had not yet had been studied (Figure 3).

DISCUSSION

The Brugada syndrome refers to a group of patients without structural heart disease, at risk of presenting ventricular fibrillation, with a mean mortality of 10% per year in symptomatic patients.⁴ More than 25% of the families have a pattern of dominant autosomal heredity with a variable expression.⁵ Approximately half of the affected patients will develop disease.⁶

Initially, two possible electrocardiographic patterns were described, consisting of a RBBB pattern and ST segment elevation in the right precordial leads showing a downward sloping or saddle pattern. Currently, the electrocardiographic image does not allow the syndrome to be diagnosed without pharmacological induction of the downward sloping ST elevation.⁷ On the other hand, in a large percentage of cases, as much as 40%, the electrocardiographic pattern is temporarily normalized, which makes its diagnosis difficult.²

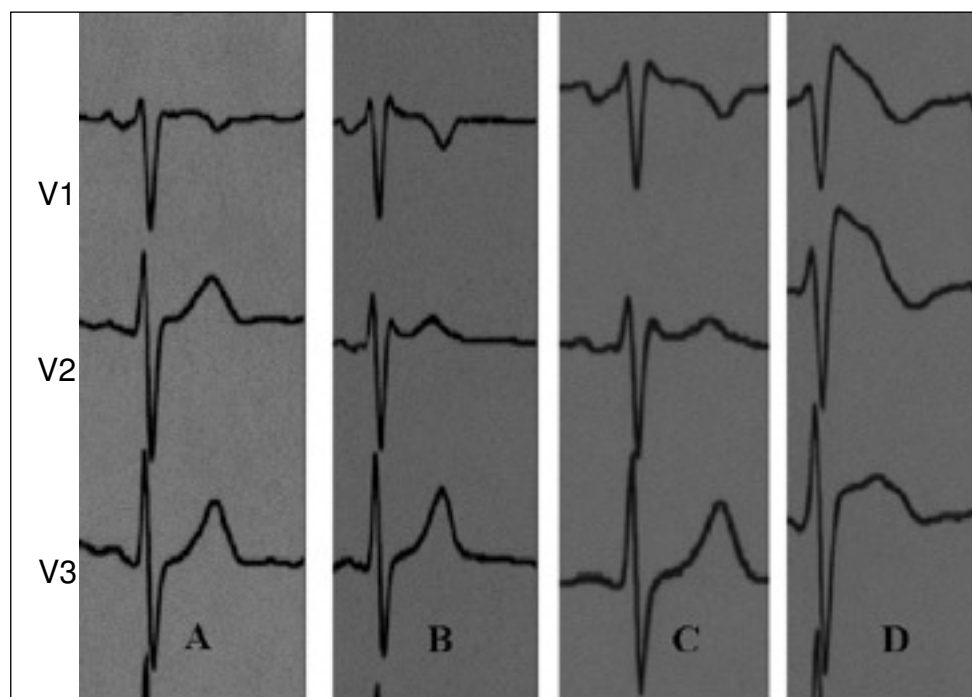


Fig. 1. Baseline ECG in the conventional right precordial leads (A) and one or two intercostal spaces (ICS) higher (B), corresponding to the patient in case 1. The ECG after a flecainide test in the conventional right precordial leads (C) and one and two ICSs higher (D)

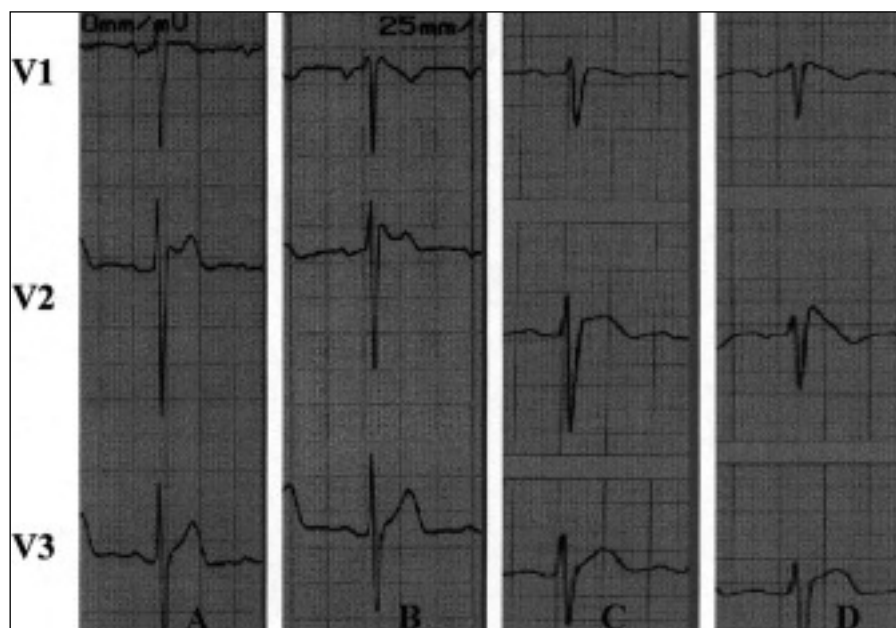


Fig. 2. Baseline ECG in the conventional right precordial leads (A) and one and two intercostal spaces (ICS) higher (B), corresponding to patient 2. ECG after a flecainide test, in the conventional right precordial leads (C) and one and two ICSs (D) higher.

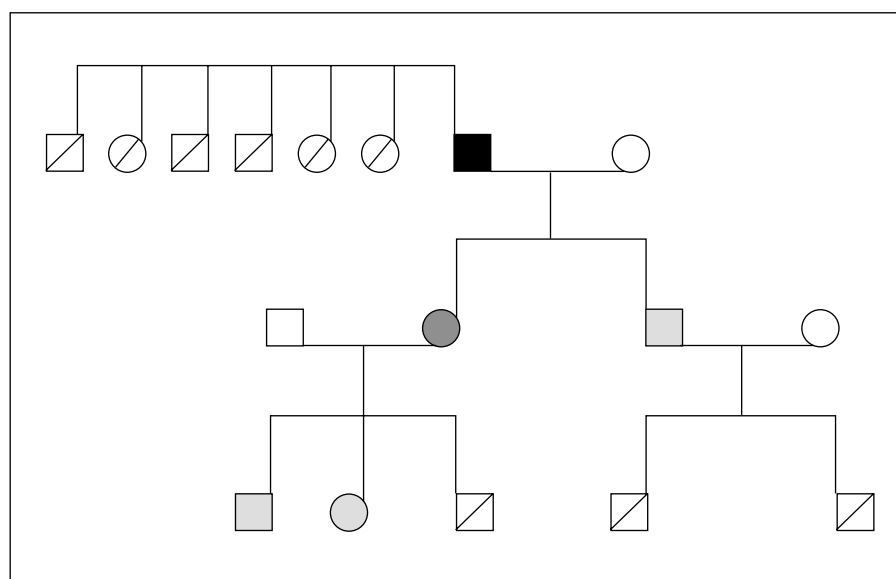


Fig. 3. Genealogical tree. The squares stand for men and the circles stand for women. Black indicates symptomatic patients with Brugada syndrome, gray indicates asymptomatic patients with a typical spontaneous electrocardiogram, and dotted elements indicate asymptomatic patients who develop the pattern after a pharmacological stress test. The crossed-out symbols indicate family members who were not studied and the white symbols indicate healthy family members.

This syndrome is determined genetically by mutations in the sodium channels (SCN5A) coded by chromosome 3.² The decrease in these sodium channels determines a voltage gradient between the ventricular epicardium and endocardium, with prolongation of the action potential and dispersion of the epicardial repolarization. This creates a situation of vulnerability for the development of ventricular arrhythmias due to re-entry.⁸ The effect of sodium channel blockers on damaged channels can facilitate these changes and unmask the electrocardiographic pattern.²

Recently, Sangwatanaroj et al.,³ based on the work of Shimizu et al.⁹ with electrocardiographic mapping

of the body surface, concluded that raising the precordial leads increases the diagnostic sensitivity for the syndrome, especially after carrying out a pharmacological stress test. According to these authors, the increased sensitivity obtained by raising the precordial leads is due to an improvement in the capacity for detecting the delayed conduction between the anterior wall and right ventricular outflow tract by increasing the recording area, where otherwise unapparent repolarization disturbances may be revealed.

Both of the cases reported here support the need to modify the protocol that is usually used to screen for Brugada syndrome. It is necessary to systematically

include precordial leads placed two and three ICSs higher. To do otherwise could lead to a high percentage of false negatives in a condition that has a potentially fatal outcome.

REFERENCES

1. Brugada P, Brugada J. Right bundle-branch block, persistent ST segment elevation and sudden cardiac death: a distinct clinical and electrocardiographic syndrome. A multicenter report. *J Am Coll Cardiol* 1992;20:1391-6.
2. Gussak I, Antzelevitch C, Bjerregaard P, Towbin J, Chaitmn B. The Brugada syndrome: clinical, electrophysiological and genetics aspects. *J Am Coll Cardiol* 1999;102:54-60.
3. Sangwatanaroj S, Prechawat S, Sunsaneewitayaku B, Sitthisook S, Tosukhowong P, Tungsanga K. New electrocardiographic leads and procainamide test for the detection of the Brugada syndrome sign in sudden unexplained death syndrome survivors and their relatives. *Eur Heart J* 2001;22:2290-6.
4. Atarashi H, Ogawa S, Harumi K, Sugimoto T, Inoue H, Murayama M, et al. Three year follow-up of patients with right bundle branch block and ST segment elevation in the right precordial leads. *J Am Coll Cardiol* 2001;37:1916-20.
5. Belhassen B, Viskin S, Fish R, Glick A, Setbou I, Eldae M. Effects of electrophysiologic-guided therapy with class IA antiarrhythmic drugs on the long-term outcome of patients with idiopathic ventricular fibrillation with or without the Brugada syndrome. *J Cardiovasc Electrophysiol* 1999;10:1301-12.
6. Brugada J, Brugada P, Brugada R. El síndrome de Brugada y las miocardiopatías derechas como causa de muerte súbita. Diferencias y similitudes. *Rev Esp Cardiol* 2000;53:275-85.
7. Brugada J, Brugada R, Antzelevitch C, Towbin J, Nademance K, Brugada P. Long-term follow-up of individuals with the electrocardiographic pattern of right bundle-branch block and ST-segment elevation in precordial leads V1 to V3. *Circulation* 2002;105:73-8.
8. Antzelevitch C. The Brugada syndrome: ionic basis and arrhythmia mechanisms. *J Cardiovasc Electrophysiol* 2001;12:268-72.
9. Shimizu W, Matsou K, Takagi M, Tanabo Y, Aiba T, Taguchi A, et al. Body surface distribution and response to drugs of ST segment elevation in Brugada syndrome: clinical implication of eighty-seven-lead body surface potential mapping and its application to twelve-lead electrocardiograms. *J Cardiovasc Electrophysiol* 2000; 11:396-404.