

Nuclear Magnetic Resonance Imaging in Patients With Cardiac Pacing Devices

Francisco Buendía, Juan M. Sánchez-Gómez, María J. Sancho-Tello, José Olagüe, Joaquín Osca, Óscar Cano, Miguel A. Arnau, and Begoña Igual

Unidad de Arritmias, Hospital Universitario La Fe, Valencia, Spain

Currently, nuclear magnetic resonance imaging is contraindicated in patients with a pacemaker or implantable cardioverter-defibrillator. This study was carried out because the potential risks in this situation need to be clearly defined. This prospective study evaluated clinical and electrical parameters before and after magnetic resonance imaging was performed in 33 patients (5 with implantable cardioverter-defibrillators and 28 with pacemakers). In these patients, magnetic resonance imaging was considered clinically essential. There were no clinical complications. There was a temporary communication failure in 2 cases, sensing errors during imaging in 2 cases, and a safety signal was generated in 1 pacemaker at the maximum magnetic resonance frequency and output level. There were no technical restrictions on imaging nor were there any permanent changes in the performance of the cardiac pacing device.

Key words: Pacemakers. Magnetic resonance imaging. Safety.

Resonancia magnética nuclear en pacientes portadores de dispositivos de estimulación cardiaca

La resonancia magnética está actualmente contraindicada a los pacientes portadores de dispositivos de estimulación cardiaca. Ante la necesidad de concretar los riesgos potenciales derivados de esta situación, surgió este estudio. De forma prospectiva, se evaluaron parámetros clínicos, eléctricos y técnicos antes y después de la realización de la prueba en 33 pacientes (5 desfibriladores automáticos implantables, 28 marcapasos), en los que se consideró clínicamente indispensable realizarla. No se apreciaron complicaciones clínicas. Se detectaron dos casos de fallo temporal de telemetría, dos errores de detección durante la exploración y una respuesta de seguridad en un marcapasos a frecuencia magnética y salida máxima. No hubo limitaciones técnicas en la adquisición de imágenes ni alteraciones permanentes del funcionamiento de los dispositivos de estimulación cardiaca.

Palabras clave: Marcapasos. Resonancia magnética. Seguridad.

INTRODUCTION

Magnetic resonance imaging (MRI)—a noninvasive and precise imaging technique—has become much more widely used in recent years.¹ It is increasingly common to request an MRI scan for patients who already have a cardiac pacing device, either a pacemaker (PM) or implantable cardioverter-defibrillator (ICD). It is estimated that, after implantation of the device, each patient has a 50% to 75% probability of requiring an MRI scan during his or her life.²

The first data obtained in this field during the 1980s were disheartening. Serious complications, both electrical and clinical, were documented and there were even some reports of deaths.^{3,4} A contraindication for MRI was therefore established.

The current devices are smaller and made of materials with less risk of electromagnetic interference. In recent years, small safety studies have been performed.⁵⁻⁹ Although these have not been sufficient to change the recommended contraindications, they do suggest that no important complications occur if certain safety conditions are maintained.

We conducted a prospective study to assess the risks of MRI in patients with modern cardiac pacing devices.

For 14 months (October 2007 to December 2008), 29 patients with a cardiac pacing device

Correspondence: Dr. F. Buendía Fuentes.
Calderón de la Barca, 9, pta. 18, 46010 Valencia, España.
E-mail: franbuendia@gmail.com

Received April 30, 2009.
Accepted for publication July 21, 2009.

for whom the MRI scan was indicated as the only available diagnostic test were included in the study. Patients with abandoned leads were not included. All 33 patients were informed of the possible consequences of the test and all gave their consent to the procedure.

Scans were performed in 5 patients with ICDs and 28 with PMs, 4 of whom were PM-dependent, defined as the absence of an independently stable ventricular rhythm above 40 beats/min.

Before and after the test, the devices were fully checked, recording the make, model, pacing mode, frequency of follow-up, battery status (impedance and/or voltage), pacing and detection thresholds and pacing impedance. Fifty-eight leads were analyzed (33 ventricular and 25 atrial). The pacing threshold was calculated for all cases, varying only the amplitude of the impulse, and so was expressed in volts.

In accordance with current guidelines, the pacing mode was changed from V00 to D00 in PM-dependent patients. Antitachycardiac therapies were deactivated in ICD patients. Bipolar detection was programmed, setting the output at double the pacing threshold and detection at half the amplitude of the wave detected, when the device so permitted.

All studies were performed with a 1.5T MRI apparatus (Siemens Magnetom-Avanto), with and SAR limit <4 W/kg for the entire body surface.

During the test, electrocardiographic and pulse oximetry monitoring was carried out and verbal contact with the patient was maintained. As a safety measure, advanced cardiopulmonary resuscitation equipment was on hand in the MRI hall, along with an external cardioverter defibrillator and the programmer of the pacing device.

After the scan, a systematic questionnaire was administered with questions about pain, sensation of movement of the device, heat, or discomfort. In addition, the duration of the test was noted and the responsible radiologist was asked whether there were any defects in the image or any technical limitations.

The distribution of pacing mode, type of pacing device and type of MRI is shown in Table 1.

The quantitative parameters were analyzed using the *t* test for paired samples. In series with n<30 (battery impedance and voltage, atrial impedance, atrial and ventricular detection), a Mann-Whitney *U* test was used.

For the analysis of changes in the pacing threshold, the presence of variation was defined as a dichotomous variable. Subsequently, using the #c² test, the possible relationship between the presence of variation and the paced chamber (atrium, ventricle) was analyzed, along with whether the site was infradiaphragmatic or supradiaphragmatic.

TABLE 1. Pacing Mode, Manufacturer, and Type of Magnetic Resonance Imaging of the Devices Included in the Study

Pacing modes	
VI	7
VDD	3
DDD	18
VEV	1
VVED	3
DDED	1
Device manufacturer	
Medtronic	11
Vitatron	7
Biotronik	4
Ela-Sorin	5
Guidant	6
Type of magnetic resonance imaging	
Cardiac	6
Brain	16
Spinal	4
Abdominal	5
Limbs	2

Qualitative data were expressed as percentages and quantitative data as mean (SD). Statistical significance was established at *P*<.05.

RESULTS

No clinical complications were reported. No patient reported pain, heat, discomfort, or sensation of movement of the device during the scan. In all cases, the scan was completed without any technical limitations; 1 case of an artifact was reported in the images obtained, during a cardiac MRI in a patient with a Vitality 2DR (Guidant) PM.

None of the electrical parameters changed significantly during the scan (Table 2).

In the 58 exposed leads, the pacing impedance was measured; the pacing threshold could not be determined in 3 atrial leads because the patient was in atrial fibrillation. In 11 cases (20%), there was a slight variation in the pacing threshold (a slight reduction in all but 3 cases, in which an increased threshold was observed); the largest change recorded was a decrease of 0.5 V in a ventricular device.

Of the 11 leads with a change in their pacing threshold, 5 were ventricular and 6 atrial (*P*=.271). Of the 11 studies in which a change in threshold was observed, 7 were infradiaphragmatic and 4 supradiaphragmatic (*P*=.023).

Detection failures were reported twice, once in an atrial lead and once in a ventricular one (Figures 1

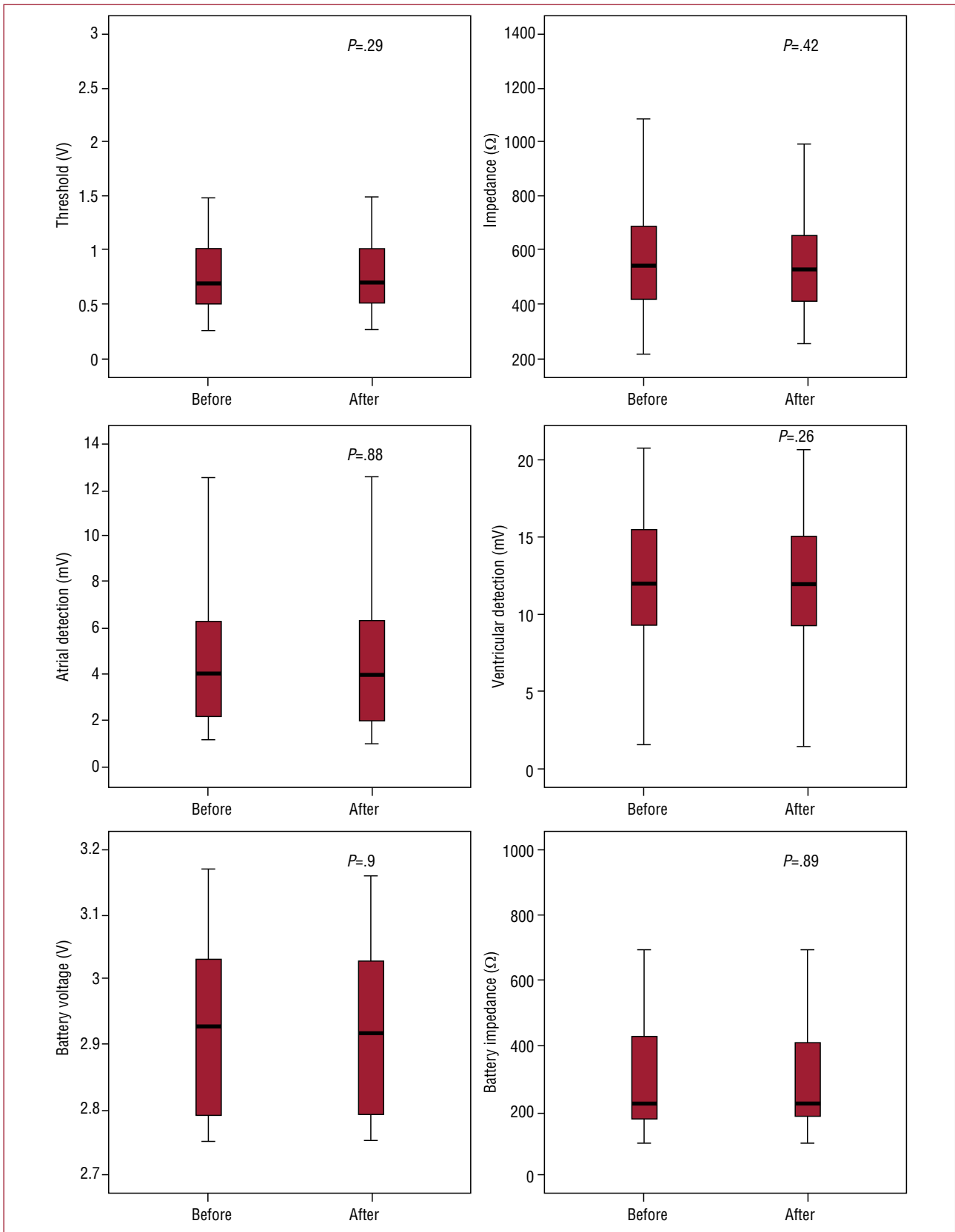


Figure 3. Comparative graphic representation of the electrical parameters detected before and after magnetic resonance imaging. No statistically significant changes were observed.

confirmed, and after the MRI scan the testing could be performed without any complications.

DISCUSSION

We attempted to determine more exactly the risk that MRI scans represent for PM and ICD patients. We present a prospective study of 33 patients, conducted between October 2007 and December 2008. Thus the characteristics of the pacing devices and the MRI apparatus are similar to what is found in everyday clinical practice, although the findings should not be extrapolated to devices of different makes or models.

The devices studied responded safely to the electromagnetic interference caused by the MRI scan. No clinical event or significant change in the electrical parameters analyzed was observed (Figure 3). Likewise, there were no irreversible changes in device function. The events recorded were transient after reprogramming and did not represent any limitation in the operation of the devices or in performing the MRI.

The statistical result suggesting that a change in the pacing threshold is more likely after performing an infradiaphragmatic MRI scan should be interpreted with caution, given the low number of threshold changes detected (11 of 50 leads). Likewise, the low number of scans is a limitation for accurately describing small changes in the parameters analyzed, as well as for characterizing uncommon problems.

Our findings are in line with recently published series,^{10,11} and our conclusion also agrees with the general recommendations available at present.¹² Given that larger prospective studies are lacking, the decision to conduct MRI scans in these patients should be considered on an individual basis. Current data suggest that, with cardiac monitoring and following some basic safety measures, MRI scans can be performed in PM and ICD patients who require such a test for clinical reasons, although it should be highlighted that the absolute safety of MRI scans in these patients cannot be guaranteed.

REFERENCES

1. Marcu CB, Beek AM, van Rossum AC. Clinical applications of cardiovascular magnetic resonance imaging. *CMAJ*. 2006;175:911-7.
2. Kanal E, Borgstede JP, Barkovich AJ, Bell C, Bradley WG, Etheridge S, et al. American College of Radiology White Paper on MR safety: 2004 update and revisions. *AJR Am J Roentgenol*. 2004;182:1111-4.
3. Pohost GM, Blackwell GG, Shellock FG. Safety of patients with medical devices during application of magnetic resonance methods. *Ann N Y Acad Sci*. 1992;649:302-12.
4. Shellock FG, Crues JV III. MR safety and the American College of Radiology White Paper. *AJR Am J Roentgenol*. 2002;178:1349-52.
5. Martin ET, Coman JA, Shellock FG, Pulling CC, Fair R, Jenkins K. Magnetic resonance imaging and cardiac pacemaker safety at 1.5-Tesla. *J Am Coll Cardiol*. 2004;43:1315-24.
6. Gimbel JR, Kanal E, Schwartz KM, Wilkoff BL. Outcome of magnetic resonance imaging (MRI) in selected patients with implantable cardioverter defibrillators (ICDs). *Pacing Clin Electrophysiol*. 2005;28:270-3.
7. del Ojo JL, Moya F, Villalba J, Sanz O, Pavón R, Garcia D, et al. Is magnetic resonance imaging safe in cardiac pacemaker recipients? *Pacing Clin Electrophysiol*. 2005;28:274-8.
8. Sommer T, Naehle CP, Yang A, Zeijlemaker V, Hackenbroch M, Schmiedel A, et al. Strategy for safe performance of extrathoracic magnetic resonance imaging at 1.5 Tesla in the presence of cardiac pacemakers in non-pacemakerdependent patients: a prospective study with 115 examinations. *Circulation*. 2006;114:1285-92.
9. Nazarian S, Roguin A, Zviman MM, Lardo AC, Dickfeld TL, Calkins H, et al. Clinical utility and safety of a protocol for noncardiac and cardiac magnetic resonance imaging of patients with permanent pacemakers and implantable-cardioverter defibrillators at 1.5 tesla. *Circulation*. 2006;114:1277-84.
10. Levine GN, Gomes AS, Arai AE, Bluemke DA, Flamm SD, Kanal E, et al. Safety of magnetic resonance imaging in patients with cardiovascular devices: an American Heart Association scientific statement from the Committee on Diagnostic and Interventional Cardiac Catheterization, Council on Clinical Cardiology, and the Council on Cardiovascular Radiology and Intervention: endorsed by the American College of Cardiology Foundation, the North American Society for Cardiac Imaging, and the Society for Cardiovascular Magnetic Resonance. *Circulation*. 2007;116:2878-91.
11. Roguin A, Schwitler J, Vahlhaus C, Lombardi M, Brugada J, Vardas P, et al. Magnetic resonance imaging in individuals with cardiovascular implantable electronic devices. *Europace*. 2008;10:336-46.
12. Dill T. Contraindications to magnetic resonance imaging: noninvasive imaging. *Heart*. 2008;94:943-8.