

Occlusion of the First Septal Branch With Microcoils in a Patient With Hypertrophic Obstructive Cardiomyopathy

David Rodrigo,^a Pedro M. Montes Orbe,^a Juan Alcívar,^b Javier Fernández,^a Susana Gómez,^a and José I. Barrenetxea^a

^aServicio de Cardiología, Hospital de Cruces, Baracaldo, Vizcaya, Spain ^bSección de Hemodinámica, Hospital de Cruces, Baracaldo, Vizcaya, Spain.

Nonsurgical septal reduction by induced septal infarction is one of the management options in the treatment of patients with hypertrophic obstructive cardiomyopathy. Good immediate and long-term clinical and hemodynamic results have been reported with this technique for occlusion of the first septal branch of the anterior descending coronary artery followed by ethanol infusion. This is the first report of a case in which nonsurgical septal reduction with microcoils has been attempted.

Key words: Ablation. Cardiomyopathy. Infarction. Coils.

Full English text available at: www.revespcardiol.org

INTRODUCTION

In patients with hypertrophic obstructive cardiomyopathy (HOCM) for whom medical treatment has proved ineffective, the non-surgical reduction of the interventricular septum is a therapeutic option that can provide sustained improvement in exercise capacity as well as persistent reduction in the resting and exercising gradients of the left ventricular outflow tract (LVOT).¹ Since Sigwart et al.² described the technique of septal reduction via ethanol ablation of the first septal branch of the anterior descending coronary artery, numerous reports on the success and viability of this therapy have been published.³⁻⁵

Microcoils are devices designed to occlude blood vessels or undesired conduits. They are deployed by catheters (several systems are available), and are effective in occluding both veins and arteries. These

Oclusión con micro-coils de la primera rama septal en el tratamiento de un paciente con miocardiopatía hipertrófica obstructiva

La ablación no quirúrgica del septo mediante la inducción de un infarto septal es una de las alternativas existentes en el tratamiento de la miocardiopatía hipertrófica obstructiva. Se han comunicado buenos resultados clínicos y hemodinámicos con esta técnica, inmediatos y a largo plazo, cuando se emplea la oclusión de la primera rama septal de la coronaria descendente anterior y la posterior infusión de etanol. Éste es el primer caso comunicado en el que se intenta efectuar la ablación no quirúrgica del septo con micro-coils.

Palabras clave: Ablación. Miocardiopatía. Infarto. Coils.

devices have been used successfully to occlude coronary arteries in patients with fistulas at this site.⁶ The literature contains no previous reports of attempts to reduce the LVOT gradient in patients with HOCM by ablation of the first septal branch with microcoils.

CLINICAL CASE

A 64-year-old woman presented with a five-year history of exercise-associated dyspnea but with no cardiovascular risk factors or other medical antecedents of note. The patient was studied in the outpatient clinic, where an electrocardiogram showed sinus rhythm with a frontal plane QRS axis of 10°, signs of left ventricular hypertrophy by voltage criteria (Sokolov 63 mm), and secondary changes in repolarization. No pathological Q waves were found, nor were any changes in conduction rhythm observed.

An echocardiogram showed a non-dilated left ventricle with preserved systolic function (ejection fraction 69%), but severe hypertrophy (septum 20 mm, posterior wall 17 mm). Systolic anterior motion of the mitral valve septal cusp was appreciable. Although it did not make contact with the septum, it

Correspondence: Dr. P.M. Montes Orbe.
Luis Power 2, 1.º C. 48014 Bilbao, Vizcaya, España.
E-mail: pmontes@euslkalnet.net

Received 21 April 2003.
Accepted for publication 10 June 2003.

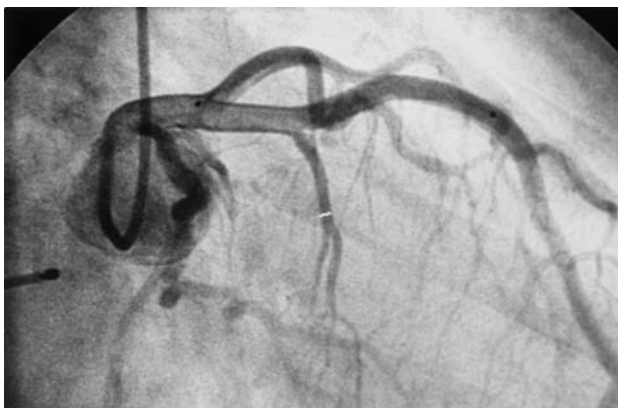


Fig. 1. Cardiac catheterization image showing the first main septal branch arising from the anterior descending coronary artery.

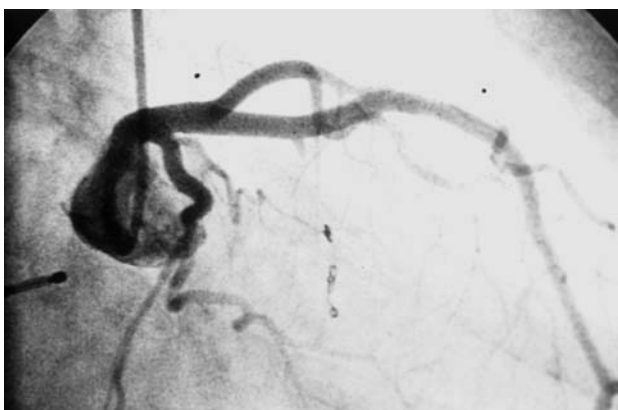


Fig. 2. Cardiac catheterization image showing the complete occlusion of the first main septal branch with microcoils.

caused a subvalvular gradient of 232 mm Hg, and moderate mitral insufficiency was apparent. The Doppler velocity curve was typical of dynamic obstruction. Considering the high speed of the blood flow, special attention was paid to make sure the LVOT velocity spectrum was not distorted by the signal originating from the patient's mitral insufficiency. The pressure in the pulmonary artery was 50 mm Hg. Cardiac nuclear magnetic resonance imaging showed morphological changes consistent with the echocardiographic results. The patient was treated with beta-blockers and with beta-blockers plus calcium antagonists, but no clinical results or significant variation in the subaortic gradient were achieved.

Despite treatment, the patient showed class III-IV functional status and was admitted to hospital, where dual-chamber stimulation was considered. In tests performed in the electrophysiology laboratory, different atrioventricular delays failed to produce any significant variation in the gradient; this therapy was therefore ruled out. The patient was offered surgery

but declined. Non-surgical reduction of the septum by inducing a septal infarction was therefore proposed as an alternative, making it very clear that this was an experimental technique. Because our department has no experience in septal ablation with alcohol, but has ample experience in the use of coils in different situations, the decision was made to close the first septal branch with this technique. During catheterization, a first main septal branch of 1.8 mm was identified with a wide perfusion field in the interventricular septum (Figure 1). A 3-m Anibal guidewire was passed into the septal branch, and via this a 2.3 Fr Microrapid Transit Cordis catheter was introduced, which was placed distally in the septal branch. Via this catheter a thermal system was used to deploy 3 thermo-expandable microcoils (Boston GDF 2 mm 1 cm, 2.5 mm 3 cm, and 2.5 mm 3 cm), achieving complete closure of the vessel (Figure 2). It is noteworthy that the patient showed only a small increase in creatin phosphokinase MB (CPK-MB) (687 IU total CPK [maximum reference value 170 IU] with an MB fraction of 19%). The increase in troponin I was more significant, reaching 14.8 ng/mL (maximum reference value 2.3 ng/mL). Clinically, the patient complained only of slight chest discomfort. No clear changes with respect to the baseline ECG could be observed. However, the LVOT gradient decreased to 113 mm Hg (i.e., by about 50%) after treatment, although no appreciable morphological changes in the septum or its thickness could be seen. The patient was released on beta-blocker treatment but continued to show class III dyspnea. Two months later her LVOT gradient was 186 mm Hg. Eventually, the patient agreed to surgery and a myectomy was performed. One year later, the patient showed class II dyspnea and a subaortic gradient of 32 mm Hg.

DISCUSSION

The non-surgical reduction of the interventricular septum is a potential alternative to surgery for the treatment of HOCM. It provides substantial improvement in symptoms, a notable improvement in exercise capacity, and a reduction in the LVOT gradient. These improvements have been maintained in patients followed over the long-term.^{1,7} Although controlled, randomized studies comparing this still-experimental technique with surgery are required, it would seem to offer an alternative for certain patients with HOCM, especially for those who are unwilling to undergo surgery or for whom comorbidity renders surgery inadvisable.

Following an exhaustive search of the literature, ours would appear to be the only published report of an attempt to induce a septal infarction in a patient with HOCM patient by occlusion of the first septal branch with microcoils. It is noteworthy that no

clinically or enzymatically significant infarction was induced, even though the vessel we treated was an angiographically important (1.8 mm) septal artery, total occlusion was achieved, and there were no other angiographically visible septal or collateral arteries nearby. This may be because the special organization of the myocardium in these patients requires the local abrasive effect of ethanol if permanent necrosis is to be achieved, and the ischemia produced through occlusion of the vessel may not be sufficient to trigger an infarction.

When Sigwart² described the first 3 cases of non-surgical myocardial reduction in HOCM, he noted that hemodynamic effects on the LVOT gradient immediately reverted when the balloon occluding the septal branch was deflated, even after inflations lasting 30 min. In their patient, de la Torre et al⁸ observed no reduction in the gradient until alcohol infusion, even though the artery had been occluded for 20 min. Faber et al,⁵ who measured the variation in the LVOT gradient in 91 patients during balloon occlusion to confirm the target branch before alcohol treatment, reported that simple occlusion led to a decrease in LVOT gradient from 73.8 ± 35.4 to 36.4 ± 29.3 mm Hg—less than that produced by the alcohol infusion (16.6 ± 18.1 mm Hg) but still statistically significant. However, it is not known how the gradient might have changed afterwards if ethanol infusion had not been performed. There are no previous studies of the results that might be achieved through permanent mechanical occlusion of the first septal branch. We used a permanent coronary occlusion method with microcoils, but the procedure did not provide a satisfactory outcome. Though a significant reduction

in the gradient was initially seen, within two months it had returned to the baseline value. These findings suggest that simple mechanical occlusion of the first septal branch is not effective in the treatment of HOCM, and that ethanol is needed to produce the degree of necrosis required for effective hemodynamic results to be achieved.

REFERENCES

1. Shamim W, Yousufuddin M, Wang D, Wang D, Henein M, Seggewiss H, et al. Nonsurgical reduction of the interventricular septum in patients with hypertrophic cardiomyopathy. *N Engl J Med* 2002;347:1326-33.
2. Sigwart U. Non-surgical myocardial reduction for hypertrophic obstructive cardiomyopathy. *Lancet* 1995;346:211-4.
3. Knight C, Kurbaan AS, Seggewiss H, Henein H, Gunning M, Harrington D, et al. Nonsurgical septal reduction for hypertrophic obstructive cardiomyopathy: outcome in the first series of patients. *Circulation* 1997;95:2075-81.
4. Lakkis N, Nagueh S, Kleiman N, Killip D, He Z, Verani M, et al. Echocardiography-guided ethanol septal reduction for hypertrophic obstructive cardiomyopathy. *Circulation* 1998;98:1750-5.
5. Faber I, Seggewiss H, Gleichmann U. Percutaneous transluminal septal myocardial ablation in hypertrophic obstructive cardiomyopathy: results with respect to intraprocedural myocardial contrast echocardiography. *Circulation* 1988;98:2415-21.
6. Perry SB, Rome J, Keane JF. Transcatheter closure of coronary artery fistulas. *J Am Coll Cardiol* 1992;20:205-9.
7. Gietzen FH, Leuner CJ, Raute-Kreisen U, Dellmann A, Hegelmann J, Strunk-Mueller C, et al. Acute and long-term results after transcatheter ablation of septal hypertrophy (TASH). Catheter interventional treatment for hypertrophic obstructive cardiomyopathy. *Eur Heart J* 1999;20:590-3.
8. de la Torre JM, Sánchez N, Riesco F, Ruiz B, Ochoteco A, Zueco J, et al. Inducción del infarto septal como alternativa terapéutica en la miocardiopatía hipertrófica obstructiva: nuevas observaciones a propósito de un caso. *Rev Esp Cardiol* 1999;52:339-42.