

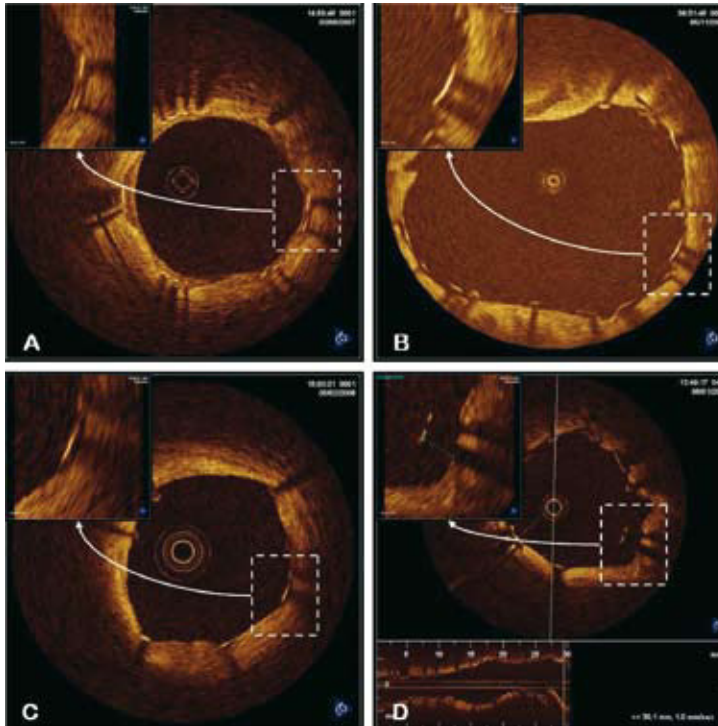Figure 1.

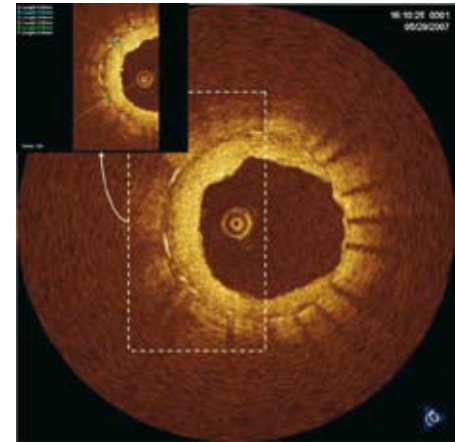


Figure 2.

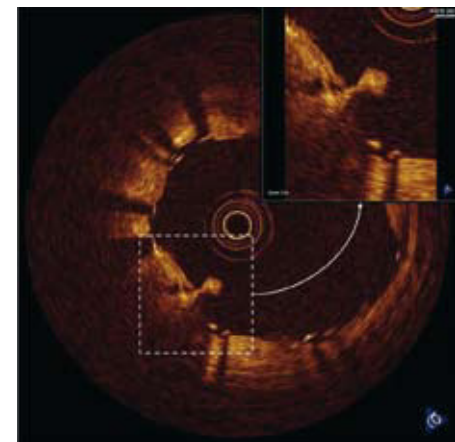


Figure 3.

Optical Coherence Tomography. Ancient Topics, Modern Perspectives

Optical coherence tomography (OCT) is an intracoronary diagnostic technique recently applied in clinical practice that provides high-quality, high-resolution (10-20 μm , compared to 80-120 μm with intracoronary ultrasound) cross-sectional images of the vessels. This technique provides valuable information on the characterization of plaques, the mechanisms implicated in thrombosis or restenosis of coronary stents, and relevant information to improve the results of coronary interventional procedures.

One of the potential mechanisms involved in stent thrombosis is incomplete endothelialization of the surface of the device. The excellent resolution of OCT enables visualization of each of the struts to determine whether they are adequately covered with neointimal tissue (Figure 1A) or not (Figure 1B). This information can be helpful to guide future decisions regarding discontinuation of dual antiplatelet therapy.

Another reported mechanism of thrombosis, inadequate stent apposition, remains a subject of debate. With the use of OCT, it is possible to determine whether apposition of the stent struts to the vessel wall is adequate (Figure 1C) or poor (Figure 1D), the latter being a factor that favors adherence of thrombi and stent thrombosis.

Lastly, depending on the density and uniformity of tissue growth, it is possible to characterize the various components of the atherosclerotic plaque present in as much as 500 μm of the lumen surface (poor penetration), assess the severity and extension of neointimal proliferation in stent restenosis (Figure 2), and identify and locate intraluminal thrombus (Figure 3).

Pablo Aguiar-Souto, Peter Barlis,
and Carlo Di Mario

Department of Cardiology and National Heart
and Lung Institute, Royal Brompton Hospital, Imperial College,
London, United Kingdom