

# Orthotopic Heart Transplantation in Patients With Transposition of the Great Arteries

Christian Muñoz-Guijosa,<sup>a</sup> Antonino Ginel,<sup>a</sup> José Montiel,<sup>a</sup> Vicens Brosa,<sup>b</sup> Sonia Mirabet,<sup>b</sup> Antonio Bayés-Genis,<sup>b</sup> and José M. Padró<sup>a</sup>

<sup>a</sup>Servicio de Cirugía Cardíaca, Unidad de Miocardiopatías, Insuficiencia Cardíaca y Trasplante Cardíaco, Hospital de la Santa Creu y Sant Pau, Barcelona, Spain

<sup>b</sup>Servicio de Cardiología, Unidad de Miocardiopatías, Insuficiencia Cardíaca y Trasplante Cardíaco, Hospital de la Santa Creu y Sant Pau, Barcelona, Spain

Thanks to progress in cardiac surgery and cardiology, pediatric patients with complex congenital heart conditions who would previously have died are now reaching adulthood. Patients with transposition of the great arteries who have undergone atrial repair can present during follow-up with progression towards heart failure as a result of progressive systemic right ventricular failure. In this situation, heart transplantation is a possible therapeutic option. Anatomic abnormalities and the presence of intraatrial conduits ensure that transplantation must involve a number of technical modifications. Here, we present our experience during 1992-2004 with heart transplantations in 4 patients with transposition of the great arteries and atrial repair. There was no operative mortality. During follow-up (mean period, 75 months), there was 1 death due to chronic rejection. The other patients remain in New York Heart Association class I, with normally functioning grafts.

**Key words:** Transplantation. Transposition of the great arteries. Congenital heart disease. Surgery.

## Trasplante cardíaco ortotópico en pacientes con transposición de grandes vasos

Debido a la evolución de la cirugía cardíaca y la cardiología, los pacientes pediátricos que antaño fallecían a causa de cardiopatías congénitas actualmente llegan a la edad adulta. Los pacientes con transposición de grandes vasos y reparación fisiológica en el seguimiento pueden evolucionar hacia la insuficiencia cardíaca, como consecuencia del fallo progresivo del ventrículo derecho en posición sistémica. En esta situación, el trasplante cardíaco aparece como una posible alternativa terapéutica. Las alteraciones anatómicas y la presencia de conductos intraauriculares hacen que el trasplante precise de una serie de variaciones técnicas. Presentamos la experiencia en nuestro centro. Entre 1992 y 2004 se han realizado 4 trasplantes cardíacos en transposición de grandes vasos y corrección fisiológica. No hubo mortalidad quirúrgica. Durante el seguimiento (media, 75 meses), se produjo una muerte por rechazo crónico. Los demás pacientes presentan clase I de la NYHA, con injerto normofuncionante.

**Palabras clave:** Trasplante. Transposición de grandes arterias. Cardiopatías congénitas. Cirugía.

## INTRODUCTION

Progress in cardiac surgery and cardiology has resulted in pediatric patients with congenital heart disease (CHD) who previously would have died now reaching adulthood. In fact, in some countries, the percentage of the adult population with CHD repaired in infancy is already higher than the pediatric population.<sup>1</sup> In patients with transposition of the great arteries (TGA), physiological or intra-atrial repair techniques (Mustard and Senning) have

been used for more than 20 years.<sup>2</sup> Both techniques were described in the late 1960s. Given that the Senning technique can be performed without having to use prosthetic material for redirection of blood flow, this was the most frequently used technique, considering its growth potential. Anatomical correction (Jatene procedure or arterial switch) enables avoiding use of the left ventricle as a systemic ventricle<sup>3</sup> but, as it was developed later on (in the 1970s), there are still many patients who reach adulthood with some variation of intra-atrial repair technique. The majority of these patients are clinically well throughout their adult life, but as a consequence of the potential for right ventricular (systemic) failure, some may develop cardiac insufficiency.<sup>4,5</sup> The poor results obtained with other surgical techniques, such as the late arterial switch,

Correspondence: Dr. C. Muñoz-Guijosa.  
Servicio de Cirugía Cardíaca. Hospital de la Santa Creu y Sant Pau.  
Sant Antoni Maria Claret, 167. 08025 Barcelona. España.  
E-mail: cmunozg@santpau.es

Received March 11, 2008.  
Accepted for publication May 12, 2008.

**TABLE 1. Clinical and Surgical Data**

Patient. Sex	Diagnosis	Previous Surgery	Age at Onset of CCI, y	CT Waiting List, mo	WU	Age	Procedure	Course
1. Woman	D-TGA, IVC	Rashkind, Senning (6 months of age)	13	6	0.26	15	Bicaval CT	PM-VVI Immunosuppressive treatment: cyclosporine, mycophenylate, prednisone. Vascular graft disease diagnosed 5 years after CT. Death 6 years after CT
2. Female	D-TGA	Senning (9 months of age)	11	2	2.99	13	Bicaval CT	PM-VVI Immunosuppressive treatment: tacrolimus, azathioprine, prednisone
3. Female	D-TGA, dextrocardia, IVC, IAC, PS, viscerotrial SI	Mustard (9 months of age)	22	13	2.5	25	Biatrrial CT (maintaining Mustard-type rechanneling)	Immunosuppressive treatment: tacrolimus, mycophenylate, prednisone
4. Male	D-TGA, persistent LSVC	Senning (3 years of age)	15	1	2.8	17	Bicaval CT	PM-DDDR Immunosuppressive treatment: tacrolimus, mycophenylate

CT indicates cardiac transplant; d-TGA, d-transposition of the great vessels; IAC, interatrial communication; IVC, interventricular communication; LSVC, left superior vena cava; PS, pulmonary stenosis; PM, pacemaker; SI, situs inversus.

make heart transplantation a good therapeutic alternative in cases where right ventricular insufficiency develops.<sup>5,6</sup> Previous surgery and alterations in the atrial anatomy give heart transplantation its own peculiarities, sometimes leading to the need for technical variations.

## METHODS

We carried out a descriptive study of 4 patients (3 women, 1 man) with TGA and physiological correction, with end-stage cardiac insufficiency, who underwent heart transplantation between 1992 and 2004. Data collection was by review of the clinical charts (Table); 3 patients had D-TGA and 1 had D-TGA, dextrocardia and viscerotrial situs inversus; 3 patients underwent a Senning-type correction and 1 a Mustard-type correction. None of the patients had pulmonary hypertension. The age range at the time of transplantation was 13-25 years. In 3 cases the implant was performed using the bicaval technique and in 1 case, the classical biatrial technique.

## RESULTS

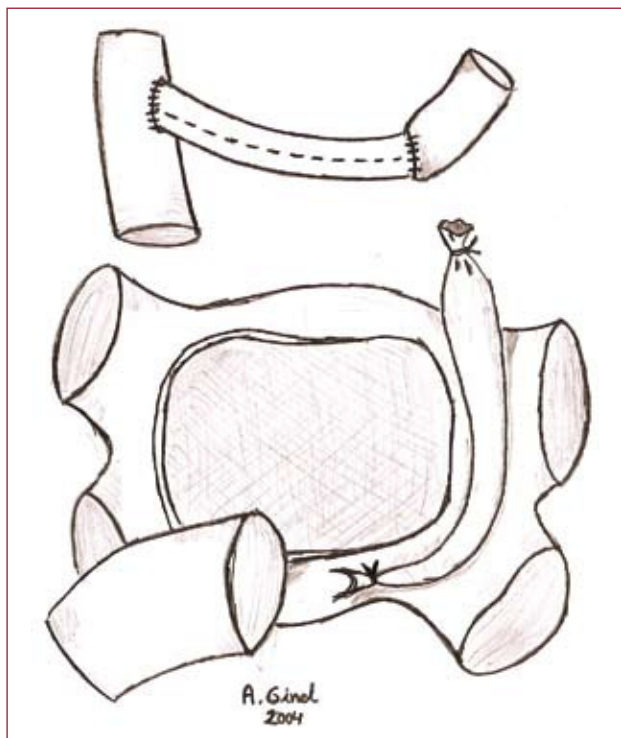
In the patients with Senning repair, redirection of blood flow is achieved through surgical alteration of the interatrial septum and connection of the left atrium (LA), open at the outlet of the right pulmonary veins, with the lateral wall of the right atrium (RA).

This results in the free wall of the RA being, in reality, the free wall of the systemic atrium. The venous cannulation must be carried out keeping this in mind. The superior vena cava (SVC) can be cannulated directly. Drainage of the inferior vena cava (IVC) can be performed by directly accessing it near the diaphragm or through the femoral vein. On initiating the cardiectomy, the first cavity accessed is the systemic atrium. After opening the systemic atrium, the neoseptum is extracted, in order to access the venous atrium. After explanting the septum, both vena cavae are mobilized and sectioned. Finally, the remaining LA is sectioned circumferentially.

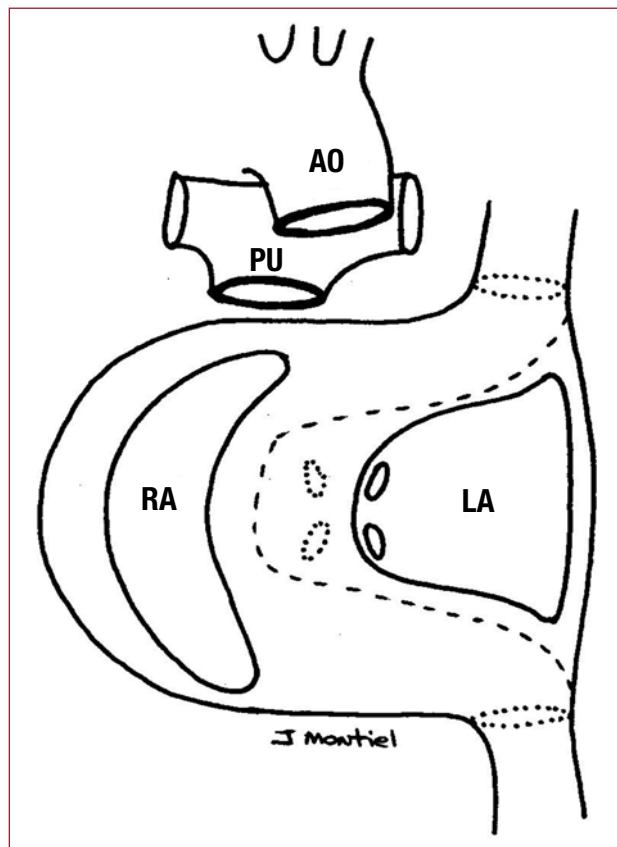
In these 3 cases, the cardiac transplant was carried out using the bicaval technique. In one of these patients there was no innominate vein and the left SVC persisted. During surgery recannulation of the left SVC to the right SVC with a prosthetic conduit was performed (Figure 1).

In the Mustard procedure, venous redirection is achieved by extracting the interatrial septum and creating a tunnel in the interior of the atrium connecting both vena cavae to the mitral valve. Thus, the pulmonary veins drain into the tricuspid valve. During the procedure, venous drainage is achieved through direct cannulation of both vena cavae.

In the patient with D-TGA and dextrocardia, the Mustard-type correction allowed venous blood to flow from the left side toward the right side. The cardiectomy was performed maintaining intra-atrial



**Figure 1.** Representation of the mediastinal structures after cardiectomy. Redirection of flow via prosthetic conduit is shown.



**Figure 2.** Representation of the mediastinal structures after cardiectomy. Mustard-type rechanneling enabled cardiac transplant using the biatrial technique.

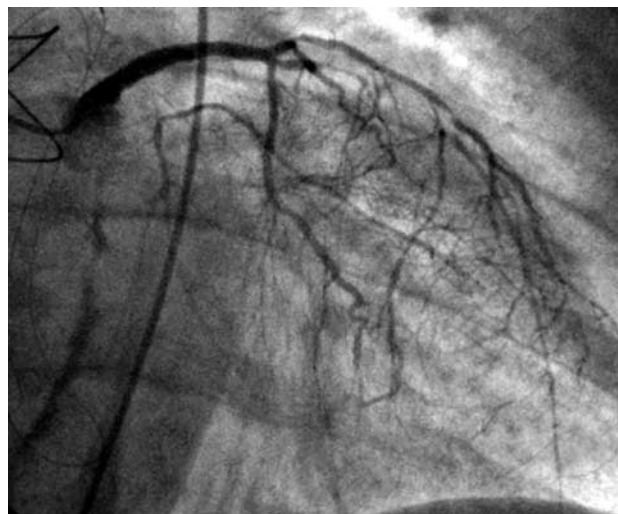
recannulation, in such a way that venous flow remained situated on the right side of the patient (Figure 2). Cardiac transplant was performed using the bicaval technique. During the procedure the donor LA was sutured with the drainage situated on the left, and the donor RA with the drainage situated on the right. With the implant complete, the donor heart was in a position of mesocardia with levoapex.

There were no hospital deaths. One patient died at 6 years post-transplant due to graft vasculopathy (Figure 3). The mean follow-up was 75 months, with the 3 remaining patients in New York Heart Association functional class I and a normally functioning graft.

## DISCUSSION

Great controversy surrounds the long-term progress of patients with TGA who have undergone physiological correction. The incidence of systemic ventricular failure during follow-up is not known with certainty. Certain series present figures of up to 61% ventricular failure at 25 years,<sup>4</sup> while others present lesser values, with up to 85% survival at 32 years.<sup>7,8</sup>

Surgical options for treatment of these patients are limited. Substitution of the tricuspid valve is generally insufficient to avoid functional worsening.



**Figure 3.** Coronary angiogram 5 years after cardiac transplantation.

Another option would be late conversion to a 2-stage arterial switch: banding of the pulmonary artery and later takedown of the intra-atrial repair and arterial switch.<sup>6</sup> At first this technique presented encouraging results. Later studies, with longer follow-up periods,

confirmed that the success rate was lower than 20% in patients older than 12 years of age.<sup>9</sup> The main cause of failure was the inability of the LV to adapt to systemic pressure. Given that the majority of patients who develop ventricular failure are in their 20s or 30s, this technique is not considered a true alternative. Faced with this situation, for patients who progress toward cardiac insufficiency, heart transplantation is an interesting therapeutic option, although its use still cannot be generalized due to limited experience in this group of patients.<sup>9</sup>

Heart transplantation in adult patients with CHD presents its own series of problems: previous surgery, the presence of prosthetic material, and anatomic anomalies are the principal complications. Performing a heart transplant in these situations is facilitated by a series of anatomical constants. The LA is a structure situated in the midline and which receives drainage from the pulmonary veins. The pulmonary artery is a structure situated in the middle mediastinum. The aorta, at its exit from the pericardium, is located anterior and to the right of the pulmonary artery. These anatomic constants enable us to perform a heart transplant in practically any type of CHD.<sup>10</sup> Preparation of venous return is the fundamental element in these situations. Special attention must be paid to patients in whom the Senning technique was employed, as the structure most anterior to the mediastinum is the systemic atrium. Both vena cavae remain in its interior, in a deeper position.

In the case of the patient with situs inversus and dextrocardia, cardiac transplantation of a normal heart is a great challenge. The repositioning of venous drainage is the key to the intervention.<sup>10</sup> Several authors have proposed the possibility of transferring blood from the left to the right via prosthetic conduits.<sup>10,11</sup> In our case, due to the presence of a Mustard-type rechanneling, venous redirection had already been achieved. Cardiectomy was performed preserving this venous redirection, which enabled a cardiac transplant with no great alterations.

Cardiac transplantation in patients with complex CHD may be performed with results similar to those obtained in the normal population. It is essential to be aware of any previous surgery, the resulting anatomy, and the variations specific to each patient, in order to plan each intervention.

## REFERENCES

1. Marelli AJ, Mackie AS, Ionescu-Ittu R, Rahme E, Pilote L. Congenital heart disease in the general population: Changing prevalence and age distribution. *Circulation*. 2007;115:163-72.
2. Oliver JM. Cardiopatías congénitas del adulto: residuos, secuelas y complicaciones de las cardiopatías congénitas operadas en la infancia. *Rev Esp Cardiol*. 2003;56:73-88.
3. Blanch P, Gómez-Hospital JA, Serrano M, Lozano C, Girona J, Casaldáliga J. Seguimiento de la trasposición de grandes arterias corregida con técnica de Senning. *Rev Esp Cardiol*. 1995;48:42-8.
4. Roos-Hesselink JW, Meijboom FJ, Spitaels SEC, van Domburg R, van Rijen EHM, Utens EMWJ, et al. Decline in ventricular function and clinical condition after Mustard repair for transposition of the great arteries (a prospective study of 22-29 years). *Eur Heart J*. 2004;25:1264-70.
5. Sarkar D, Bull C, Yates R, Wright D, Cullen S, Gewillig M, et al. Comparison of long-term outcomes of atrial repair of simple transposition with implications for a late arterial switch strategy. *Circulation*. 1999;100:II-176.
6. Mee RBB. Severe right ventricular failure after Mustard or Senning operation. Two stage repair: pulmonary artery banding and switch. *J Thorac Cardiovasc Surg*. 1986;92:385-90.
7. Puley G, Siu S, Connelly M, Harrison D, Webb G, Williams WG, et al. Arrhythmia and survival in patients >18 years of age after the Mustard procedure for complete transposition of the great arteries. *Am J Cardiol*. 1999;83:1080-4.
8. Gelatt M, Hamilton R, McCrindle B, Connelly M, Davis A, Harris L, et al. Arrhythmia and mortality after the Mustard procedure: a 30 year single center experience. *J Am Coll Cardiol*. 1997;29:194-201.
9. Poirier NC, Yu JH, Brizard C, Mee R. Long term results of left ventricular reconditioning and anatomic correction for systemic right ventricular dysfunction after atrial switch procedures. *J Thorac Cardiovasc Surg*. 2004;127:975-81.
10. Doty D, Renlund DG, Caputo GR, Burton N, Jones KW. Cardiac transplantation in situs inversus. *J Thorac Cardiovasc Surg*. 1990;99:493-9.
11. Rubay JE, D'Udekem Y, Sluysmans T, Ponlot R, Jacquet L, De Leval M. Orthotopic heart transplantation in situs inversus. *Ann Thorac Surg*. 1995;60:460-2.