

Image in cardiology

Out-of-hospital Use of Semiautomated External Defibrillator Electrocardiography

Registro electrocardiográfico de descarga extrahospitalaria de desfibrilador semiautomático

Nekane Murga Eizagaechearria*

Servicio de Cardiología, Hospital de Basurto, Bilbao, Vizcaya, Spain

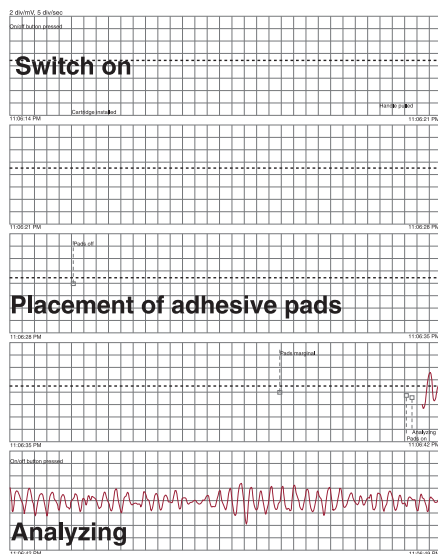


Figure 1.

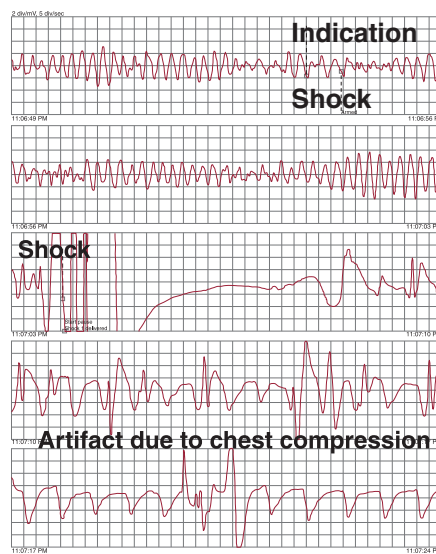


Figure 2.

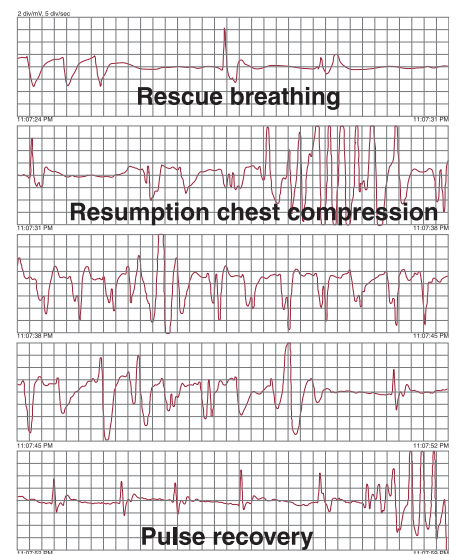


Figure 3.

A 70-year-old man lost consciousness in a public place. The event was witnessed by a health professional trained in cardiopulmonary resuscitation. After confirming that the individual was in cardiorespiratory arrest, he called the emergency services and began basic cardiopulmonary resuscitation. In approximately 3 min, the airport's semiautomatic external defibrillator (AED) (Philips HeartStart, HS1) arrived at the scene.

The images (Figs. 1–3) show the consecutive electrocardiographic recordings of the AED. The delay from the time the device was switched on to shock delivery was 50 s (switch on, pad placement, analysis, recommendation, and confirmation of shock). The device analyzed the electrocardiographic recording during 12 s, at which time the presence of heart rhythm with an indication for shock was confirmed. The shock was then delivered (biphasic 150 J) and was effective. The posterior recording shows artifacts due to resumption of chest compression.

We know that the emergency team arrived at 7 min after the device was turned on. Therefore, in this case, the availability of the AED in a public place enabled the shock to be applied during that time.

The patient's heart rhythm and pulse recovered in less than 1 min after the shock and he regained consciousness. He was taken to hospital, where an absence of neurological sequelae was confirmed, coronary disease was ruled out, and moderate ventricular dysfunction was diagnosed. He currently uses a defibrillator.

* Corresponding author:
E-mail address: nmurga@telefonica.net
Available online 19 October 2011