

Image in cardiology

Paroxysmal Supraventricular Tachycardia Immediately Following Heart Transplantation



Taquicardia supraventricular paroxística inmediatamente tras un trasplante cardiaco

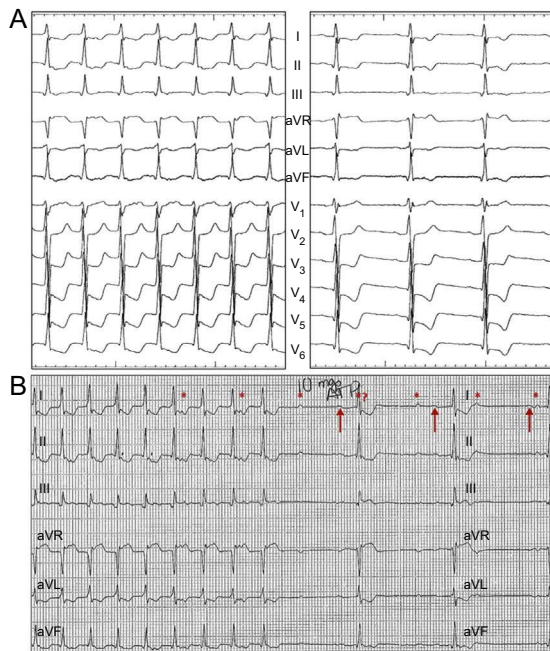
Angel L. Miracle,^a Felipe Atienza,^{b,*} and Francisco Fernández-Avilés^b^a Servicio de Cardiología, Hospital Universitario Rey Juan Carlos, Móstoles, Madrid, Spain^b Servicio de Cardiología, Hospital General Universitario Gregorio Marañón, Madrid, Spain

Figure 1.

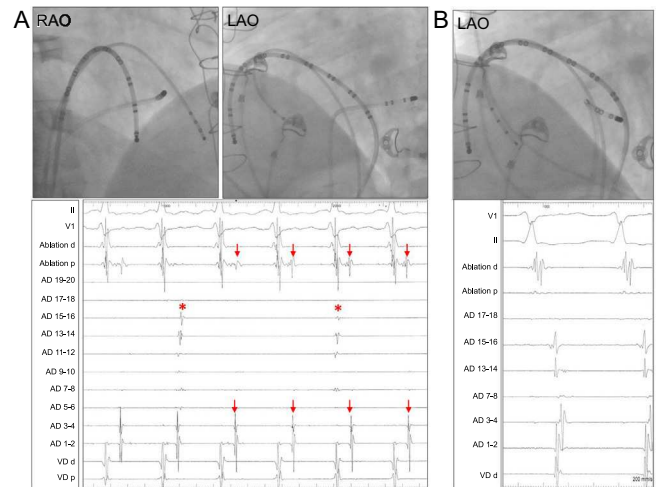


Figure 2.

An electrophysiologic study was performed in a heart transplant recipient with recurrent episodes of paroxysmal supraventricular tachycardia that started shortly after surgery. Electrocardiograms at baseline and during tachycardia (A), as well as the adenosine response (B), are shown in Figure 1. Note culmination with 2 blocked P waves with different morphology and a frequency lower than that of the tachycardia.

Figure 2A depicts the catheter positions in left and right oblique views: a duodecapolar catheter was placed in an anteroposterior position, with the distal dipoles near the tricuspid annulus and the proximal dipoles toward the posteroseptal atrium, a tetrapolar catheter was placed in the right ventricle apex, and another ablation catheter was positioned in the coronary sinus. During tachycardia, a 1:1 atrioventricular conduction ratio (arrows) was seen in the distal duodecapolar dipoles (1-2) and in ablation, whereas dissociated atrial activity (asterisks) was seen in the proximal duodecapolar dipoles (13-14). The diagnostic maneuvers confirmed orthodromic tachycardia mediated by a right posteroseptal accessory pathway, requiring ablation in the coronary sinus ostium (ablation catheter, Figure 2B).

The dissociated atrial activity observed in the intracardiac recordings and surface electrocardiogram, indicated by asterisks in Figures 1 and 2, corresponded to the sinus rhythm of the remnant recipient atrium (transplantation had been performed using the biatrial technique), whereas the arrows indicate the atrial activity of the donor heart. This case illustrates orthodromic tachycardia in a transplanted heart, a situation only sporadically described in the literature, with a singular manifestation on electrocardiography due to the surgical technique used.

* Corresponding author:

E-mail address: fatienza@secardiologia.es (F. Atienza).

Available online 20 March 2014