

Image in cardiology

Percutaneous Closure of an Ascending Aortic Pseudoaneurysm



Cierre percutáneo de pseudoaneurisma de aorta ascendente

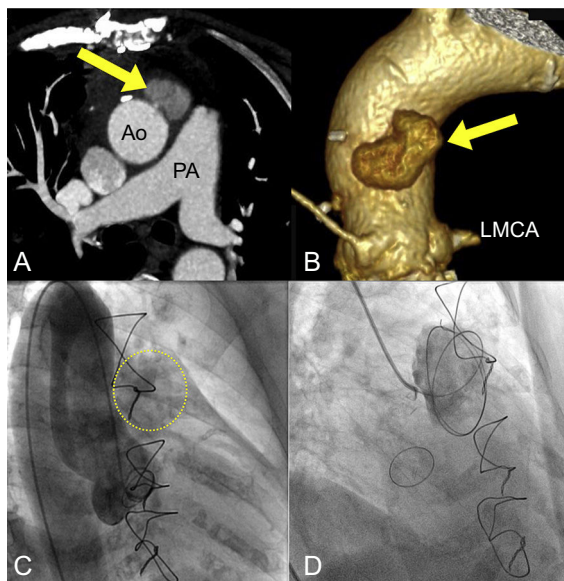
Eulogio García,^a Leire Unzué,^{a,*} and María Soledad Fernández López-Peláez^b^a Unidad de Cardiología Intervencionista, Hospital Universitario Madrid-Montepríncipe, Boadilla del Monte, Madrid, Spain^b Servicio de Radiodiagnóstico, Hospital Universitario Madrid-Montepríncipe, Boadilla del Monte, Madrid, Spain

Figure 1.

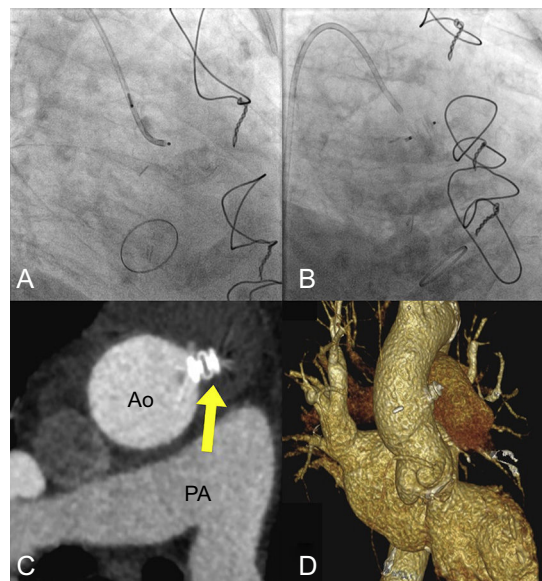


Figure 2.

Pseudoaneurysm of the ascending aorta is a rare but potentially lethal complication arising after interventions involving surgical manipulation of the aorta. The classic therapeutic management strategy consists of high-risk surgical reintervention. In recent years, percutaneous treatment has emerged as an alternative to surgery. Here, we present a case of successful repair of an aortic pseudoaneurysm by percutaneous intervention.

An 81-year-old woman presented with persistent chest pain 3 weeks after surgical replacement of the aortic valve. Thoracic computed tomography revealed a pseudoaneurysm of the ascending aorta measuring 40×27 mm, with a narrow neck connected to the anterior face of the aorta (Ao) above the level of the pulmonary artery (PA) and the left main coronary artery (LMCA) (Figures 1A and B). The case was discussed in a medical-surgical session, and a decision was made to perform percutaneous closure of the pseudoaneurysm. An aortogram showed a rounded cavity connected to the ascending aorta (Figure 1C); a hydrophilic guidewire was advanced into the interior of the cavity until various loops formed (Figure 1D). An 8-mm Amplatzer Vascular Plug II (St. Jude Medical, Inc., St. Paul, Minnesota, United States) was subsequently implanted via a right coronary diagnostic catheter, with a good angiographic result (Figures 2A and B). A postprocedure computed tomography scan showed good positioning of the device, with complete occlusion of the pseudoaneurysm (Figures 2C and D).

* Corresponding author:

E-mail address: leireunzue@yahoo.es (L. Unzué).

Available online 12 June 2015