

# Percutaneous Embolization of Vascular Fistulas Using Coils or Amplatzer Vascular Plugs

Josep Girona,<sup>a</sup> Gerard Martí,<sup>b</sup> Pedro Betrián,<sup>c</sup> Ferrán Gran,<sup>c</sup> and Jaume Casaldàliga<sup>d</sup>

<sup>a</sup>Servicio de Cardiología y Hemodinámica Pediátrica, Àrea del Cor, Hospital Vall d'Hebron, Barcelona, Spain

<sup>b</sup>Servicio de Hemodinámica, Àrea del Cor, Hospital Vall d'Hebron, Barcelona, Spain

<sup>c</sup>Servicio de Cardiología Pediátrica, Àrea del Cor, Hospital Vall d'Hebron, Barcelona, Spain

<sup>d</sup>Unidad de Cardiopatías Congénitas del Adulto, Àrea del Cor, Hospital Vall d'Hebron, Barcelona, Spain

**Introduction and objectives.** A great variety of different types of vascular fistula are referred to cardiac catheterization laboratories for diagnosis and percutaneous occlusion. In addition, a wide range of devices is available for treating them percutaneously. The objectives of this study were to assess the usefulness and difficulty of treating vascular fistulas percutaneously using controlled-release coils or Amplatzer vascular plugs and to report on the complications and overall outcomes observed with these 2 devices.

**Methods.** Retrospective review of percutaneous embolizations performed from January 2004 through June 2008.

**Results.** In total, 51 vascular fistulas in 30 patients aged from 6 days to 28 years (mean, 8.4 years) underwent successful embolization. The underlying diagnoses were: 27 venous collaterals in 16 patients after the Glenn procedure, 4 surgical (ie Blalock-Taussig) fistulas, 11 pulmonary arteriovenous fistulas in 3 patients, 2 aortopulmonary collateral arteries in 2 patients, 1 venous collateral in a patient who underwent the Fontan procedure, 1 aortopulmonary artery fistula in a patient with Scimitar syndrome, 1 coronary arteriovenous fistula, 3 systemic arteriovenous fistulas in a newborn, and 1 fistula from the left atrium to the superior vena cava after the repair of anomalous pulmonary venous return. The lesions were treated percutaneously using 34 vascular plugs and 19 coils.

**Conclusions.** Vascular fistulas can be occluded percutaneously with good results. Small fistulas can be closed using coils, while vascular plugs are preferable for large lesions. Both devices are highly effective as occluders and no particular difficulty or significant complication was observed.

**Key words:** *Congenital heart disease. Fistula. Embolization. Cardiac catheterization.*

## Embolización percutánea de fístulas vasculares con el tapón vascular de Amplatzer o coils

**Introducción y objetivos.** Hay gran variedad de fístulas vasculares que son remitidas a los laboratorios de cateterismo cardíaco para su diagnóstico y oclusión percutánea. Existe también una amplia gama de dispositivos utilizables en su tratamiento percutáneo. El objetivo es evaluar la utilidad, las dificultades, las complicaciones y los resultados en el tratamiento percutáneo de las fístulas vasculares mediante el uso de coils de liberación controlada o tapones vasculares de Amplatzer.

**Métodos.** Revisión retrospectiva de las embolizaciones percutáneas realizadas desde enero de 2004 a junio de 2008.

**Resultados.** Se embolizaron 51 fístulas vasculares en 30 pacientes con edades entre 6 días y 28 años (media, 8,4 años), con buen resultado. Diagnósticos: 27 colaterales venosas en 16 pacientes con Glenn; 4 fístulas quirúrgicas (Blalock-Taussig); 11 fístulas arteriovenosas pulmonares en 3 pacientes; 2 arterias colaterales aortopulmonares en 2 pacientes; 1 colateral venosa en 1 paciente con Fontan previo; 1 arteria aortopulmonar en un síndrome de cimitarra; 1 fístula arteriovenosa coronaria; 3 fístulas arteriovenosas sistémicas en 1 recién nacido, y una fístula entre aurícula izquierda y vena cava superior tras la cirugía de un retorno venoso pulmonar anómalo. En el tratamiento percutáneo de estas lesiones se emplearon 34 tapones vasculares y 19 coils.

**Conclusiones.** Las fístulas vasculares pueden ser ocluidas percutáneamente con buen resultado. Los coils permiten el cierre de fístulas de menor diámetro y los tapones vasculares están indicados en las más amplias. Ambos dispositivos alcanzan una alta eficacia oclusora y no se han observado especiales dificultades ni complicaciones significativas.

**Palabras clave:** *Cardiopatía congénita. Fístula. Embolización. Cateterismo cardíaco.*

Correspondence: Dr. J. Girona.  
Servicio de Cardiología y Hemodinámica Pediátrica.  
Hospital Vall d'Hebron.  
Pg. Vall d'Hebron, 119-129. 08035 Barcelona. España.  
E-mail: jgirona@vhebron.net

Received July 17, 2008.

Accepted for publication March 25, 2009.

**ABBREVIATIONS**

APCA: aortopulmonary collateral artery.  
 AVP: Amplatzer vascular plug.  
 BT: Blalock-Taussig fistula.  
 PAVF: pulmonary arteriovenous fistula.  
 VF: vascular fistula.  
 VVC: veno-venous collaterals.

**INTRODUCTION**

A great range of devices are currently available for the percutaneous closure of vascular fistulas (VF).<sup>1</sup> Out of the wide range of fistulas that can be treated by percutaneous closure, this paper will focus on those found in the context of congenital heart disease and on those that, due to their hemodynamic relevance, are referred to cardiac catheterization laboratories for diagnosis and treatment. On the other hand, among the many devices available, we only focus only on Amplatzer vascular plugs (AVP) (AGA Medical, Golden Valley, Minnesota, USA) and controlled-release coils, since these are the ones more widely used in our setting.

The aim of this work was to retrospectively review the difficulties, complications, and immediate results of 51 embolizations in 30 patients from January 2004 to June 2008.

**METHODS**

From January 2004 to June 2008, 51 percutaneous embolizations were performed in 30 patients aged from 6 days to 28 years (mean age, 8.4 years) (Table 1).

A total of 34 AVPs and 19 coils were used in the percutaneous treatment of these lesions. Controlled-release coils are well-known devices consisting of a metallic coil with fibers attached to increase their occlusive effect. Within the wide range of coils available, we focus on the Flipper Detachable Embolization Coils (Cook Cardiology, Bloomington, Indiana, USA) since these are the ones most frequently used as an alternative to AVP devices in our hospital. They are available with 3, 4, or 5 coils and in 3-mm, 5-mm, 6.5-mm, and 8-mm diameters. They are implanted via 4 Fr catheters using a delivery system attached to the coil by a threaded mechanism.

The use of AVP devices was approved relatively recently (2004). They are self-expanding devices

**TABLE 1. Summary of Patient Characteristics and Devices Used**

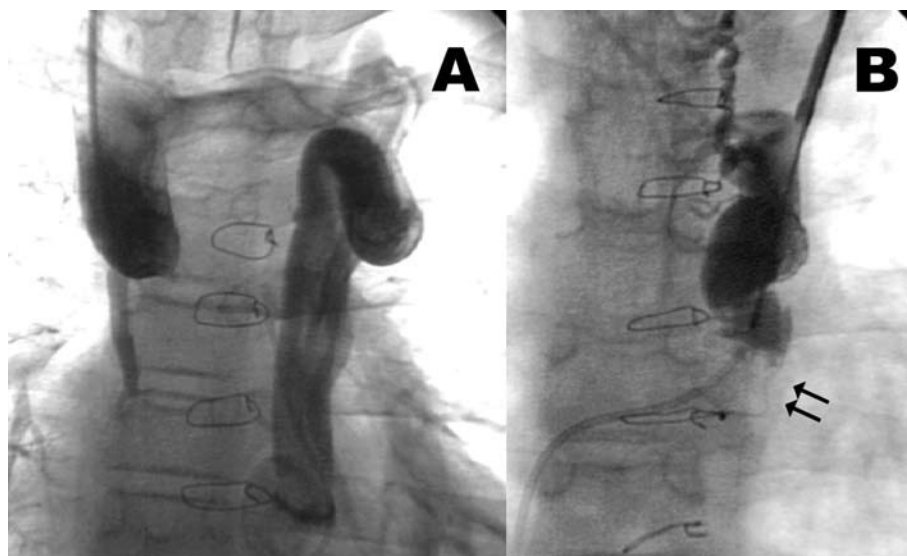
Patient	Age	Diagnosis	Type of Fistula and Diameter	Device, Type, and Diameter	Outcome of Occlusion	Observations
1	7 y, 3 mo	Single ventricle; Glenn procedure	VVC to RA 2 mm	AVP 6 mm	Total occlusion	No variation in initial Hb saturation
2	7 y, 3 mo	Tricuspid atresia; Glenn procedure	VVC to ICV 2 mm	Not possible	–	Increase in Hb saturation from 80% to 85%
3	7 y, 3 mo	Single ventricle; Glenn procedure	VVC to ICV 4 mm	AVP 8 mm	Total occlusion	No variation in initial Hb saturation
			VVC to ICV 6 mm	AVP 12 mm	Partial occlusion	
			VVC to RA 2 mm	AVP 4 mm	Total occlusion	
			VVC to RA 3 mm	2 coils, 3×4 and 5×3	Total occlusion	
4	11 y	Tricuspid atresia; Glenn procedure	VVC to ICV 2 mm	Coil 3×4	Total occlusion	No variation in initial Hb saturation
			VVC to ICV 2 mm	AVP 4 mm	Total occlusion	
			VVC to ICV 2 mm	AVP 6 mm	Total occlusion	
			VVC to ICV 4 mm	AVP 8 mm	Total occlusion	
5	10 y, 2 mo	Tetralogy of Fallot with right ventricular hypoplasia; Glenn procedure	VVC to ICV 12 mm	AVP 16 mm	Total occlusion	Increase in Hb saturation from 90% to 95%
6	8 y, 2 mo	Atrioventricular septal defect with pulmonary atresia; Glenn procedure	VVC to RA 5 mm	AVP 10 mm	Total occlusion	No variation in initial Hb saturation
7	4 y, 4 mo	Single ventricle; Glenn procedure	VVC to ICV 10 mm	AVP 12 mm	Total occlusion	No variation in initial Hb saturation
			VVC to ICV 4 mm	AVP 6 mm	Total occlusion	
8	4 y, 7 mo	Tricuspid atresia; Glenn procedure	VVC to RA 4 mm	AVP 8 mm	Total occlusion	No variation in initial Hb saturation
9	2 y, 3 mo	Single ventricle; Glenn procedure	VVC to ICV 2 mm	Coil 3×5	Total occlusion	No variation in initial Hb saturation
			VVC to ICV 2 mm	AVP 6 mm	Total occlusion	
			VVC to ICV 4 mm	AVP 8 mm	Total occlusion	

(Continues on next page)

**TABLE 1. Summary of Patient Characteristics and Devices Used (continued)**

Patient	Age	Diagnosis	Type of Fistula and Diameter	Device, Type, and Diameter	Outcome of Occlusion	Observations
10	6 y	Single ventricle; Glenn procedure	VVC to RA 3 mm VVC to RA 2 mm	AVP 6 mm Coil 3×4	Total occlusion Total occlusion	No variation in initial Hb saturation
11	7 y, 3 mo	Tricuspid atresia; Glenn procedure	VVC to RA 3 mm VVC to RA 3 mm	AVP 6 mm Coil 3×5	Total occlusion Total occlusion	No variation in initial Hb saturation
12	9 y, 5 mo	Unbalanced atrioventricular septal defect; Glenn procedure	VVC to RA 3 mm VVC to RA 2 mm	2 coils, 3×5 and 5×3 Coil 3×3	Total occlusion Total occlusion	No variation in initial Hb saturation
13	4 y, 4 mo	Unbalanced atrioventricular septal defect; Glenn procedure	VVC to ICV 6 mm	AVP 10 mm	Total occlusion	Increase in Hb saturation from 89% to 92%
14	5 y, 7 mo	Pulmonary atresia with intact septum; Glenn procedure	VVC to RA 2 mm	AVP 6 mm	Total occlusion	No variation in initial Hb saturation
15	12 y	Single ventricle; Glenn procedure	VVC to CS 4 mm	AVP 6 mm	Total occlusion	No variation in initial Hb saturation
16	4 y, 10 mo	Single ventricle; Glenn procedure	VVC to RA 2 mm	Coil 3×3	Total occlusion	No variation in initial Hb saturation
17	10 y, 3 mo	Atrioventricular discordance and arterial ventricle with large interventricular anastomosis and severe lung stenosis; Fontan procedure	VVC to LA 8 mm	AVP 12 mm	Total occlusion	Increase in Hb saturation from 88% to 97%
18	1 y, 10 mo	PAVF in right lower lobe PAVF in left lower lobe with 3 main afferent arteries	PAVF 2 mm PAVF 3 mm PAVF 2 mm PAVF 3 mm	Coil 3×4 Coil 5×5 Coil 3×3 Coil 3×4	Total occlusion Total occlusion Total occlusion Total occlusion	Improvement of clinical cyanosis. Images compatible with multiple peripheral pulmonary microfistulae
19	11 y	PAVF in right lower lobe with 2 main afferent vessels joined into a common one	PAVF 3 mm PAVF 3 mm PAVF 4 mm	Coil 3×4 Coil 3×4 Coil 3×4	Total occlusion Total occlusion Total occlusion	No variation in Hb saturation (98% with patient intubated and 21% FiO <sub>2</sub> )
20	5 y, 5 mo	Large PAVF in right lower lobe with 4 main afferent arteries	PAVF 4 mm PAVF 4 mm PAVF 6 mm PAVF 10 mm	AVP 6 mm AVP 8 mm AVP 10 mm AVP 16 mm	Total occlusion Total occlusion Total occlusion Total occlusion	Increase in Hb saturation from 90% to 100%
21	10 y	Pulmonary valve atresia, valvulotomy, BT fistula	BT 4 mm	Coil 5×5	Total occlusion	
22	1 y, 9 mo	Critical pulmonary valve stenosis, valvulotomy, BT fistula	BT 4 mm	AVP 8 mm	Total occlusion	
23	11 y	Critical pulmonary valve stenosis, valvulotomy, BT fistula	BT 3 mm	AVP 6 mm	Total occlusion	
24	20 y	Fontan procedure, BT fistula	BT 4 mm	AVP 6 mm	Total occlusion	
25	26 y	Tetralogy of Fallot intervened, MAPCA	MAPCA 3-4 mm	AVP 6 mm	Total occlusion	Thoracic pain
26	28 y	Atrioventricular septal defect, pulmonary stenosis and MAPCA	MAPCA 6 mm	AVP 8 mm	Partial occlusion	Thoracic pain
27	8 y	Scimitar syndrome	VF 4 mm	Coil 5×4, AVP 6 mm	Total occlusion	
28	7 y	Coronary arteriovenous fistula	VF 4 mm	AVP 6 mm	Partial occlusion	
29	6 d	Very large fistula arteriovenous in right forearm with 3 main afferent arteries	VF 4 mm VF 5 mm VF 7 mm	AVP 8 mm AVP 10 mm AVP 12 mm	Total occlusion Total occlusion Total occlusion	Newborn
30	1 mo, 10 d	Pulmonary venous return treated VF from superior vena cava to left atrium	VF 2 mm	AVP 6 mm	Total occlusion	Lesion in VF

AVP indicates Amplatzer vascular plug; BT, Blalock-Taussig fistula; CS, coronary sinus; MAPCA, main aorto-pulmonary collateral artery; LA, left atrium; PAVF, pulmonary arteriovenous fistula; RA, right atrium; VF, vascular fistula; VVC, veno-venous collateral.



**Figure 1.** A: large veno-venous collateral in a patient who underwent previous Glenn procedure linking the superior vena cava with the hemizygous vein through the innominate vein. B: the arrows indicate the position of the Amplatzer vascular plug which totally occluded the fistula tract.

made of nitinol mesh. Once expanded, their size ranges from 4 mm to 16 mm and can be delivered by using 5-8 Fr catheters. Deployment is achieved using a wire with a threaded end. The launch of this device had a very positive impact on the percutaneous treatment of VF.<sup>2-4</sup> The greatest advantages are ease and safety of use as well as the wide range of vascular diameters in which they can be deployed. Their main disadvantages refer to the need for relatively large catheters, 5 Fr at least, and the fact that the catheter-release wire set is somewhat rigid and occasionally hinders delivery and deployment.

The type and the size of the device used in each case did not follow a preestablished protocol in this study, although the tendency was to use AVPs in larger fistulas and coils in smaller ones, using in all cases sizes reasonably greater than the diameter of the site to be occluded.

The method used was a retrospective review of the procedures performed, taking into account the type of fistula, diameter, and tract, as well as the type and size of the device, observed difficulties, immediate outcome, and complications. The immediate result was assessed by angiography 10 min after the deployment of the device, and the outcome was considered good (total occlusion) when no or very little contrast medium was observed passing through the AVP mesh.

The Mann-Whitney U test was used to assess VF diameters, as well as the ratio between device diameters and VF diameters.

## RESULTS

Patients undergoing previous Glenn procedure (16): 28 veno-venous collaterals (VVC) with indication for closure and diameters ranging from 2 mm to 12 mm (mean diameter, 3.7 mm). A total

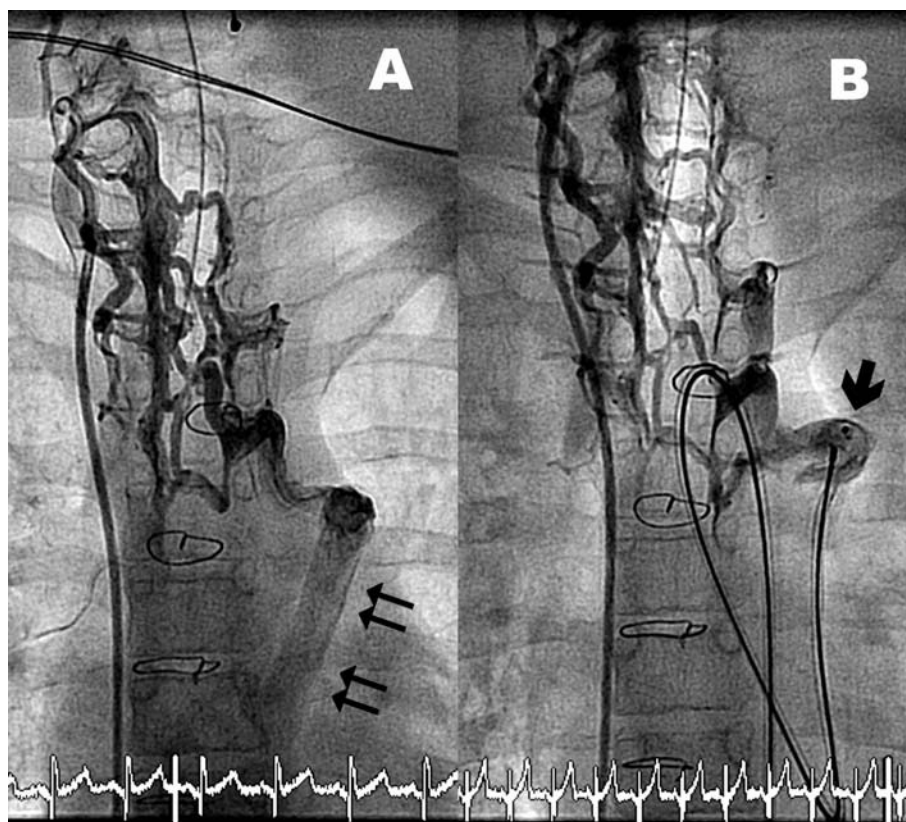
of 19 AVPs with a diameters between 4 mm and 16 mm (mean diameter, 7.8 mm) were used in 19 VVC with diameters between 2 mm and 12 mm (mean, 4.3 mm). The coil/VVC diameter ratio was 1.8. A total of 10 coils were used in 8 VVC (2 VVC required the placement of 2 coils), and 1 VVC could not be occluded due to the extreme tortuosity of its initial tract. Coil diameters were between 3 mm and 5 mm (mean diameter, 3.3 mm) and the VVC diameters were between 2 mm and 3 mm (mean diameter, 2.4 mm), with a diameter ratio of 1.3.

Total occlusion was confirmed by angiography in all cases but 1, where a slight residual shunt was observed after deploying the AVP (Figure 1). No complications were reported.

Patient 17, who had previously undergone Fontan surgery, was referred to cardiac catheterization due to progressive cyanosis. It was found that a VVC drained from the territory of the superior vena cava, through paravertebral veins, to a wide venous collector (8-mm diameter) which drained into the left atrium (Figure 2). Given that it was impossible to reach the venous collector from the superior vena cava, retrograde catheterization was achieved from the femoral artery, passing through the ascending aorta, left ventricle, and left atrium, finally reaching the venous collector. A 12-mm AVP was deployed with excellent angiographic results and the immediate termination of the cyanosis.

Three patients presented pulmonary arteriovenous fistulas (PAVF). Patient 18 presented four afferent arteries with diameters ranging from 2 mm to 3 mm which were treated with 3-mm to 5-mm coils; patient 19 presented three afferent arteries with diameters between 3 mm to 4 mm that were occluded with 3-mm coils. Patient 20 had four large afferent arteries with diameters of 4 mm, 4 mm, 6 mm, and 10 mm that were occluded with 6-mm, 8-mm,





**Figure 2.** A: veno-venous collateral draining from the territory of the superior vena cava, through paravertebral veins, to a wide venous collector (arrows) that emptied into the left atrium in a patient who had previously undergone a Fontan procedure. B: the arrow indicates the location of the Amplatzer vascular plug in the venous collector with total occlusion of the fistula.

10-mm and 16-mm AVPs, respectively. The device/artery diameter ratio was 1.25 when coils were used and 1.7 with AVPs. Total occlusion was achieved in all cases, with strong improvement of cyanosis, and no significant complications.

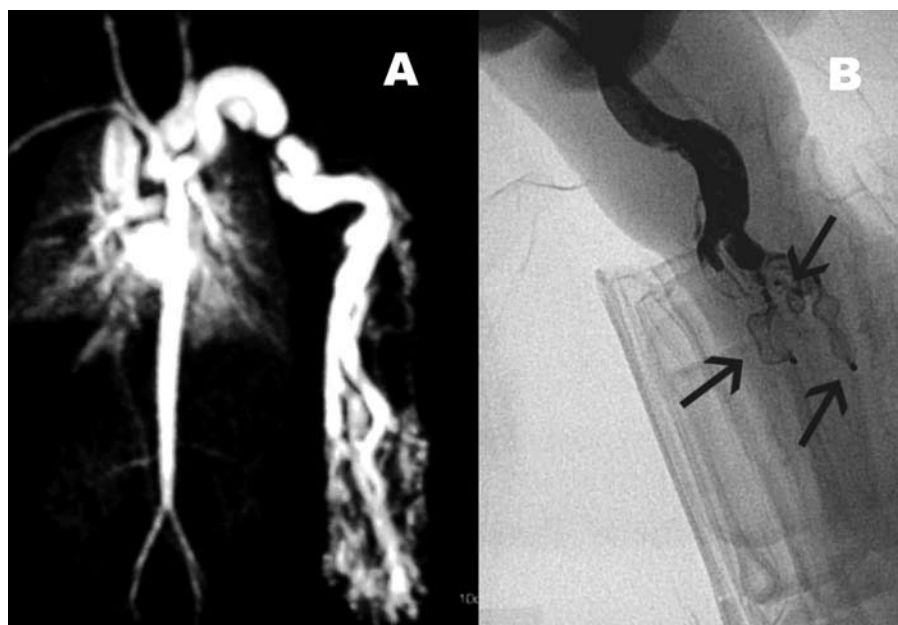
Four patients had previously undergone a Blalock-Taussig shunt procedure. Their underlying heart disease included: critical pulmonary valve stenosis in 2 patients, which required valvulotomy and a Blalock-Taussig (BT) fistula procedure during the neonatal period. The course was favorable and this permitted fistula closure; 1 patient presented pulmonary atresia which followed similar treatment and course; and 1 patient presented pulmonary atresia with right ventricular hypoplasia which, due to technical difficulties during the Fontan procedure, required percutaneous closure of the Blalock-Taussig shunt, which was performed 24 h after surgery.

A BT fistula was occluded successfully with a 5-mm coil via retrograde femoral artery access. In the other 3 cases AVPs were used. In patient 22, arterial retrograde closure with a coil was also attempted, but it was not possible to securely stabilize the delivery device into the fistula due to the acute angle formed between the Goretex tube and the subclavian artery, and thus femoral venous access was attempted. Deployment of an 8-mm AVP was successfully achieved from the pulmonary artery. Patient 23 presented occluded bilateral

femoral venous access, and thus jugular access was employed. The atrium, left ventricle and aorta were reached via an interatrial shunt from which the BT fistula was catheterized. An acute angle between the subclavian artery and the fistula impeded the safe deployment of the coil, and so percutaneous access was gained through the femoral artery and—using a suitable 5 Fr guiding catheter—placement and deployment of the 6-mm AVP was achieved with an excellent outcome. In patient 24, a 6-mm AVP was delivered and deployed via percutaneous access through the right intermediate basilic vein, without difficulty and with a good outcome.

Two patients presented an aortopulmonary collateral artery (APCA) that required occlusion. Patient 26 presented an atrio-ventricular defect and pulmonary stenosis, and the VF was reached by antegrade femoral vein access. It was occluded with no difficulty with an 8-mm AVP, with residual flow 10 min after embolization. In the other patient (number 25), percutaneous femoral artery access was used to deploy a 6-mm AVP, obtaining total occlusion after 10 min. In both cases, previous transient balloon occlusion in the APCA was performed, without decreased hemoglobin saturation being observed, but with reports of occlusion-associated chest pain in both patients.

Patient 27 presented Scimitar syndrome with a 5-mm aortopulmonary fistula. A 5-mm coil was first



**Figure 3.** A: magnetic resonance image of a neonate with a large systemic arteriovenous fistula in the right upper limb. B: the arrows indicate the location of the Amplatzer vascular plugs deployed and their occlusive effect.

deployed, but this underwent distal displacement after release, and thus a 6-mm AVP was inserted leading to successful occlusion.

Patient 28 presented a dilated left coronary artery with several fistula tracts that drained into the coronary sinus through a common 4-mm diameter collector. Given that there was a reasonable doubt concerning the existence of normal coronary venous return (with no fistula), transient balloon occlusion was performed and the ECG and aortic pressure were monitored; a coronary angiography was performed to visualize the coronary venous return. A 6-mm AVP was advanced and deployed through the right jugular vein achieving partial flow occlusion after 10 min.

Patients 29 and 30 were neonates with very rare disorders. One presented a large systemic arteriovenous fistula in the right forearm, with three large afferent arteries of 4-mm, 5-mm, and 7-mm diameter. The neonate had heart failure with cardiogenic shock resistant to medical treatment, only managed by compression in the fistula region, and extreme muscle, skin and subcutaneous tissue dystrophy in the right hand and forearm. Vascular surgeons advised against surgical treatment of the fistula due to tissue dystrophy, and percutaneous embolization was indicated as an alternative to amputation (Figure 3). Reasonable occlusion was obtained with 3 AVPs of 8-mm, 10-mm, and 12-mm diameter, which immediately terminated the heart failure. However, 5 days later, while treating the forearm, a sudden and copious bleeding event took place and the decision was taken to amputate the forearm. The percutaneous procedure was very difficult due to the large difference in size between

the length of the devices needed for the occlusion (introducer guide and release wire) and the upper limbs of neonates.

The other neonate presented moderate breathing difficulties following intervention for anomalous pulmonary venous return, and thus underwent cardiac catheterization when aged 40, and 30 days after the first intervention. An anomalous fistula tract was found between the left atrium and the superior vena cava, through paravertebral connecting veins, with an arteriovenous shunt through them such that embolization was decided on. To ensure the stability of the device in a venous structure connected to the left atrium, an AVP was thought to be a better option than a coil despite requiring an introducer with a greater diameter (5 Fr). While advancing the introducer a lesion occurred in the fistula, which impeded advancing the AVP. However, the patency of the fistula tract was preserved, and a coronary stent implanted (Trimax 2.75×23 mm). This enabled advancing and deploying a 6-mm AVP, which completely occluded the VF with a satisfactory clinical course.

### Relationship of Vascular Fistula Diameter to Occluding Device Diameter

The diameter of the VF ranged between 2 mm and 12 mm, with a mean diameter of 6.7 mm. The diameters of VF occluded with coils ranged between 2 mm and 4 mm (mean diameter, 2.7 mm) and those occluded with AVPs ranged between 2 mm and 12 mm (mean diameter, 4.5 mm). The coils used had a coil diameter ranging from 3 mm to 5 mm (mean diameter, 3.5 mm) and AVP had diameters

**TABLE 2. Relationship Between Device Diameter and Vascular Fistula Diameter**

Device	Coil	AVP	P
VF Diameter (mm), range (mean)	2-4 (2.7)	2-12 (4.5)	<.005
Diameter device (mm), range (average)	3-5 (3.5)	4-12 (8)	NS
Device/VF diameter ratio	1.3	1.8	<.005

AVP indicates Amplatzer vascular plug; VF, vascular fistula.

between 4 mm and 12 mm (mean diameter, 8 mm). The device/VF diameter ratio was 1.3 for coils and 1.8 for AVP. There was a statistically significant difference ( $P<.005$ ) between the diameters of VF occluded with coils and those occluded with AVP, as well as in the device/VF diameter ratio between both devices (Table 2).

## DISCUSSION

There is a great variety of VF—congenital or associated with previous surgical procedures—that require occlusion. Percutaneous embolization is an effective alternative which is less traumatic than surgical closure.

### Indication for Vascular Fistula Closure

In patients who have undergone a Glenn procedure, cardiac catheterization has to be performed before establishing indication for Fontan surgery. This serves to assess pulmonary pressure and resistance, the morphology and diameter of the pulmonary arterial tree, and whether VVC are present.<sup>5</sup>

When VVC are found, the approach depends on their tract and whether a Fontan procedure will be performed or not. When indicated, those VVC draining directly or indirectly into the atrium should be occluded, since they could cause systemic desaturation after surgery. If a Fontan procedure cannot be performed or has to be delayed, every VVC should be occluded because, regardless of their tract, all contribute to systemic desaturation.<sup>6</sup>

For the percutaneous closure of VVC, a great variety of devices are commonly used, including AVP,<sup>7,8</sup> coils,<sup>9,10</sup> and Amplatzer atrial septal occluders.<sup>11</sup> We only used AVPs and coils in the percutaneous closure of 27 VVC in 16 patients who underwent a previous Glenn procedure. Only 1 VVC could not be embolized due to the extreme tortuosity of its initial tract. The angiography performed 10 min after occlusion demonstrated a practically total occlusion in all cases.

Although the aim of this study was not to assess the clinical outcomes of the occlusions, it should be noted that an unquestionable improvement of hemoglobin saturation was observed in only 3 patients with VVC  $\geq 6$  mm (patients 2, 5, and 13). These data

could raise doubts regarding the desirability of occluding small VVC; the only remaining argument in its favor being the need to avoid a future increase in flow due to potential dilation of the VVC. It is worth noting that cyanosis disappeared immediately in the only patient who underwent occlusion of a large VVC that drained into the left atrium, and who had previously undergone a Fontan procedure.

Pulmonary arteriovenous fistulas are anomalous vascular connections between the pulmonary arteries and veins that cause systemic desaturation and cyanosis. Treatment consists of percutaneous embolization.<sup>12</sup> The use of small-diameter devices makes it possible to occlude highly distal areas, with minimal disturbance to healthy vascular structures. However, it has the drawback of requiring the deployment of several devices. On the other hand, large-diameter devices achieve highly effective occlusion with few devices, but this raises the risk of occluding healthy pulmonary artery territories. Thus, in the 3 patients treated for PAVF in this study, coils were chosen when the vascular diameter was small and AVP were chosen for larger diameters. In no case was the deployment of more than one device per fistula necessary; embolized fistulas were totally occluded and there was clear improvement of cyanosis in all 3 patients.

When a Blalock-Taussig shunt has to be occluded, percutaneous embolization is a highly efficient procedure.<sup>13,14</sup> Coils enable the use of smaller-diameter catheters, which is an advantage when using the percutaneous arterial approach, but they fit less tightly to the fistula walls, which is a drawback concerning the risk of embolization. The AVP fit more tightly to the vascular walls, but they require larger catheters. In all cases, total occlusion of the fistula was obtained, with no complications.

Percutaneous embolization is indicated in APCA-type vascular fistulas when they are not required to preserve pulmonary flow in a specific lung area, present the risk of pulmonary hypertension, or when they may cause hemoptysis.<sup>15</sup>

Scimitar syndrome is a pulmonary vascular malformation in which a right pulmonary vein drains into the inferior vena cava and there is a collateral artery from the abdominal aorta toward the affected pulmonary parenchyma. The extent of the anomaly, and the degree of pulmonary



hypoplasia and clinical disorder are variable. It has been demonstrated that percutaneous embolization of the collateral artery provides substantial clinical improvement in these patients and may prevent or delay surgery.<sup>16</sup>

Coronary arteriovenous fistulas with indication for occlusion can be treated surgically or by percutaneous embolization.<sup>17-19</sup> In most cases, coils are used, although in patient 28 (who had a VF) the presence of a common collector of around 4 mm led to the use of an AVP to avoid the use of several coils and reduce the risk of embolization.

The 2 remaining patients in the series were two neonates with different and rare disorders. One presented a large systemic arteriovenous fistula in the right forearm. Large systemic arteriovenous fistulas in the limbs of newborns are difficult to treat surgically, and thus percutaneous embolization was attempted.<sup>20,21</sup> In the other neonate, the use of coils—which are easier to implant from a technical point of view—was rejected due to the risk of embolization to the left atrium, and so an AVP was used.

### Type of Device Indicated

Using coils rather than AVP in smaller VF is consistent with the tendency to employ AVP in larger vessels and coils in small vessels, since the structure and size of the devices encourage this. The small device/VF diameter ratio of coils, compared to AVP, restricts their range of use, given that a larger size coil does not allow proper deployment after release, and thus would lose its occlusive capacity. On the other hand, large AVPs are well adapted to the vascular structure, maintain their occlusive capacity, and adapt themselves, by expansion, to potential dilatation of the VF over time.

### Complications and Difficulties in Device Advancement and Deployment

In general, there were few procedural complications, and the technical difficulties encountered were attributed to extremely tortuous tracts or highly acute angles. The 2 patients in the study who underwent APCA embolization presented chest pain that required analgesic treatment; this was maintained in one of them for 1 week. In one of the neonates, a VF lesion occurred which was satisfactorily resolved. The other neonate presented large arteriovenous fistulas in the right upper limb. This was a very special case due to the extreme technical difficulty involved and the severity of tissue and muscle dystrophy in the limb.

No complication related to vascular access occurred during the procedure or before discharge, neither was long-term antiplatelet therapy required.

### Immediate Outcome of Occlusion

In all cases, angiography was performed to verify the occlusive effect of the device. A practically total occlusion was obtained in all cases but 2: in the coronary fistula and in the APCA of patient 26.

### CONCLUSIONS

Vascular fistulas can be effectively occluded through the percutaneous delivery of coils or AVP devices.

The AVP are available in larger diameters than coils, and so the former are particularly indicated in fistulas with larger diameters. However, the greater rigidity of the AVP delivery system compared to coils can be a drawback in some cases. Both devices provide highly effective occlusion and no particular difficulties or significant complications have been observed.

### REFERENCES

- Walsh KP. Advanced embolization techniques. *Pediatr Cardiol.* 2005;26:275-88.
- Hijazi ZM. New device for percutaneous closure of aortopulmonary collaterals. *Catheter Cardiovasc Interv.* 2004;63:482-5.
- Hares DL, Tometzki AJ, Martin R. Use of the Amplatzer vascular occluder to occlude large venous vessels in adults and children with congenital heart disease: a case series. *Catheter Cardiovasc Interv.* 2007;69:33-9.
- Hill SL, Hijazi ZM, Hellenbrand WE, Cheatham JP. Evaluation of the AMPLATZER vascular plug for embolization of peripheral vascular malformations associated with congenital heart disease. *Catheter Cardiovasc Interv.* 2006;67:113-9.
- Nakanishi T. Cardiac catheterization is necessary before bidirectional Glenn and Fontan procedures in single ventricle physiology. *Pediatr Cardiol.* 2005;26:159-61.
- Fernández Pineda L, Cazzaniga M, Villagrà F, Díez Balda JI, Daghero F, Herraiz Sarachaga I, et al. La operación de Glenn bidireccional en 100 casos con cardiopatías congénitas complejas: factores determinantes del resultado quirúrgico. *Rev Esp Cardiol.* 2001;54:1061-74.
- Rothman A, Acherman RJ, Luna CF, Restrepo H. Enlarged left vitelline vein remnant as a cause of cyanosis after the Fontan procedure: resolution with an Amplatzer vascular plug. *Pediatr Cardiol.* 2006;27:381-4.
- de Groote K, Verhaaren H, Suys B, de Wolf D. Percutaneous closure by a vascular plug of a fistula between the superior caval vein and the left atrium. *Pediatr Cardiol.* 2005;26:675-6.
- Recto MR, Elbl F, Austin E. Transcatheter closure of large persistent left superior vena cava causing cyanosis in two patients post-Fontan operation utilizing the Gianturco Grifka vascular occlusion device. *Catheter Cardiovasc Interv.* 2001;53:398-404.
- Alcibar J, Gómez S, Vitoria Y, Jiménez A, Peña N, Oñate A, et al. Oclusión de la vena levoatriocardinal con coils de Gianturco tras la cirugía de Fontan. *Rev Esp Cardiol.* 1999;52:733-6.
- Guérin P, Losay J, Baron O. Transcatheter occlusion of an intrahepatic venovenous fistula after modified Fontan circulation by implantation of an Amplatzer atrial septal occluder. *Catheter Cardiovasc Interv.* 2005;64:117-20.



12. Uthaman B, Al-Qbandi M, Abushaban L, Rathinasamy J. Transcatheter closure of large pulmonary arteriovenous fistula including pulmonary artery to left atrial fistula with Amplatzer septal occluder. *Catheter Cardiovasc Interv.* 2007;70:422-8.
13. Sivakumar K, Krishnan P, Pieris R, Francis E. Hybrid approach to surgical correction of tetralogy of Fallot in all patients with functioning Blalock-Taussig shunts. *Catheter Cardiovasc Interv.* 2007;70:256-64.
14. Benito Bartolomé F, Prada Martínez F, Sánchez Fernández-Bernal C. Cierre de la fistula de Blalock-Taussig con dispositivo de Amplatzer tras la operación de Fontan. *Rev Esp Cardiol.* 2003;56:826-7.
15. Tissot C, da Cruz E, Beghetti M, Aggoun Y. Successful use of a new Amplatzer vascular plug for percutaneous closure of a large aortopulmonary collateral artery in a pulmonary atresia with ventricular septal defect prior to complete repair. *Int J Cardiol.* 2007;116:e39-41.
16. Uthaman B, Abushaban L, Al-Qbandi M, Rathinasamy J. The impact of interruption of anomalous systemic arterial supply on scimitar syndrome presenting during infancy. *Catheter Cardiovasc Interv.* 2008;71:671-8.
17. Iborra Cuevas C, Sánchez-Recalde A, Roca Pereda L, Moreno R. Cierre percutáneo por acceso radial de una fistula compleja desde la arteria coronaria derecha a la arteria pulmonar con micro-coils. *Rev Esp Cardiol.* 2008;61:101-2.
18. Abdelmoneim SS, Mookadam F, Moustafa S, Zehr KJ, Mookadam M, Maalouf JF, et al. Coronary artery fistula: single-center experience spanning 17 years. *J Interv Cardiol.* 2007;20:265-74.
19. Mavroudis C, Backer CL, Rocchini AP, Muster AJ, Gevitz M. Coronary artery fistulas in infants and children: a surgical review and discussion of coil embolization. *Ann Thorac Surg.* 1997;63:1235-42.
20. Hamilton MC, Occlshaw CJ, Calder AL. Congenital arteriovenous fistula between an intercostal artery and the left brachiocephalic vein. *Cardiol Young.* 2005;15:437-8.
21. Evans K, Jones TK, Johnston TA. Novel use of the Amplatzer duct occluder for percutaneous closure of a large subclavian artery to innominate vein fistula in a neonate. *Congenit Heart Dis.* 2006;1:46-9.