

## Images in cardiology

## Percutaneous Treatment of a Coronary-subclavian Steal Syndrome



## Tratamiento percutáneo de un síndrome de robo coronario-subclavio

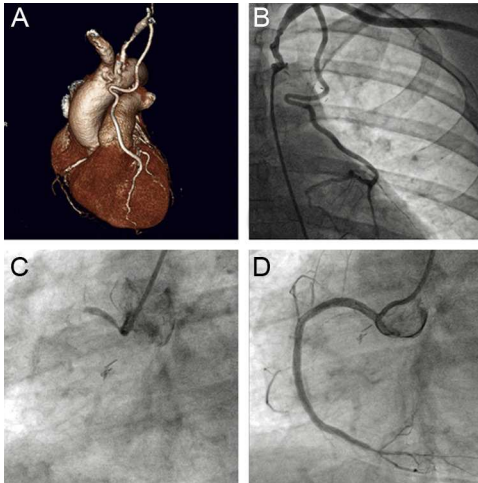
Leire Unzué,<sup>a,\*</sup> Eulogio García,<sup>a</sup> and José Juan Gómez de Diego<sup>b</sup><sup>a</sup> Servicio de Cardiología, Hospital Universitario Madrid-Montepríncipe, Madrid, Spain<sup>b</sup> Servicio de Cardiología, Hospital Universitario Madrid Norte-Sanchinarro, Madrid, Spain

Figure 1.

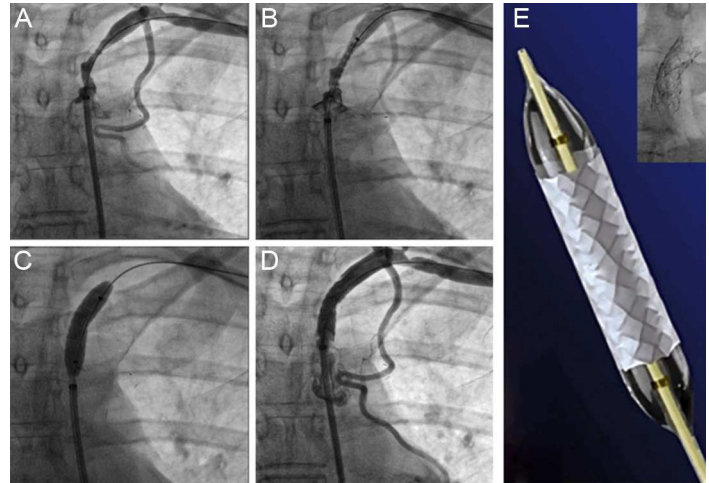


Figure 2.

We present an unusual case of coronary-subclavian steal syndrome, in the context of chronic total occlusion of native left and right coronary arteries that threatened global myocardial blood flow.

The patient was a 55-year-old woman, a smoker, who presented with hypertension, obesity, and dyslipidemia. She was attended at the hospital because of progressive angina and anteroinferior ischemia, discovered in an isotopic study. Nine years earlier, she had undergone surgical revascularization with a left mammary artery (LMA) grafted to anterior descending artery to treat left main coronary artery disease. On this occasion, coronary computed tomography angiography revealed stenosis of the left subclavian artery proximal to the origin of the LMA, which remained patent (Figure 1A). Coronary angiography confirmed the presence of a marked change in the left subclavian artery, with slowed blood flow to the LMA, which retrogradely filled the anterior descending and circumflex arteries to the level of the distal left main coronary artery (Figure 1B and video 1 of the supplementary material). Injections into the native arterial tree revealed total occlusion of the left main coronary artery with chronic total occlusion of the proximal right coronary artery (Figure 1C). Right coronary angioplasty involving placement of 3 overlapping drug-eluting stents (Figure 1D) was performed in the same procedure, with delayed management of the subclavian artery, which was treated by placement of a 7 mm × 22 mm Advanta (Atrium) polytetrafluoroethylene (PTFE)-covered stent at 14 atm (Figures 2A-C; video 2 of the supplementary material). The angiographic outcome was good and there was significant improvement in blood flow to the LMA (Figure 2D; video 3 of the supplementary material). The patient remained asymptomatic 12 months after the procedure.

Percutaneous treatment of coronary-subclavian steal syndrome is an effective and safe therapeutic option that avoids the risks of reintervention.

## SUPPLEMENTARY MATERIAL



Supplementary material associated with this article can be found in the online version available at [doi:10.1016/j.rec.2014.02.023](https://doi.org/10.1016/j.rec.2014.02.023).

\* Corresponding author:  
E-mail address: [leireunzue@yahoo.es](mailto:leireunzue@yahoo.es) (L. Unzué).  
Available online 10 July 2014