

IRMA-2¹) tended to present a less favorable RR in patients receiving ARB-II, there was no evidence of significant heterogeneity. Sensitivity analysis was concordant and we found no publication bias.

The unexpected ROADMAP study⁵ findings on increased cardiovascular-cause mortality in patients receiving olmesartan conflicts with recent trials, principally, the ONGoing Telmisartan Alone and in combination with Ramipril Global Endpoint Trial (ONTARGET)⁶ that included 9612 patients with diabetes and reported telmisartan had a beneficial effect similar to that of ramipril—which had previously been shown to reduce myocardial infarction and mortality. It has been argued that some of the excess events occurred in patients with previous ischemic heart disease and in patients in whom olmesartan induced a minimum hypotensive effect or a substantial reduction in blood pressure, raising once more the controversial “J curve” issue with respect to mortality and ischemic heart disease.^{5,6}

We conclude that although previous studies have adequately shown that ARB-II use slows kidney disease in a range of patients with type 2 diabetes with different degrees of vascular disease, the present meta-analysis shows no benefits but nor does it show any harm to patients' global survival. Further studies will need to determine whether the conflictive ROADMAP study⁵ results are a cause for concern because they reflect a specific effect of olmesartan—which cannot be discounted—or simply a chance finding. This raises the interesting question as to whether microalbuminuria remains a good intermediate variable to predict cardiovascular outcomes.

Luciano Consuegra-Sánchez,^{a,*} Juan Sanchis,^b Julio Núñez,^b José Domingo Cascón,^a Manuel Villegas,^a and Francisco Picó^a

^aServicio de Cardiología, Hospital Universitario del Rosell, Cartagena, Murcia, Spain

^bServicio de Cardiología, Hospital Clínico de Valencia, Valencia, Spain

*Corresponding author:

E-mail address: lconsue@gmail.com (L. Consuegra-Sánchez).

Available online 12 August 2011

REFERENCES

1. Parving HH, Lehnert H, Bröchner-Mortensen J, Gomis R, Andersen S, Arner P. The effect of irbesartan on the development of diabetic nephropathy in patients with type 2 diabetes. *N Engl J Med*. 2001;345:870–8.
2. Brenner BM, Cooper ME, De Zeeuw D, Keane WF, Mitch WE, Parving HH, et al. Effects of losartan on renal and cardiovascular outcomes in patients with type 2 diabetes and nephropathy. *N Engl J Med*. 2001;345:861–9.
3. Lewis EJ, Hunsicker LG, Clarke WR, Berl T, Pohl MA, Lewis JB, et al. Renoprotective effect of the angiotensin-receptor antagonist irbesartan in patients with nephropathy due to type 2 diabetes. *N Engl J Med*. 2001;345:851–60.
4. Bilous R, Chaturvedi N, Sjølie AK, Fuller J, Klein R, Orchard T, et al. Effect of candesartan on microalbuminuria and albumin excretion rate in diabetes: three randomized trials. *Ann Intern Med*. 2009;151:11–20.
5. Haller H, Ito S, Izzo Jr JL, Januszewicz A, Katayama S, Menne J, et al. Olmesartan for the delay or prevention of microalbuminuria in type 2 diabetes. *N Engl J Med*. 2011;364:907–17.
6. Cordero A, Fácila L, Galve E, Mazón P. Progresos en hipertensión y diabetes mellitus. *Rev Esp Cardiol*. 2010;63:101–15.

doi: 10.1016/j.rec.2011.05.028

Phenotypic Variability in Marfan Syndrome in a Family With a Novel Nonsense *FBN1* Gene Mutation

Variabilidad fenotípica del síndrome de Marfan en una familia con una nueva mutación en el gen *FBN1*

To the Editor,

We present a family in which four members were diagnosed by molecular testing as having the Marfan syndrome (MFS), with a highly variable expression. The proband is a 30-year-old man in whom a mild dilatation of the aortic root was detected at the age of 12 years. He underwent cataract surgery when he was 13 and, when he was found to have lens subluxation at the age of 18, he was diagnosed with MFS. At the present time, he is totally blind in his right eye and has scoliosis, arachnodactyly and recurrent patellar dislocation. The diameter of the aortic root is presently 41 mm.

The patient and his partner came to the genetics unit seeking genetic counseling with regard to future offspring. He explained that he had four healthy sisters, that he was the only member of his family with MFS, and that there was no family history of aortic disease or sudden death at a young age. After receiving an explanation of the mode of inheritance—autosomal dominant—and a description of the reproductive options, they were offered prenatal or preimplantation diagnosis once the mutation responsible for the disease had been identified. They were also informed that more than 90% of the patients with MFS may have an *FBN1* gene mutation. We discussed with the couple the limitations to predict the severity of the disease, given that the clinical spectrum ranges from mild bone and joint involvement to severe neonatal forms with fatal cardiovascular disease. After adequate informed

consent, we proceeded to *FBN1* gene sequencing using DNA extracted from peripheral blood. In this study, we detected four single nucleotide polymorphisms (SNP) included in the SNP database (in Entrez databases): rs1018148 (IVS2–102T>C), rs59966849 (IVS28+47–/CATAA), rs2303502 (IVS48+54T>A) and rs363832 (IVS56+17G>C). In addition, we detected two intronic variants not described in the polymorphism databases and, thus, of uncertain significance (IVS25+49delTAAAGA and IVS40–35C>T). In the coding sequences, we identified a heterozygous point mutation in exon 54: E2194X (c.6580G>T) (Fig. 1). It was a premature termination codon (as are 33% of the mutations of this gene) that had not been previously described. This mutation presumably causes the disease as it produces the truncation and loss of 24% of the fibrillin 1, which affects 11 epidermal growth

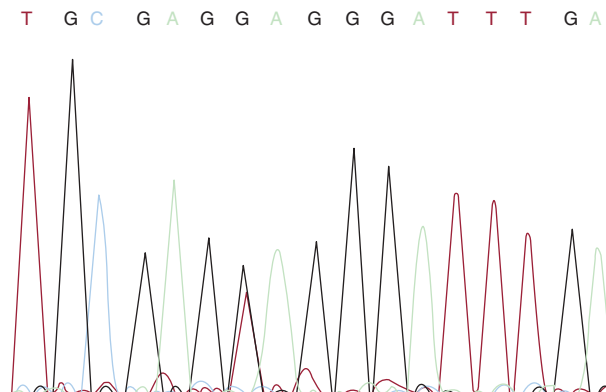


Figure 1. c.6580G>T mutation.

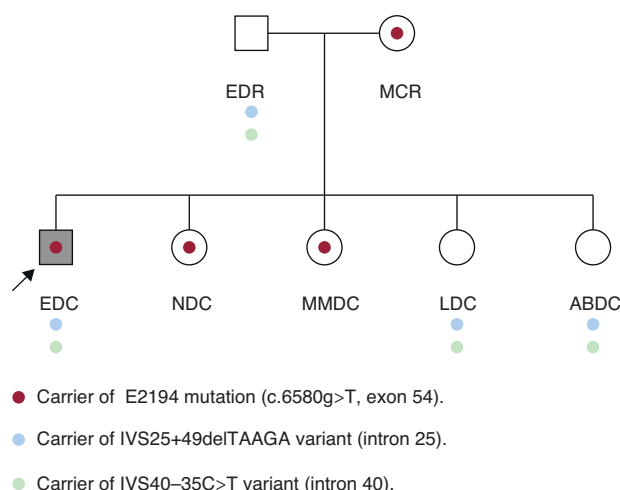


Figure 2. Family tree.

factor-like domains. It would be a potentially pathogenic nonsense mutation, according to the revised Ghent criteria. The mutation is located in exon 54, in the 3' region, where 37% of the mutations of *FBN1* have been described.

Initially, we studied the presence of the mutation and of the two uncertain variants in the parents of the patient, with the unexpected detection of the same mutation in his mother, who was apparently healthy. In his father (age: 53 years; height: 169 cm), who had a normal physical examination, electrocardiogram and echocardiogram, we detected two variants of uncertain significance. The examination of his mother (age: 50 years; height: 160 cm) revealed marked kyphoscoliosis, abdominal hypotonia and dural ectasia in the magnetic resonance (MR) study. The results of the ophthalmologic examination and transthoracic echocardiogram were normal. Subsequently, his four sisters underwent a molecular study and physical examination. In two of them (NDC and MMDC), the same pathogenic mutation was detected, and in the other two (LDC and ABDC), only the two variants of uncertain significance were observed (Fig. 2). In the examination of NDC (age: 23 years; height: 172 cm), we detected *pectus carinatum*, arachnodactyly, positive thumb and wrist signs and marked hyperlaxity. Magnetic resonance imaging demonstrated mild scoliosis, as well as dural ectasia at the lumbosacral level. The results of the ophthalmologic examination and echocardiogram were normal. The other three healthy sisters refused to undergo the examination, although MMDC, a carrier of the mutation, had scoliosis.

Unexpectedly, the molecular analysis enabled us to identify three healthy relatives in whom the correct diagnosis had been overlooked for years.

The findings in this family lead us to several conclusions: a) the genetic study should commence with the most severely affected patients and, if a causative mutation is detected, should be continued with relatives; b) taking into account the morbidity and mortality rates in patients with MFS, early diagnosis is important so that appropriate medical and surgical management can be undertaken;¹ the recently revised international consensus guidelines for diagnostic criteria² are valuable for this purpose and, in cases of minimal expression, the genetic diagnosis may not change

the clinical management a great deal, but it will permit reproductive options and aid in the evaluation of other relatives;³ c) the molecular study in relatives, *a priori* with a 50% risk of being affected, makes it possible to identify those with a predisposition to the disease and, moreover, results in a savings in periodical checkups in the case they do not have the mutation; d) MR enables the identification of dural ectasia, present in 90% of the patients with MFS, with a high diagnostic specificity, as has been pointed out in the revision of the Ghent criteria;² e) special care should be taken in the transmission of the information since, in some cases, the situation is similar to that of the predictive analyses; f) with respect to the variability in expression, Van Dijk et al.⁴ pointed out that additional trans-acting mutations in *FBN1* could play a role as modifiers that would explain the intrafamilial variability; our findings could strengthen this hypothesis since we detected two variants that, when they accompany the mutation, are associated with a more severe phenotype, and that may play a role as modifiers of the phenotype; g) as Comeglio et al. have pointed out,⁵ it is essential that the scientific community identify the largest possible number of mutations in order to further clarify the causative or modifying effects of similar mutations, a circumstance that would aid in genetic counseling, to define the probable diagnosis and to control decisions made in patient management; and h) if genetic studies are not available, clinical evaluation of relatives is indispensable after a diagnosis of hereditary heart disease in a proband.

Aránzazu Díaz de Bustamante,^{a,*} Eva Ruiz-Casares,^b
 M. Teresa Darnaude,^a Teresa Perucho,^b
 and Gabriel Martínez-Quesada^c

^aUnidad de Genética, Hospital Universitario de Móstoles, Madrid, Spain

^bLaboratorio de Genética, Genyca Innova, Majadahonda, Madrid, Spain

^cServicio de Medicina Interna, Hospital Universitario de Móstoles, Móstoles, Madrid, Spain

* Corresponding author:

E-mail addresses: arandiazbus@yahoo.es,
adiazb.html@salud.madrid.org (A. Díaz De Bustamante).

Available online 12 August 2011

REFERENCES

- Dean JCS. Marfan syndrome: clinical diagnosis and management. *Eur J Hum Genet.* 2007;15:724–33.
- Loeys BL, Dietz HC, Braverman AC, Callewaert BL, De Backer J, Devereux RB, et al. The revised Ghent nosology for the Marfan syndrome. *J Med Genet.* 2010;47:476–85.
- Lebrero A, Martins E, Almeida J, Pimenta S, Bernardes JM, Machado JC, et al. Utilidad del diagnóstico molecular en una familia con síndrome de Marfan y fenotipo vascular atípico. *Rev Esp Cardiol.* 2011;64:151–4.
- Van Dijk FS, Hamel BC, Hilhorst-Hofstee Y, Mulder BJM, Timmermans J, Pals G, et al. Compound heterocytous Marfan syndrome. *Eur J Med Genet.* 2009;52:1–5.
- Comeglio P, Johnson P, Arno G, Brice G, Evans A, Aragon-Martin J, et al. The importance of mutation detection in Marfan-related disorders: Report of 193 *FBN1* mutations. *Hum Mutat.* 2007;28:928.

doi: 10.1016/j.rec.2011.05.031