

## Prolonged Temporary Cardiac Pacing Using an External Permanent Pacing System

### *Estimulación cardíaca temporal prolongada mediante un sistema externo de estimulación permanente*

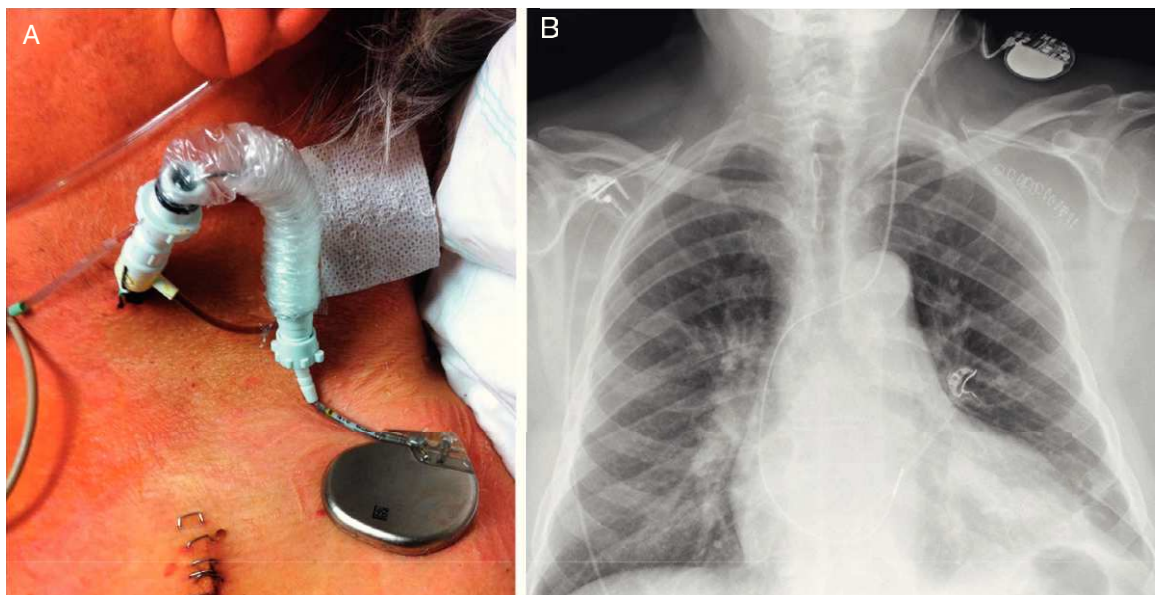
#### To the Editor,

The number of pacemakers and implantable cardioverter defibrillators implanted each year continues to grow in Spain, due largely to the increased life expectancy of the population in the case of pacemakers and the indications for primary prevention in the case of implantable cardioverter defibrillators.<sup>1,2</sup> Although the incidence of infections associated with implantable cardiac devices is not high, this complication is responsible for increased morbidity and mortality among affected patients. The strategy for achieving the best outcomes is complete removal of the system (electrodes and generator), along with prolonged antibiotic therapy.<sup>1</sup> In addition to the general problems faced in pacing-dependent patients, there is also the need for temporary cardiac pacing, at times very prolonged, before implantation of a new system. In most cases, temporary pacing is achieved through transluminal percutaneous placement of a bipolar electrode under radioscopic guidance. The electrode is advanced until good endocardial contact is achieved in the chamber to be paced. This electrode is then connected to a temporary pacing generator. However, the need for prolonged pacing increases the risk of electrode displacement, as well as capture or detection failure, something which may have particularly negative consequences in pacing-dependent patients.

We present the case of a 68-year-old man with a longstanding history of nonischemic cardiomyopathy who received a single-chamber internal defibrillation system in 2007 as primary prevention for sudden cardiac death. The active fixation electrode was implanted in the apex of the right ventricle. At the time of implantation, the patient had very depressed left ventricular systolic function and was in chronic atrial fibrillation. Months after implantation, the patient needed permanent pacing after medical treatment had been progressively optimized. Four years later, the patient showed progressive deterioration in his functional class and replacement of the single-chamber defibrillation system with

a defibrillation system with cardiac resynchronization was considered. While awaiting the procedure, the patient presented with an abscess in the region of the generator pocket. The system was completely removed and intravenous antibiotic therapy started to treat the late infectious process prior to implantation of the new system. In view of the complete dependence on pacing, it was decided, before removal, to implant a pacing system that would allow safe, easy, and prolonged physiologic pacing. Thus, with access via the left internal jugular vein and using a short sleeved introducer (Fig. 1A), a conventional permanent active fixation pacing electrode was advanced under radiologic guidance and in sterile conditions. The electrode was placed in the septal region of the right ventricle, with an optimum pacing threshold (Fig. 1B). The electrode was connected to a permanent sterilized pacemaker generator that had been removed from another patient without signs of infection. The generator was programmed in VVI/R mode at 70 bpm to 120 bpm to allow a more physiologic pacing. The introducer was attached to the skin, the sleeve was attached to the electrode, and the generator was fixed with covering adhesive bandaging to the left supraclavicular region to avoid pulling on the electrode or displacement of the generator. On the following day, the infected system was removed percutaneously without complications. The patient was able to walk from the next day onwards. This situation lasted 21 days while the prescribed antibiotic therapy was completed. After implantation, a defibrillation system with biventricular pacing was implanted, without any complications, and the fixation electrode was removed under radiologic guidance, also without any complications. The patient was discharged without any incidents, and showed a favorable clinical response to the new therapy and did not experience any subsequent complications.

The use of active fixation electrodes in permanent pacing to achieve appropriate temporary pacing has the advantage of greater electrode stability and the possibility of placement in different areas of the heart (in this case, the right ventricular septum was chosen to avoid complications on removing the previously implanted electrode from the apex). In addition, the risk of perforation is minimized with the greater flexibility and the possibility of avoiding apical sites. Inadvertent or accidental displacement of the electrode is not uncommon in long-term carriers of provisional pacemakers, and the outcome with an active



**Figure 1.** A: Left cervical region where the implanted system can be observed. B: Posteroanterior chest X-ray after removal of the infected system.

fixation system when this occurs could be compromised. Thus, particular care should be taken when dressing the wound and in ensuring that the system is stably fixed in the cervical region of the patient. On the other hand, the fact that it can be connected to a permanent pacemaker generator allows for programming of more physiologic pacing modes that help to maintain the patient in a stable clinical condition and allow the patient to walk about without clinical deterioration. Such advantages are particularly desirable in patients who are totally dependent on pacing and who require very prolonged temporary pacing. The small size of the generator is conducive to portability, and this in turn helps ensure that the patient can walk around and has greater mobility in general.

As a precaution, the resterilized pacemaker generators that are used for this purpose, although only ever in contact with the skin of the patient, should come from patients without evidence of infection at the time of switching to minimize the possibility of infection. The greater cost of the active fixation electrode used compared to the usual temporary pacing electrodes is compensated by the fact that the patient does not require admission to hospital in a unit with facilities for close patient monitoring.

This technique should be considered in patients who will require prolonged temporary pacing for any reason,<sup>3</sup> particularly those who are pacing-dependent.

Miguel A. Arias,\* Alberto Puchol, Marta Pachón, Jesús Jiménez-López, and Luis Rodríguez-Padial

*Unidad de Arritmias y Electrofisiología Cardíaca, Servicio de Cardiología, Hospital Virgen de la Salud, Toledo, Spain*

\*Corresponding author:

E-mail address: [maapalomares@secardiologia.es](mailto:maapalomares@secardiologia.es) (M.A. Arias).

Available online 23 November 2011

## REFERENCES

1. Coma Samartín R, Sancho-Tello de Carranza MJ, Ruiz Mateas F, Leal del Ojo González J, Fidalgo Andrés ML. Registro Español de Marcapasos. VII Informe Oficial de la Sección de Estimulación Cardíaca de la Sociedad Española de Cardiología (2009). *Rev Esp Cardiol.* 2010;63:1452-67.
2. Alzueta J, Linde A, Barrera A, Peña J, Peinado R. Registro Español de Desfibrilador Automático Implantable. VI Informe Oficial del Grupo de Trabajo de Desfibrilador Automático Implantable de la Sociedad Española de Cardiología (2009). *Rev Esp Cardiol.* 2010;63:1468-81.
3. Wilkoff BL, Love CJ, Byrd CL, Bongiorni MG, Carrillo RG, Crossley GH, et al. Transvenous lead extraction: heart rhythm society expert consensus on facilities, training, indications, and patient management. *Heart Rhythm.* 2009; 6:1085-104.

doi: 10.1016/j.rec.2011.07.023

## Value of Intraprocedural Radiologic Rotational Angiography in Atrial Fibrillation Ablation. Comparison With Other Imaging Techniques

**Valor de la angiografía rotacional radiológica intraprocedimiento en la ablación de fibrilación auricular. Comparación con otras técnicas de imagen**

### To the Editor,

Given the complex anatomy of the left atrium (LA) and pulmonary veins (PVs), physicians should obtain individualized information on patient anatomy prior to atrial fibrillation (AF) ablation. Magnetic resonance imaging (MRI) is an excellent tool in anatomic reconstruction. Furthermore, three-dimensional (3D) navigation systems (NS) are widely used.<sup>1,2</sup>

Radiologic rotational angiography (RRA) creates a 3D reconstruction of the cardiac chambers during the ablation procedure. It has previously been compared with imaging tests<sup>3-5</sup> but not with 3D NS.

We propose to evaluate the precision of RRA in LA and PVs reconstruction and compare it with that offered by using MRI and 3D NS.

We enrolled consecutive patients indicated for AF ablation. Exclusion criteria were bronchial asthma, obesity preventing free radiologic arm rotation, difficulty in transseptal puncture, kidney failure, and iodine allergy. Ablation was performed under general anesthesia and with Ensite-NavX<sup>®</sup> 3D NS (St. Jude Medical)<sup>3</sup>; cardiac MRI (Philips Achieva<sup>®</sup> 3T) had been performed previously. We programmed 240° C-arm rotation (Philips Allura equipment). High-dose adenosine was injected (18 mg-24 mg) to provoke a transient pause due to atrioventricular block. Once the block had started, iodine contrast was injected into the LA and the programmed rotation was conducted. Postprocessing of the images rendered a 3D LA reconstruction. One researcher (CH) analyzed the reconstruction blind and compared MRI (number of PV and diameter of PV ostia) with the 3D NS (number of PVs).

Continuous variables are described as median [interquartile range] and compared with the Wilcoxon signed-rank test. Correlation was calculated with Spearman's coefficient.

Initially, we enrolled 22 patients; 5 were excluded (2 for obesity, 1 for difficulty in transseptal puncture, 1 for asthma, and 1 for kidney failure). RRA was performed with no complications in 17 patients; 2 in the pilot phase, leaving 15 who constituted our study group (Table 1).

In 3 patients, RRA images could not be analyzed. In these patients, pause duration was too short for analysis, 2.1 [1.2-4.8] vs 12.3 s [7.8-16.2] ( $P=.034$ ). The RRA enabled us to observe 4 PVs with independent ostia in 8 of 12 patients with images suitable for analysis, and common antra in 4. When compared with 3D NS, RRA identified the same number of PVs and common antra in 10 of 12 patients (Fig. 1). In the remaining patients, 3D NS showed 1 left common antrum and 1 intermediate right PV missing in RRA and MRI.

MRI and measurements were available for 10 patients and identification of PVs and common antra proved the same as in RRA in 9 of them (Fig. 1). In the one remaining patient, MRI identified 1

**Table 1**  
Baseline Characteristics

Patients	15
Age, years	52±10
Men	14 (93)
LVEF, %	63±9
Indication for ablation	
Paroxysmic AF	13 (86.7)
Persistent AF	2 (13.3)
Rhythm at RRA	
Sinus rhythm	10 (67)
AF	5 (33)

AF, atrial fibrillation; LVEF, left ventricular ejection fraction; RRA, radiologic rotational angiography.

Data are expressed as no. (%) or mean±standard deviation.