

# Remodeling Annuloplasty Using a Prosthetic Ring Designed for Correcting Type-IIIb Ischemic Mitral Regurgitation

Farzan Filsoufi, Javier G. Castillo, Parwis B. Rahmanian, Alain Carpentier, and David H. Adams

Department of Cardiothoracic Surgery, Mount Sinai Medical Center, New York, New York, USA

**Introduction and objectives.** The most common mechanism underlying ischemic mitral regurgitation is restricted leaflet motion during systole (Carpentier's type IIIb). Annuloplasty is the preferred technique for surgical repair. The new Carpentier-McCarthy-Adams IMR Etlogix® prosthetic annuloplasty ring was designed specifically to address the particular peculiarities of this condition, principally asymmetric annular dilatation. The aims of this study were to review the rationale underlying the creation of the ring and to report our early clinical experience.

**Methods.** The study included 40 patients with type-IIIb ischemic mitral regurgitation (grade 3+/4+) who underwent mitral valve reconstruction using the new prosthetic ring between December 2003 and June 2005. Their mean age was 68(10) years. Concomitant procedures included coronary artery bypass grafting (n=27, 68%), tricuspid valvuloplasty (n=10, 25%), and a modified Maze procedure (n=9, 22%). The mean predicted EuroSCORE mortality for surgery was 17%(11).

**Results.** In-hospital mortality was 2.5% (n=1). Major postoperative morbidities included one case of stroke (2.5%), one renal failure (2.5%), and four respiratory failures (10%). PredischARGE echocardiography revealed no mitral regurgitation in 36 patients (92%) and mild regurgitation in three (8%). Long-term follow-up echocardiography was carried out in 36 patients (92%) after 15–34 months, and showed that the rate of recurrence of (grade ≥2+) mitral regurgitation was 3% (n=1).

**Conclusions.** The Carpentier-McCarthy-Adams IMR Etlogix® annuloplasty ring was effective in correcting type-IIIb ischemic mitral regurgitation. Its novel three-dimensional asymmetric shape is designed to deal with the anatomical and pathological characteristics of the condition and its use may, therefore, result in an excellent long-term outcome.

**Key words:** Myocardial ischemia. Mitral regurgitation. Valvuloplasty. Remodeling.

## Anuloplastia remodeladora mediante un anillo específico para la reparación de la regurgitación mitral isquémica de tipo IIIb

**Introducción y objetivos.** El mecanismo más frecuente de regurgitación mitral isquémica es la restricción de movimiento de los velos en sístole (tipo IIIb de Carpentier). La anuloplastia es la técnica más aceptada para su reparación. El nuevo anillo protésico Carpentier-McCarthy-Adams IMR Etlogix® fue diseñado para tratar cada una de las peculiaridades de esta entidad, principalmente la dilatación anular asimétrica. En este estudio revisamos las bases de creación del anillo y describimos nuestra experiencia clínica inicial.

**Métodos.** Se intervino a 40 pacientes (edad, 68 ± 10 años) de regurgitación mitral isquémica de tipo IIIb (grados 3+/4+) mediante el nuevo anillo protésico entre diciembre de 2003 y junio de 2005. Los procedimientos asociados fueron la revascularización coronaria (n = 27 [68%]), la valvuloplastia tricuspídea (n = 10 [25%]) y la técnica modificada de Maze (n = 9 [22%]). La estimación del riesgo quirúrgico por EuroSCORE fue del 17% ± 11%.

**Resultados.** La mortalidad hospitalaria fue del 2,5% (n = 1). La morbilidad postoperatoria incluyó 1 caso de accidente cerebrovascular (2,5%), 1 caso de insuficiencia renal (2,5%) y 4 casos de insuficiencia respiratoria (10%). El estudio ecocardiográfico previo al alta hospitalaria reveló la ausencia de regurgitación mitral en 36 pacientes (92%) y regurgitación de grado leve en 3 (8%). Se obtuvo el seguimiento ecocardiográfico a largo plazo de 36 pacientes (92%; intervalo de seguimiento, 15-34 meses), y se objetivó una tasa de recurrencia (grado ≥ 2+) del 3% (n = 1).

**Conclusiones.** El anillo de Carpentier-McCarthy-Adams IMR Etlogix® corrige de manera efectiva la regurgitación mitral isquémica de tipo IIIb. La nueva conformación tridimensional asimétrica afronta las características anatomopatológicas de este tipo de disfunción y puede aportar excelentes resultados a largo plazo.

**Palabras clave:** Isquemia miocárdica. Insuficiencia mitral. Valvuloplastia. Remodelado.

SEE EDITORIAL ON PAGES 1122-6

Project financed by the Department of Cardiothoracic Surgery.

Correspondence: Dr. J. Castillo/Dr. F. Filsoufi, Research Fellow, Department of Cardiothoracic Surgery, Mount Sinai Medical Center, 1190 Fifth Avenue, New York, NY 10029-1028 USA E-mail: javier.castillo@mountsinai.org

Received March 18, 2007.

Accepted for publication June 29, 2007.

## ABBREVIATIONS

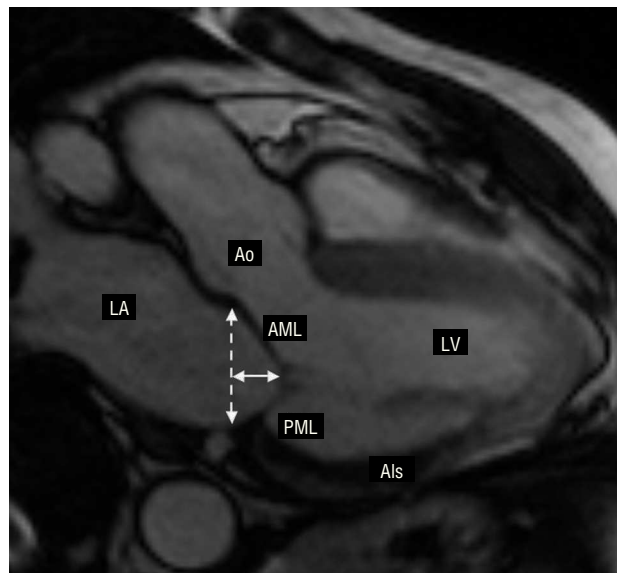
CMA-E: Carpentier-McCarthy-Adams IMR Etlogix  
 EF: ejection fraction  
 IMR: ischemic mitral regurgitation  
 IQR: interquartile range  
 MR: mitral regurgitation

## INTRODUCTION

Ischemic mitral regurgitation (IMR) is a complex disease with a poor prognosis. Restricted mitral leaflet motion during the end-systolic phase (Carpentier's type IIIb dysfunction, Table 1), which is more accentuated in the posterior leaflet, has been described as the leading cause of mitral regurgitation of ischemic origin.<sup>1</sup> After severe myocardial damage, the left ventricle undergoes a change in its elliptical morphology acquiring a more spherical shape.<sup>2</sup> The increase in the ventricular sphericity index leads to an apical and lateral displacement of the papillary muscles (particularly in the posteromedial papillary muscle), thus creating an imbalance between the forces of traction and coaptation in the mitral subvalvular apparatus. Displacement of the papillary muscles involves apical tenting of the valve leaflets. This phenomenon stops the free edges of the leaflets from reaching the physiological annular plane (Figure 1), thus causing mitral regurgitation.

Ischemic papillary muscle dysfunction is compounded by the creation of excessive tension in the chordae tendinae and impedes the correct coaptation of the mitral leaflets, further worsening the grade of mitral regurgitation. In IMR, postischemic ventricular remodeling is the main factor catalyzing mitral dysfunction; nevertheless, dilatation and later annular deformation — the result of the lack of valvular coaptation — are frequently associated with type-IIIb dysfunction.

Three-dimensional echocardiography has refined the analysis of the valve leaflets leading to higher levels of detection and better quantification of IMR. Kwan et al<sup>3</sup> corroborated a concept previously postulated by our group, demonstrating that mitral valve deformation follows an asymmetrical pattern along its commissural



**Figure 1.** Cardiac magnetic resonance imaging (vertical long axis, 2-chamber view, maximum systolic pressure). The ischemic area (Als) involving the posteromedial papillary muscle was calculated (courtesy of Dr Javier Sanz). LA indicates left atrium; Ao, aorta; continuous line, tenting height; discontinuous line, physiological plane of coaptation and mitral annular diameter; AML, anterior mitral leaflet; LV, left ventricle; PML, posterior mitral leaflet.

diameter. They also confirmed that in patients with IMR there is marked tethering of both leaflets at the posteromedial edge (segments A3 and P3), whereas tenting was less pronounced in the segments at the anterolateral edge (segments A1 and P1). Furthermore, in an ovine model of chronic ischemic mitral regurgitation, Gorman et al<sup>4</sup> showed that all the segments of the mitral annulus, including the anterior segments, are asymmetrically dilated, especially in the posteromedial segment.

To date, the surgical treatment of choice for patients presenting IMR is mitral valve annuloplasty, employing a great variety of surgical techniques in combination with myocardial revascularization.<sup>5</sup>

Recent findings, some already mentioned, indicate that most of the surgical techniques used during the last decade may not be the optimal treatment in preventing the long-term appearance of residual or recurrent mitral regurgitation (MR), observed in 10%-15% of patients during clinical follow-up.<sup>6-8</sup>

A better understanding of the pathophysiological mechanism of type-IIIb IMR has led to the development of a specific ring for this clinical entity: the Carpentier-McCarthy-Adams IMR Etlogix (CMA-E) annuloplasty ring.<sup>9</sup> This new prosthetic ring not only corrects the general dilatation of the native valve, but also has the aim of correcting the asymmetrical dilatation and tethering of segment P2 and P3. The resulting increase in leaflet coaptation surface should lead to more durable long-term functionality. In this study, we describe our initial clinical

**TABLE 1. Pathophysiological Triad of Ischemic Mitral Regurgitation**

Dysfunction	Lesions	Presentation
Type I	Annular dilatation	Chronic
Type II	Papillary muscle rupture	Acute
	Ruptured chordae tendinae	Acute
	Elongation of the papillary muscle	Chronic
Type IIIb	Displacement of the papillary muscle	Acute or chronic

experience with the new prosthetic mitral ring in patients with type-IIIb IMR.

## METHODS

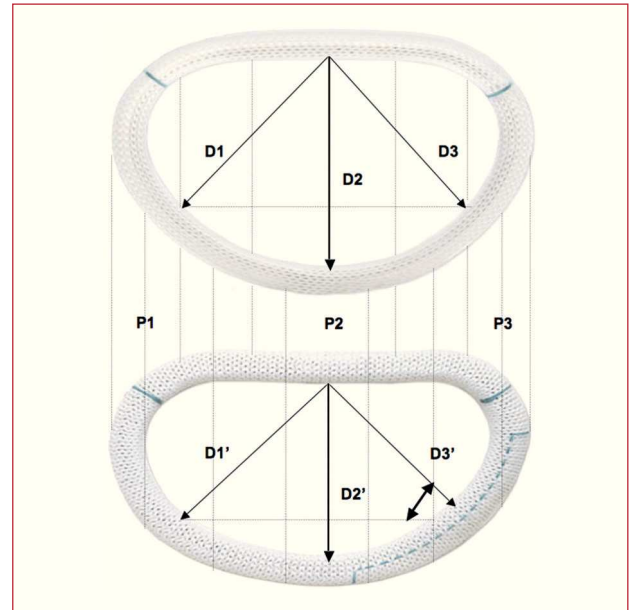
The study included 40 consecutive patients who underwent interventions for type-IIIb ischemic mitral regurgitation using the new CMA-E prosthetic mitral ring (Edwards LifeSciences, Irving, California, USA) between December 2003 and June 2005. Patients who had already undergone surgery or who required additional tricuspid valve surgery were also included in the study group. A database was used to retrospectively identify all the patients. The clinical record of each patient was reviewed to obtain additional information. The study was approved by the ethical research committee of our institutional review board and the research period established following the international recommendations on clinical research (HIPPA) according to the Declaration of Helsinki developed by the World Medical Association (1975).

All the patients underwent preoperative transthoracic echocardiographic study; restricted valve leaflet motion during the end-systolic phase was confirmed in all cases (type-IIIb IMR, Carpentier Functional Classification). The severity of MR was prospectively assessed in all the patients based on regurgitant jet area (color Doppler ultrasound) and regurgitant volume quantified by semiquantitative Doppler ultrasound and 2-dimensional echocardiography. The grade of MR was quantified from 0 to 4+ (0, none; 0.5+, trace; 1+, mild; 2+, moderate; 3+, moderate to severe; and 4+, severe).<sup>10</sup>

Furthermore, the geometry of the mitral apparatus was evaluated by measuring the mitral annular diameter, mitral valve tenting height (distance between the mitral leaflet coaptation point and its physiological plane of coaptation) and mitral valve tethering area.

### Carpentier-McCarthy-Adams IMR Etlogix Annuloplasty Ring

Two basic concepts came together when creating the new ring: reducing the mitral annular diameter using an undersized ring, and correcting the asymmetrical annular deformation of the native mitral ring and thus return it to its characteristic saddle shape. This new design leads to an increase in the valve leaflet coaptation surface area by reducing the anteroposterior dimension (D2 vs D2'), which remains invariable during the entire cardiac cycle due to its rigid titanium core), and the septolateral dimension (D3 vs D3'). Thus, there is an annular reduction of 1 size for the anteroposterior dimension (D2') and of 2 sizes for the septolateral dimension (D3') compared to the Carpentier-Edwards Physio ring (Figure 2). This makes it possible to select the size of the prosthetic ring based on the dimensions of the anterior mitral leaflet (calibrated using a standard Carpentier-Edwards sizer),



**Figure 2.** Comparison between the classic Physio (upper) and the new CMA-E ring (lower). Differences between the dimensions outlined within the 2 rings were calculated: septomedial dimension (D1 and D1'), anteroposterior dimension (D2 and D2'), and septolateral dimension (D3 and D3'). D2' is 1 size less than D2, and D3' is 2 sizes less than D3.

which enables valve remodeling with optimal coaptation in segments P2 and P3.

## Statistical Analysis

All values are expressed as mean (SD) and quantitative variables as median and interquartile range (IQR). The Student *t* test was used for paired data and to compare echocardiographic measurements before and after the surgical procedure. Discrete variables are presented as percentages and compared using  $\chi^2$ .  $P < .05$  was considered statistically significant. The SPSS software package (version 15.0, SPSS., Chicago, Illinois, USA) was used for the statistical analysis.

## RESULTS

Table 2 presents the clinical characteristics of the patients. The study population included 30 men (75%) and 10 women (25%). The mean age was 68 (10) years. Mean ejection fraction (EF) was 39% (14%) (range, 14%-64%). The grade of coronary disease among patients was distributed as follows: 9 (22%) patients presented 1-vessel coronary disease; 14 (35%), 2-vessel coronary disease; and 17 (43%), 3-vessel coronary disease.

The preoperative echocardiographic MR grade among patients was distributed as follows: 28 (70%) patients presented grade 4+ MR and 12 (30%), grade 3+ MR.

**TABLE 2. Clinical Characteristics of the Patients**

Age, mean (SD), years	68 (10)
Age >70 years, n (%)	22 (55)
Men, n (%)	30 (75)
BMI, median (IQR)	26 (24-29)
Atrial fibrillation, n (%)	9 (22)
EF, mean (SD), %	39 (14)
EF <30% (%)	21 (52)
Coronary artery disease	
1 vessel, n (%)	9 (22)
2 vessels, n (%)	14 (35)
3 vessels, n (%)	17 (43)
Previous PTCA, n (%)	6 (15)
Previous coronary artery surgery, n (%)	7 (18)
Previous myocardial infarction, n (%)	22 (55)
Arterial hypertension, n (%)	14 (35)
Pulmonary hypertension, n (%)	17 (42)
Congestive heart failure, n (%)	26 (65)
Diabetes, n (%)	11 (27)
Kidney failure, n (%)	4 (10)
Previous stroke, n (%)	7 (18)
Intraaortic balloon counterpulsation, n (%)	2 (5)
High EuroSCORE (9%-25%), n (%)	16 (40)
Very high EuroSCORE (> 25%), n (%)	9 (22)

PTCA indicates percutaneous transluminal coronary angioplasty; SD, standard deviation; EuroSCORE, European System for Cardiac Operative Risk Evaluation; EF, ejection fraction; BMI, body mass index; IQR, interquartile range.

## Surgical Procedures

Myocardial revascularization was performed in 27 (68%) patients. The mean number of coronary grafts was 2.7 (1.3). Before mitral repair a modified Maze procedure was performed in 9 (22%) patients with a history of atrial fibrillation, and a cryoablation technique used for tissue ablation (Cryocath Technology, Pointe-Claire, Canada).<sup>11</sup> Intraoperative exploration confirmed previous echocardiographic findings in all cases. The CMA-E prosthetic mitral ring was successfully implanted in all patients; it was fixed to the native valve using interrupted mattress sutures (12-15 stitches). The sutures

were overlapped at P2, P3, and the posteromedial commissure, with the aim of releasing excess tension and thus avoiding the potential risk of annular dehiscence. Ring size was decided after measuring the commissural distance and anterior leaflet surface area, using a standard Carpentier-Edwards sizer. After it was implanted and fixed to the native valve, the valve was examined to rule out any possibility of residual leakage by injecting pressured saline serum into the ventricular cavity, thus confirming that the coaptation area was good ( $\geq 8$  mm). The line of coaptation was typically asymmetrical due to extensive previous tenting in segments P2, P3, and in the posteromedial commissural area (Figure 3). Table 3 shows the prosthetic ring sizes used and concomitant procedures followed. Mean cardiopulmonary bypass and aortic clamp times were 162 (70) min and 115 (50) min, respectively.

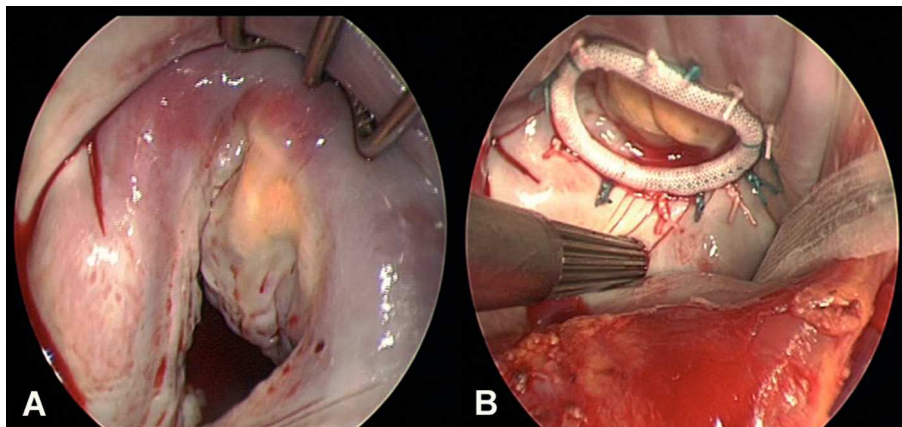
## Morbidity and Mortality

Mortality during hospital stay or 30 days postprocedure was 2.5% (n=1). The cause of death was multiorgan failure due to prolonged low cardiac output syndrome. In the postoperative period there was 1 case (2.5%) of stroke, 1 (2.5%) of kidney failure (creatinine >2.5 mg/dL for more than 7 days or need for dialysis), 4 (10%) respiratory failure (need for mechanical ventilation for more than 72 h), and 1 (2%) sternal wound infection. Three patients (7%) required a permanent pacemaker. There were no cases of annular dehiscence or early endocarditis.

Median hospitalization time was 11 (IQR, 7-15) days. Table 4 shows postoperative events.

## Echocardiographic Findings

Echocardiographic findings are shown in Figure 4. Mitral valve regurgitation grade was significantly reduced in all patients (3.8 [0.4] and 0.3 [0.3];  $P=.001$ ). Mitral valve geometry values were also significantly reduced



**Figure 3.** A: intraoperative view prior to mitral valve annuloplasty. B: intraoperative view of the implanted CMA-E ring.



**TABLE 3. Surgical Analysis**

	n (%)
Ring size (CMA-E)	
26 mm	19 (48)
28 mm	15 (37)
30 mm	6 (15)
Concomitant procedures	
Coronary surgery	27 (68)
Tricuspid valve repair	10 (25)
Modified Maze technique	9 (22)
Closure of patent foramen ovale	2 (5)

CMA-E indicates Carpentier-McCarthy-Adams IMR Etlogix.

after surgery: mitral valve annular diameter (3.2 [0.8] cm to 2.3 [0.05] cm;  $P=.001$ ), tenting height (0.6 [0.2] cm to 0.4 [0.1] cm;  $P=.001$ ), and tethering area (1.2 [0.4] cm to 0.6 [0.3] cm;  $P=.001$ ) (Figure 5). There were no significant changes in ejection fraction (39% [14%] to 40% [11%];  $P=.631$ ) and no case of systolic anterior motion occurred. At hospital discharge, 36 (90%) patients did not present postoperative residual MR and only 3 (10%) presented residual mild MR.

### Clinical and Echocardiographic Follow-Up

Clinical and echocardiographic follow-up was conducted in 97% (38/39) of the patients who underwent successful surgical intervention and were discharged; 2 (8%) late deaths occurred at 7 months and 12 months. Echocardiographic follow-up  $\geq 15$  months (range, 15-34

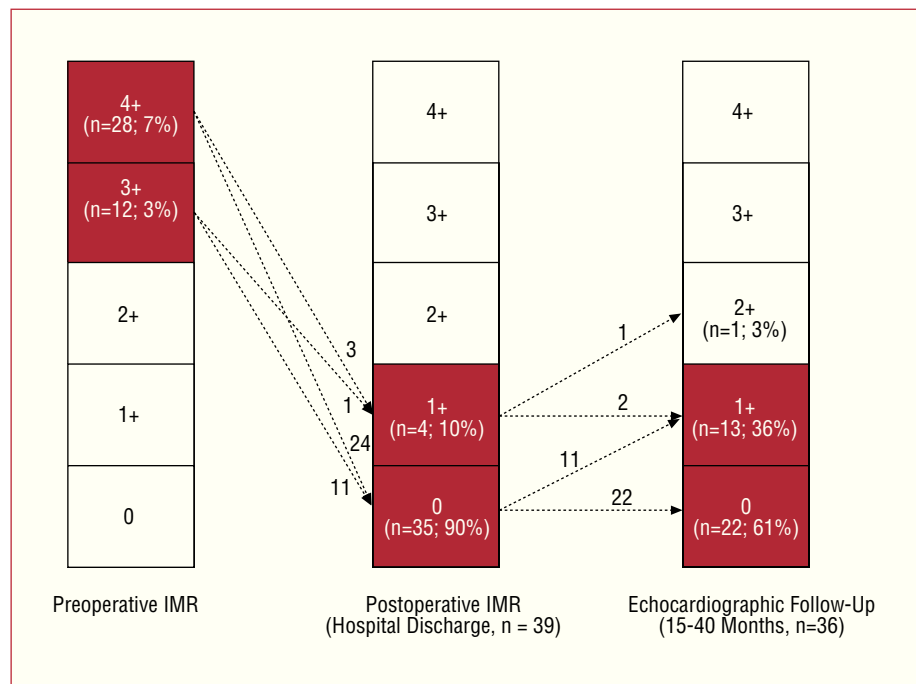
**TABLE 4. Postoperative Morbidity and Mortality During Hospital Stay or During 30 Days Post-Surgical Procedure**

	n (%)
Mortality	1 (2.5)
Stroke	1 (2.5)
Kidney failure	1 (2.5)
Respiratory failure	4 (10)
Reintervention because of bleeding	1 (2.5)
Sternal wound infection	1 (2.5)

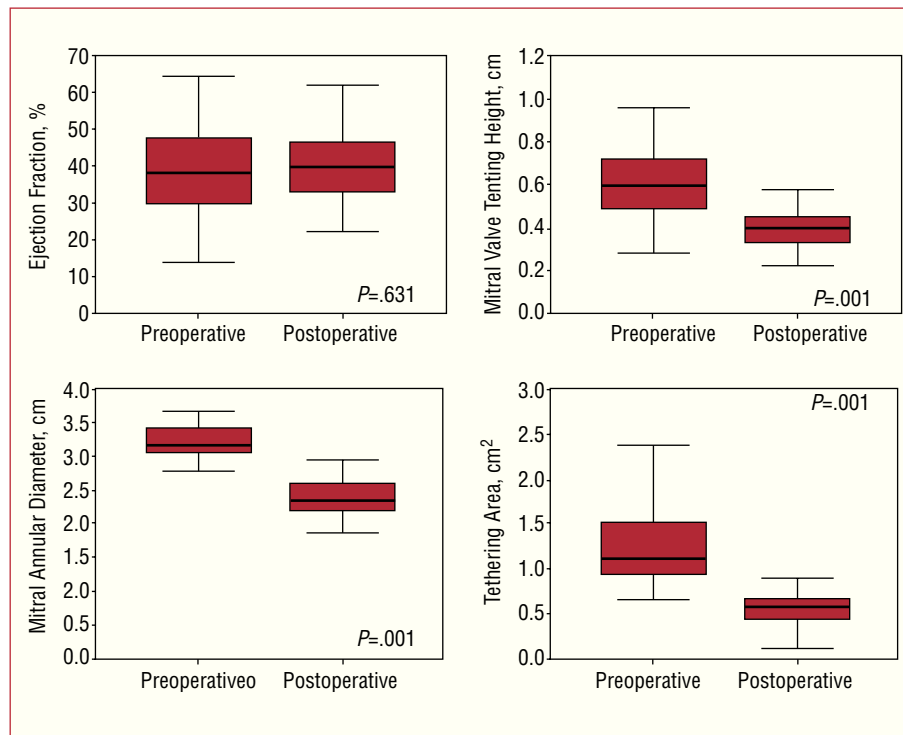
months) was conducted in 36 (92%) patients. The echocardiographic study demonstrated the absence of MR in 22 (61%) patients, mild MR in 13 (36%), and moderate MR in 1 (3%); the rate of recurrence of MR was 3%.

### DISCUSSION

In this observational study, we describe our first clinical experience with the new CMA-E prosthetic mitral ring designed for the surgical treatment of patients with type-IIIb IMR. The new ring is effective in correcting this type of IMR and offers promising initial clinical results. Clinical and echocardiographic follow-up in 97% of the patients demonstrated the reliability and durability of the new ring and indicated an MR recurrence rate of 3% ( $n=1$ ). During the study period, no complications associated with the prosthetic ring were observed, such as annular dehiscence, early endocarditis, or thromboembolic events.



**Figure 4.** Echocardiographic changes in mitral regurgitation grade during the study period. IMR indicates ischemic mitral regurgitation.



**Figure 5.** Comparison between preoperative and postoperative values associated with mitral valve geometry variables (mitral valve annular diameter, tenting height, and tethering area) and ejection fraction.

### A Specific Ring for a Specific Condition

Many studies have been conducted in an attempt to better understand the causal pathophysiological mechanisms of IMR, thus leading to the development of new surgical techniques and devices aimed at treating this complex valve lesion.<sup>12-14</sup> The first studies addressing this issue established several valve repair techniques, such as suture annuloplasty (de Vega-type mitral annuloplasty), the use of cardiac rings, or the implantation of partial bands of variable flexibility, all of which are of limited durability and lead to residual MR and its reappearance in the short-term.<sup>15-17</sup> Hausmann et al<sup>16,18</sup> reported a series of 140 patients who underwent suture annuloplasty for IMR with an incidence of residual MR ( $\geq 2+$ ) of 28%. In a report from the Cleveland Clinic Foundation group, Bhudia et al<sup>19</sup> demonstrated that posterior annuloplasty and the implantation of a flexible partial band in combination with edge-to-edge repair was associated with an MR recurrence rate of 30% at 18-month clinical follow-up.

In a clinico-anatomical study of the heart human, Hueb et al<sup>20</sup> contributed interesting data on mitral valve geometry in patients with IMR, demonstrating that in patients with ischemic cardiomyopathy or dilated cardiomyopathy, annular deformation was present in all the ring segments, including the anterior ones. These findings were later confirmed by Gorman et al<sup>21</sup> in an ovine model of chronic IMR.

They verified that dilatation of the anterior and posterior mitral ring segments, together with asymmetrical

ventricular dilatation, was the cause of tethering, and thus, of mitral regurgitation. The experience of several research groups has shown that annuloplasty using flexible partial bands may not be the optimal treatment technique for patients with type-IIIb IMR. We consider that these types of prosthetic ring do not completely remodel the native valve and, in particular, neglect the insertion area of the anterior mitral leaflet.

Similar findings have been described regarding annuloplasty using complete flexible rings in patients with IMR. Tahta et al<sup>22</sup> analyzed long-term outcomes in 100 patients who had undergone combination surgery (mitral valve annuloplasty and coronary artery bypass grafting) using a Duran flexible annuloplasty ring. Over a mean clinical follow-up time of almost 36 months, 29% of the patients presented moderate (2+) recurrent mitral regurgitation. In our opinion, flexible rings would not succeed in stabilizing the native valve during the systolic phase; they reduce the intercommissural distance of the native valve, but have a limited impact on its anteroposterior diameter, a critical parameter in these types of patient. On the other hand, annular remodeling using a rigid or semirigid ring — a concept supported by the Miller<sup>23</sup> research team — would reestablish the size and shape of the mitral ring, which also contributes to a significant reduction in anteroposterior diameter.

In this line, in 2004, Bax et al<sup>24</sup> described the efficacy of restrictive annuloplasty using a Carpentier-Edwards Physio ring (Carpentier rigid ring) for the treatment of type-IIIb MR. In a series of 51 patients with grade 3+/4+

MR, the authors reported the absence of MR after a mean clinical follow-up time of 2 years.

Restricted valve leaflet motion in type-IIIb IMR causes a reduction in the leaflet tissue available for optimal coaptation; thus, we believe that an aggressive reduction in anteroposterior diameter would provide a suitable coaptation surface area. In the mid-1990s, Bolling et al<sup>25</sup> introduced the concept of mitral reconstruction using an undersized prosthetic ring in order to reduce the incidence of residual or recurrent MR. Currently, this concept is widely accepted by most surgeons and is applied in mitral valve annuloplasty in patients with type-IIIb IMR. Furthermore, the excellent results described by Bax et al<sup>24</sup> support both this and the use of undersized prosthetic rings.

## CONCLUSIONS

The new CMA-E prosthetic mitral ring represents another advance in annuloplasty mitral valve repair. This prosthetic ring combines the principle of overcorrection with repair of the asymmetrical annular deformation in type-IIIb dysfunction. Its morphology provides an increase in valve leaflet coaptation surface area due to the reduction in anteroposterior diameter. Its asymmetrical three-dimensional design, and the reduced curvature in segments P2 and P3, lead to better tenting correction. Our study shows that the ring is very effective in correcting type-IIIb IMR. Echocardiographic results support the efficacy of the repair over a clinical follow-up time of 15 months to 34 months. However, more clinical series including a greater number of patients are needed and even longer clinical follow-up times to confirm the durability of this reconstruction technique.

## REFERENCES

1. Carpentier A. Cardiac valve surgery — the “French correction.” *J Thorac Cardiovasc Surg.* 1983;86:323-37.
2. Levine RA, Hung J, Otsuji Y, Messas E, Liel-Cohen N, Nathan N, et al. Mechanistic insights into functional mitral regurgitation. *Curr Cardiol Rep.* 2002;4:125-9.
3. Kwan J, Shiota T, Agler DA, Popovic ZB, Qin JX, Gillinov MA, et al. Geometric differences of the mitral apparatus between ischemic and dilated cardiomyopathy with significant mitral regurgitation: real-time three-dimensional echocardiography study. *Circulation.* 2003;107:1135-40.
4. Gorman JH, 3rd, Jackson BM, Enomoto Y, Gorman RC. The effect of regional ischemia on mitral valve annular saddle shape. *Ann Thorac Surg.* 2004;77:544-8.
5. Kron IL, Green GR, Cope JT. Surgical relocation of the posterior papillary muscle in chronic ischemic mitral regurgitation. *Ann Thorac Surg.* 2002;74:600-1.
6. Magne J, Pibarot P, Dagenais F, Hachicha Z, Dumesnil JG, Senéchal M. Preoperative posterior leaflet angle accurately predicts outcome after restrictive mitral valve annuloplasty for ischemic mitral regurgitation. *Circulation.* 2007;115:782-91.
7. Kuwahara E, Otsuji Y, Iguro Y, Ueno T, Zhu F, Mizukami N, et al. Mechanism of recurrent/persistent ischemic/functional mitral regurgitation in the chronic phase after surgical annuloplasty: importance of augmented posterior leaflet tethering. *Circulation.* 2006;114:1529-34.
8. Zhu F, Otsuji Y, Yotsumoto G, Yuasa T, Ueno T, Yu B, et al. Mechanism of persistent ischemic mitral regurgitation after annuloplasty: importance of augmented posterior mitral leaflet tethering. *Circulation.* 2005;112:1396-401.
9. Daimon M, Fukuda S, Adams DH, McCarthy PM, Gillinov AM, Carpentier A, et al. Mitral valve repair with Carpentier-McCarthy-Adams IMR ETlogix annuloplasty ring for ischemic mitral regurgitation: early echocardiographic results from a multi-center study. *Circulation* 2006;114:1588-93.
10. Zoghbi WA, Enriquez-Sarano M, Foster E, Grayburn PA, Kraft CD, Levine RA, et al. Recommendations for evaluation of the severity of native valvular regurgitation with two-dimensional and Doppler echocardiography. *J Am Soc Echocardiogr.* 2003;16:777-802.
11. Gehi AK, Adams DH, Salzberg SP, Filsoufi F. Outcomes and predictors of success of a radiofrequency- or cryotherapy-simplified left-sided maze procedure in patients undergoing mitral valve surgery. *J Heart Valve Dis.* 2006;15:360-7 [comment, 367-8].
12. Revuelta JM, Bernal JM. Insuficiencia mitral isquémica funcional: un debate abierto. *Rev Esp Cardiol.* 2005;58:327-32.
13. Borger MA, Alam A, Murphy PM, Doenst T, David TE. Chronic ischemic mitral regurgitation: repair, replace or rethink? *Ann Thorac Surg.* 2006;81:1153-61.
14. Gómez-Durán C. Estado actual de la cirugía mitral reconstructiva. *Rev Esp Cardiol.* 2004;57:39-46.
15. Czer LS, Maurer G, Trento A, DeRobertis M, Nessim S, Blanche C, et al. Comparative efficacy of ring and suture annuloplasty for ischemic mitral regurgitation. *Circulation.* 1992;86:II46-52.
16. Hausmann H, Siniawski H, Hetzer R. Mitral valve reconstruction and replacement for ischemic mitral insufficiency: seven years' follow up. *J Heart Valve Dis.* 1999;8:536-42.
17. Von Oppell UO, Stemmet F, Brink J, Commerford PJ, Heijke SA. Ischemic mitral valve repair surgery. *J Heart Valve Dis.* 2000;9:64-73 [comment, 73-4].
18. Hausmann H, Siniawski H, Hotz H, Hofmeister J, Chavez T, Schmidt G, et al. Mitral valve reconstruction and mitral valve replacement for ischemic mitral insufficiency. *J Card Surg.* 1997;12:8-14.
19. Bhudia SK, McCarthy PM, Smedira NG, Lam BK, Rajeswaran J, Blackstone EH. Edge-to-edge (Alfieri) mitral repair: results in diverse clinical settings. *Ann Thorac Surg.* 2004;77:1598-606.
20. Hueb AC, Jatene FB, Moreira LF, Pomerantzeff PM, Kallas E, De Oliveira SA. Ventricular remodeling and mitral valve modifications in dilated cardiomyopathy: new insights from anatomic study. *J Thorac Cardiovasc Surg.* 2002;124:1216-24.
21. Gorman JH 3rd, Gorman RC, Jackson BM, Enomoto Y, St John-Sutton MG, Edmunds LH Jr. Annuloplasty ring selection for chronic ischemic mitral regurgitation: lessons from the ovine model. *Ann Thorac Surg.* 2003;76:1556-63.
22. Tahta SA, Oury JH, Maxwell JM, Hiro SP, Duran CM. Outcome after mitral valve repair for functional ischemic mitral regurgitation. *J Heart Valve Dis.* 2002;11:11-8 [comment, 18-9].
23. Miller DC. Ischemic mitral regurgitation redux—to repair or to replace? *J Thorac Cardiovasc Surg.* 2001;122:1059-62.
24. Bax JJ, Braun J, Somer ST, Klautz R, Holman ER, Versteegh MI, et al. Restrictive annuloplasty and coronary revascularization in ischemic mitral regurgitation results in reverse left ventricular remodeling. *Circulation.* 2004;110:II103-8.
25. Bolling SF, Pagani FD, Deeb GM, Bach DS. Intermediate-term outcome of mitral reconstruction in cardiomyopathy. *J Thorac Cardiovasc Surg.* 1998;115:381-6 [comment, 387-8].