

ECG Contest

Response to ECG, June 2015



Respuesta al ECG de junio de 2015

Domingo Marzal Martín

Servicio de Cardiología, Complejo Hospitalario de Mérida, Mérida, Badajoz, Spain

This is a case of accelerated nodal rhythm secondary to digitalis toxicity. A digoxin blood level of 5.61 ng/mL was obtained in the emergency department, which confirmed the suspicion. This disorder is also called nonparoxysmal nodal tachycardia and is due to the presence of an ectopic focus at the atrioventricular node that inhibits sinus node function. It involves a regular tachycardia with a narrow QRS complex and a heart rate between 100 and 130 bpm and possible absent or retrograde P waves. It may be a chance finding in healthy individuals or is often associated with conditions such as digitalis toxicity, myocardial necrosis in diverse contexts, and hypokalemia (Figure).

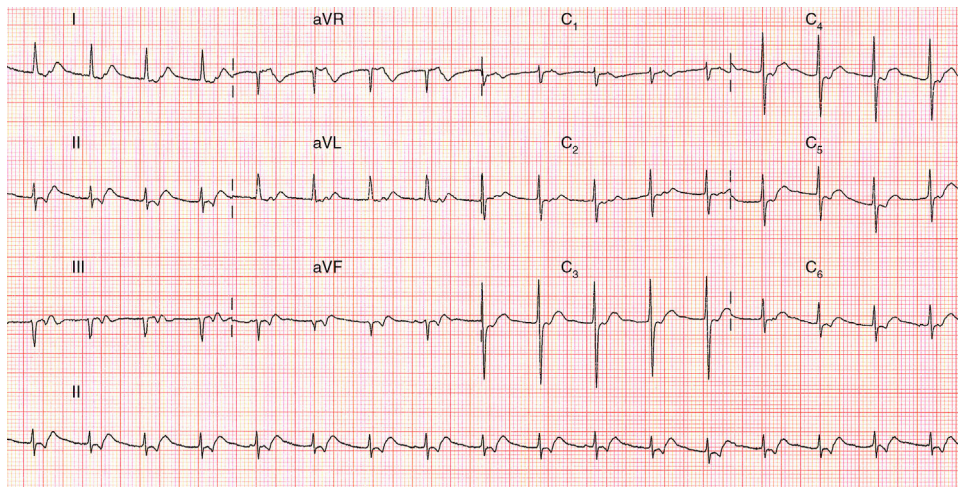


Figure.

SEE RELATED ARTICLE:

<http://dx.doi.org/10.1016/j.rec.2014.08.018>E-mail address: domingo.marzal@gmail.com<http://dx.doi.org/10.1016/j.rec.2014.08.019>

1885-5857/© 2014 Sociedad Española de Cardiología. Published by Elsevier España, S.L.U. All rights reserved.