

## Safety and Usefulness of Transesophageal Echocardiography in the Acute Phase of Myocardial Infarction

Leopoldo Pérez de Isla, Miguel Ángel García Fernández, Mar Moreno, Javier Bermejo, Raúl Moreno, Esteban López de Sá, José Luis López Sendón, Javier Jiménez Candil and Óscar Díaz Castro

Laboratorio de Ecocardiografía. Servicio de Cardiología. Hospital General Universitario Gregorio Marañón. Madrid. España.

**Introduction and objectives.** The usefulness and safety of transesophageal echocardiography have been assessed in other studies but there is no report in which these factors have been evaluated in the acute phase of myocardial infarction.

**Patients and method.** Transesophageal echocardiography was performed 56 times in 55 patients in the first week after a myocardial infarction.

**Results.** The study was completed in 54 of 56 patients. The indications were a transthoracic acoustic window that did not provide an accurate diagnosis in 13 (23.2%), diagnosis of mechanical complications and severity assessment of mitral regurgitation in 35 (62.5%), exclusion of aortic dissection in 4 (7.1%), assessment of the severity of aortic stenosis in 1 (1.8%), exclusion of the presence of atrial thrombus in 1 (1.8%), evaluation of the left ventricular outflow tract gradient in 1 (1.8%), and evaluation of the presence of a left ventricular thrombus in 1 patient (1.8%). Two patients (3.6%) died while the study was being made, the first one 10 minutes after finishing the echocardiogram due to progression of a partial rupture of the papillary muscle and the second due to left ventricle free wall rupture. In both patients, the indication for transesophageal echography was the need for proper evaluation of a post-Acute Myocardial Infarction mechanical complication.

**Conclusions.** Transesophageal echocardiography is a very useful technique for evaluating patients during the acute phase of myocardial infarction but further studies are needed to establish its safety in these patients.

**Key words:** *Echocardiography. Myocardial infarction. Sudden death.*

Full English text available at: [www.revespcardiol.org](http://www.revespcardiol.org)

Correspondence: Dr. M.A. García Fernández.  
Laboratorio de Ecocardiografía. Hospital General Universitario Gregorio Marañón.  
Dr. Esquerdo. 46. 28007 Madrid. España.  
E-mail: [leopisla@hotmail.com](mailto:leopisla@hotmail.com)

Received 26 December 2001.  
Accepted for publication 28 June 2002.

### Eficacia y seguridad de la ecocardiografía transesofágica en la fase aguda del infarto

**Introducción y objetivos.** La rentabilidad y seguridad de la ecocardiografía transesofágica han sido analizadas en numerosos estudios, pero no existe ningún trabajo que evalúe estos factores durante la fase aguda de un infarto. Nuestro objetivo fue estudiar estos aspectos en pacientes en los que el ecocardiograma transtorácico no fue concluyente.

**Pacientes y método.** Se realizaron 56 estudios a 55 pacientes en la primera semana de evolución de un infarto de miocardio.

**Resultados.** Se realizó el estudio con éxito en 54 de los 56 casos. Las indicaciones fueron: ausencia de ventana transtorácica en pacientes en los que era necesaria una valoración morfofuncional cardíaca en 13 casos (23,2%), diagnóstico de complicaciones mecánicas y valoración de severidad de una insuficiencia mitral en 35 pacientes (62,5%), descartar una disección aórtica en 4 enfermos (7,1%), graduar la severidad una estenosis aórtica en uno (1,8%), descartar la presencia de trombos auriculares en un caso (1,8%), evaluar gradientes en el tracto de salida del ventrículo izquierdo en un paciente (1,8%) y valorar de presencia de trombos en ventrículo izquierdo en un caso (1,8%). Dos pacientes (3,6%) fallecieron durante el estudio: el primero por progresión de una rotura parcial de músculo papilar y el segundo por rotura aguda de pared libre. En ambos casos, la indicación del estudio fue valorar las complicaciones mecánicas.

**Conclusiones.** La ecocardiografía transesofágica es útil durante la fase aguda de un infarto, pero hasta que no dispongamos de estudios definitivos, debemos indicar con cautela este tipo de exploración a pacientes con sospecha de complicaciones mecánicas.

**Palabras clave:** *Ecocardiografía. Infarto de miocardio. Muerte súbita.*

## INTRODUCTION

It is often extremely important to be able to establish a definitive diagnosis quickly and accurately for patients who have suffered an acute myocardial infarction (AMI). Transthoracic echocardiography



(TTE) is a very useful diagnostic tool and is currently routinely used for this type of patient. Nevertheless, the technique does have some limitations, notably the difficulty in obtaining sufficiently high-quality images in certain patients. This difficulty often occurs in patients admitted to cardiac care units during the acute phase of a myocardial infarction, since some patients require being placed on a ventilator, are hemodynamically monitored by means of a Swan-Ganz catheter and arterial shunt, or require circulation assistance devices such as intra-aortic contrapulsation balloons.

Transesophageal echocardiography (TEE) has proven to be useful for establishing the diagnosis of various cardiac ailments. We should not forget that TEE is considered the diagnostic technique of choice for illness such as bacterial endocarditis, aortic dissection, prosthetic mitral valve dysfunction, and suspected thrombi and atrial masses.

Studies have evaluated the usefulness of TEE in critically ill patients.<sup>1-6</sup> Nevertheless, no study has specifically analyzed the use of TEE in patients admitted to a coronary care unit during the acute phase of a myocardial infarction. Therefore, the importance of our study is that, for the first time, we present data analyzing the usefulness and safety of using TEE in this setting.

Our aim was to perform a descriptive analysis of the use of this technique in patients admitted to the coronary care unit of our hospital during the first week after developing a myocardial infarction.

## PATIENTS AND METHODS

We performed 85,966 echocardiograms between January, 1991, and March, 2000, (a total of 111 months) in our facility. Of these, 5837 were transesophageal studies; 56 were performed on patients admitted to the coronary care unit during the first week after developing an acute myocardial infarct (AMI). All patients had previously undergone a TTE, with inconclusive results. The type of sedation used for the patient was left to the discretion of the physician performing the study.

### Echocardiography study

The studies were performed using standard techniques and one of the following echocardiography units depending on the availability of the unit and the preference of the physician performing the test: Hewlett Packard 1500 with a biplane probe (37.5%), Acuson Sequoia with a multiplane probe (30.36%), and Hewlett Packard 5500 with a multiplane probe (32.1%).

## Statistical analysis

The results of the descriptive analysis are presented as absolute values followed by percentage.

## RESULTS

A total of 56 studies were performed on 55 patients, 21 of whom (38.2%) were women and 34 men (61.8%). In 34 patients (61.8%) the infarct developed with ST segment elevation and in 21 patients (38.2%) without ST segment elevation. A total of 29 (52.7%) infarcts had an inferior location, 18 (32.7%) had an inferior or inferoposterior location, 5 (9.1%) a lateral location, and 3 (3.5%) had an undetermined location. The Killip class of the patients at the time the study was performed was I in 39 patients (69.64%), II in 7 patients (12.5%), III in 4 patients (7.1%), and IV in 6 patients (10.7%). The study was performed in all patients during the first week of the development of the infarct (range, 1 to 7 days; mean second day). A total of 18 patients (32%) were studied while on a ventilator. In 31 patients (55.4%) sedation was achieved with Midazolam or Propofol before beginning the study. In 54 studies, esophageal intubation was successfully achieved. In the 2 remaining cases, the test could not be performed due to lack of patient cooperation. In no case could the study not be performed due to anatomic or functional anomalies that made passage of the transesophageal probe impossible.

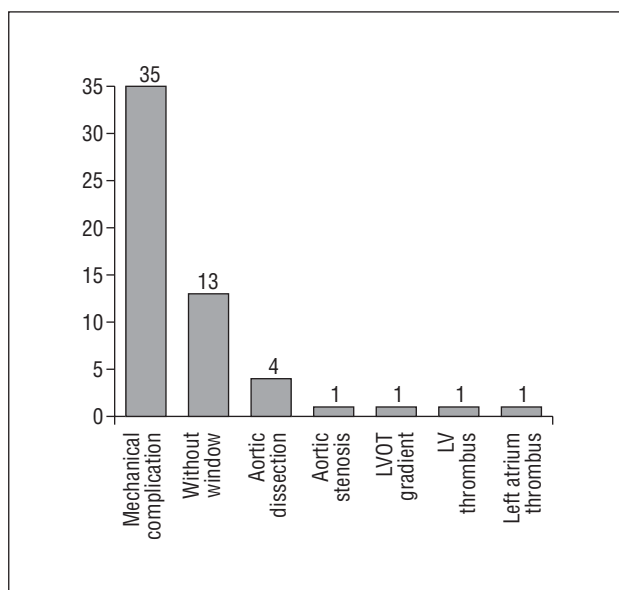
## Indications

The indications for performance of the TEE were as follows (Figure 1): suspected post acute myocardial infarct mechanical difficulties and detection of severe mitral insufficiency (in the case of the suspected mechanical difficulties it was determined to be mitral insufficiency) in 35 studies (62.5%), the lack of a transthoracic echocardiography window in patients who required adequate cardiac structural and functional assessment to optimize management in 13 cases (23.2%), suspected aortic dissection in 4 cases (7.1%), detection of severe aortic stenosis in one patient (1.8%), assessment of the gradient of the left ventricle outlet tract in one case (1.8%), determination of the presence of thrombi in the left ventricle in one case (1.8%), and ruling out the possibility of thrombus in the left cavities before performing electrocardioversion in one patient (1.8%).

## TEE vs TTE

We found the following results in patients with a suspected mechanical complication post-acute myocardial infarct: rupture of the left ventricle free





**Fig. 1.** Indications for transesophageal echocardiography. LVOT indicates left ventricle outlet tract; LV, left ventricle; LA, left atrium.

wall in 2 of the 3 patients studied in order to rule out a rupture. The diagnosis of a rupture of the left ventricle free wall was established in accordance with clinical criteria (electromechanical disassociation followed by syncope and death), hemodynamic criteria (arterial hypotension and increase in jugular venous pressure), and echocardiography criteria (pericardial leakage of more than 5 mm with dense interior echoes, compromising the cardiac cavities),<sup>7</sup> as none of the families authorized an autopsy on the deceased patient. The diagnosis of a rupture by means of direct visualization of the point of rupture is extremely difficult to establish.<sup>7</sup>

Of the 15 patients studied for suspected interventricular communication, with inconclusive data on TTE, 12 had positive results (3 ruptures located in the anteroapical area of the interventricular septum and 9 in the posterior wall), and in 3 patients this diagnosis was ruled out. Of the patients studied with the aim of ruling out the presence of papillary muscle changes and assessing the degree of severity of mitral regurgitation (n=17), in 2 patients we observed a partial rupture of the posteromedial papillary muscle and in the remaining patients the valve insufficiency was attributed to dilatation of the mitral ring, without structural anomalies of the valve or valve lining or of the sub valve apparatus. The TTE (note: this appeared as TEE in the text; I believe it should be TTE) was not diagnostic for the rupture of papillary muscles in either of the 2 cases that were later confirmed by TEE.

Another interesting aspect is the usefulness of TEE for rating the seriousness of valvulopathies. When we analyzed all the TEE results for patients with mitral

insufficiency (n=17) disregarding etiology and comparing the results with those obtained from TTE studies, we observed that TTE only correctly measured the severity of mitral regurgitation in 7 cases (41.2%). In 4 cases (23.5%), the severity could not be evaluated by TTE, and in another 6 cases (35.3%) the degree of severity obtained by TTE differed from that found on TEE.

In the group of patients with suspected aortic dissection, the existence of this disorder was confirmed in one patient, and in the remaining 3 patients it was definitively ruled out. The dissection was a Stanford type A that could not be diagnosed with TTE. The transesophageal study was performed secondary to a clinical suspicion of aortic dissection.

In 1 patient, the indication for a transesophageal study was to rule out the presence of thrombi in the left atrial opening as a first step prior to performing an electrocardioversion.

The severity of aortic stenosis was estimated by TEE in one case, when it was not possible to establish the severity of the lesion by TTE, which was able to be determined by TEE.

## Complications

It is important to point out that in 2 cases (3.6%) patient death followed administering the TEE. Neither of the 2 patients was intubated and both were sedated with intravenous benzodiazepines. The first patient was a 69-year-old man with a partial rupture of the posteromedial papillary muscle that produced severe mitral regurgitation, who was in a state of cardiogenic shock as a result of an inferoposterior AMI. This patient died immediately upon completing the TEE, on the third day of the development of the AMI, due to a sudden worsening of his state of shock, and after suffering asystole that was refractory to resuscitation attempts. The second case was a 75-year-old man with an anterior AMI and a murmur suggestive of interventricular communication. Death occurred on the second day after developing the AMI while the patients was being probed because of cardiorespiratory arrest from electromechanical dissociation due to an acute rupture of the left ventricular free wall diagnosed per the clinical, hemodynamic, and echocardiography changes previously described, and resuscitation attempts were fruitless. We could not perform an autopsy on either patient as this was not authorized by the patients' families. No significant complications developed in any other patients.

## DISCUSSION

In our analysis, 32 of the 56 transesophageal echocardiograms performed either established a diagnosis or gave an exact indication of the level of



severity of a lesion, which could not have been determined with transthoracic echocardiography. On only two occasions we were unable to perform the study due to lack of patient cooperation. There are many published articles analyzing the safety of TEE both in the general population<sup>8</sup> and in patients who are in critical condition, including cardiac and noncardiac patients,<sup>2,3,5,6,8,9</sup> but, as far as we know, there has been no study of the usefulness and safety of using this technique in patients during the acute phase of a myocardial infarction. The aim of our descriptive analysis is to address this point.

The most frequent indication for TEE in our study was to rule out the presence of mechanical complications associated with an AMI. Among these complications, assessment of the state of the mitral subvalve and, at the same time, the level of severity of mitral insufficiency, were the most frequent reasons for the study. In our center we routinely check for the presence of a rupture of the papillary muscles in all patients with mitral regurgitation during the first days of a myocardial infarction. Our results confirm the findings of other authors that the transesophageal technique is superior to the transthoracic technique, both for diagnosing the presence of subvalve changes and for evaluating the severity of valve regurgitation,<sup>10</sup> especially when the jet is eccentric. We must take into account that the mechanism that produces mitral regurgitation is not always related to the ischemic event that brought the patient to the coronary care unit, as the patients included in the register on many occasions have a history of cardiac illness. Therefore, it is not strange that patients present with insufficiency secondary to dilatation of the mitral ring that is not caused by the event in question, but by previous heart disease.

The second most frequent motive for performing a TEE according to our study was the absence of an adequate transthoracic window that would allow for acquiring sufficiently high-quality images to establish or rule out the diagnosis in patients in whom an adequate cardiologic structural-functional assessment is needed to optimize treatment. We must not forget that, in coronary care units, the patients involved are in many cases critically ill, are subjected to hemodynamic and echocardiography monitoring, and are sometimes on ventilators. All this, in addition to a lack of cooperation from these patients, means that the transthoracic technique does not allow for the acquisition of quality images. Given the impracticality of using this tool, other diagnostic imaging techniques must be used; because of the structural and functional data it provides, as well as its speed and the fact that it can be performed at bedside, the TEE is technique of choice. This technique may be indicated less and less with the advent of new techniques such as second harmonic imaging.

The third most frequent indication for use of TEE is the need to rule out aortic dissection, either associated with an acute infarct or an illness, as the differential diagnosis for an event of acute chest pain. TEE is the technique of choice for the diagnosis of this type of illness.<sup>11,12</sup> Although an aortic dissection was diagnosed on only one occasion, we must take into account that it is also very important to rule out its presence. When aortic dissection is suspected it is essential to determine whether it is present or not, as the administration of thrombolytic and anticoagulant agents could be lethal. In addition, TEE can provide decisive information for treatment of these patients.

On one occasion, we used TEE to detect thrombi in the atrium of left cavities before performing electrocardioversion. There is broad application of TEE in this setting, as it is the diagnostic tool of choice. In another patient, the indication was to determine the level of severity of aortic valve stenosis, and in another patient, to determine the extent of aortic subvalve stenosis, situations in which TEE is widely used when transthoracic images are not definitive.<sup>13</sup>

One of the most relevant findings of our study was the safety of this technique. We must point out that 2 patients died during or immediately after performing TEE. The safety of TEE has been studied both in populations of nonselected patients and in patients who are critically ill. Nevertheless, its use has not been specifically evaluated in patients in the acute phase of a myocardial infarction. The mortality rate is not inconsequential (3.6%), as is significantly higher than that described in nonselected patients (0.0098%)<sup>8</sup> or critically ill patients (0%-0.7%).<sup>2,5,6,9</sup> Although the amount of data is not sufficient to provide statistically significant results, we believe it is worth calling attention to the fact that on the 2 occasions when patients died, the TEE was performed to assess mechanical complications associated with a myocardial infarct; it would be interesting to keep registers of more cases in order to determine the safety of this procedure under these circumstances. At this time, we believe it would be prudent to be very selective as to which patients should be studied with TEE during the first week of treating a myocardial infarct.

We must emphasize that patients who are in the acute phase of an evolving myocardial infarction can be a high-risk group at the time a TEE is performed: in our center there were no cases of death during performance of a TEE procedure in critically ill or non-critically ill patients. Death only occurred in patients with a suspected mechanical complications, at a rate significantly higher than that reported in other studies of transesophageal studies in nonselected populations and in critically ill patient populations.<sup>2,5,6,8,9</sup>

In both cases where death occurred, the patients



were being studied to evaluate the existence and severity of mechanical complications post-acute myocardial infarction, and both patients were sedated and not intubated. The 1999 ACC/AHA clinical guidelines recommend avoiding the Valsalva maneuver in patients during the acute phase of a myocardial infarction.<sup>14</sup> It is possible that the Valsalva maneuver caused by esophageal intubation could have been the mechanism that triggered death in these patients, because of an increase in the parietal pressure that the rupture of the free wall or papillary wall produced. We must, therefore, keep this fact in mind and avoid any procedure that causes a Valsalva maneuver. The appearance of cardiac complications as a result of placing the left ventricle under significant stress has been described in other studies.<sup>15,16</sup>

We believe it would be interesting to start a comprehensive multicenter register to show the safety of transesophageal echocardiography in these circumstances, and how to avoid these dangers. Until we have results that give a clear indication of the dangers, it would be wise to be extremely careful in the selection of patients who are to undergo a TEE during the acute phase of a myocardial infarct.

## Study limitations

We believe the 2 principal limitations of our study are that it is a retrospective study and we cannot be sure that some patients were not included in the study. On the other hand, the number of patients is not very large, although we must take into account the number of transesophageal studies performed on patients with the same characteristics as ours in other centers is also not very high.

## CONCLUSION

TEE is a very useful diagnostic tool for patients in the acute phase of a myocardial infarction in which TTE does not provide conclusive results. Nevertheless, until we have definitive studies available, we must advise caution in the use of this type of exploration in patients with suspected mechanical complications.

## REFERENCES

- García Fernández MA, Barambio Ruíz M, Pérez de Prado A, Moreno Yangüela M, González Torrecilla E, San Román Sánchez D, et al. Implicaciones clínicas y terapéuticas del ecocardiograma transesofágico en el paciente crítico. En: Iñiguez Romo A, editor. Tratado de terapéutica cardiológica. Madrid: Editorial Libro del Año, 1995; p. 505-12.
- Hwang JJ, Shyu KG, Chen JJ, Tseng YZ, Kuan P, Lien WP. Usefulness of transesophageal echocardiography in the treatment of critically ill patients. *Chest* 1993;104:861-6.
- Brandt RR, Oh JK, Abel MD, Click RL, Orszulak TA, Seward JB. Role of emergency intraoperative transesophageal echocardiography. *J Am Soc Echocardiogr* 1998;11:972-7.
- Lesbre JP. The main indications for transesophageal echocardiography. *Ann Cardiol Angeiol (Paris)* 1995;44:547-51.
- Cicek S, Demirlic U, Kuralay E, Tatar H, Ozturk O. Transesophageal echocardiography in cardiac surgical emergencies. *J Card Surg* 1995;10:236-44.
- Gendreau MA, Triner WR, Bartfield J. Complications of transesophageal echocardiography in the emergency department. *Am J Emerg Med* 1999;17:248-51.
- López-Sendón J, González A, López de Sá E, Coma-Canella I, Roldán I, Domínguez F, et al. Diagnosis of subacute ventricular wall rupture after acute myocardial infarction: sensitivity and specificity of clinical, hemodynamic and echocardiographic criteria. *J Am Coll Cardiol* 1992;19:1145-53.
- Daniel WG, Erbel R, Kasper W, Visser CA, Engberding R, Sutherland GR, et al. Safety of transesophageal echocardiography: a multicenter survey of 10,419 examinations. *Circulation* 1991;83: 817-21.
- Oh JK, Seward JB, Khandheria BK, Gersh BJ, McGregor CG, Freeman WK, et al. Transesophageal echocardiography in critically ill patients. *Am J Cardiol* 1990;66:1492-5.
- Oh JK, Seward JB, Tajik AJ. Transesophageal echocardiography. En: Oh JK, Seward JB, Tajik AJ, editors. *The echo manual*. 2nd ed. Philadelphia: New Cork Lippincott-Raven, 1999.
- Erbel R, Engberding R, Daniel W, Roelandt J, Visser C, Rennollet H, et al. Echocardiography in diagnosis of aortic dissection. *Lancet* 1989;1:457-61.
- Ballal RS, Nanda NC, Gatewood R, D'Arey B, Samdarshi TE, Holman WL, et al. Usefulness of transesophageal echocardiography in assessment of aortic dissection. *Circulation* 1991;84: 1903-14.
- Hoffmann R, Flachskampf FA, Hanrath P. Planimetry of orifice area in aortic stenosis using multiplane transesophageal echocardiography. *J Am Coll Cardiol* 1988;12:606-15.
- Ryan TJ, Antman EM, Brooks NH, Califf RM, Hillis LD, Hiratzka LF, et al. ACC/AHA guidelines for the management of patients with acute myocardial infarction: 1999 update: a report of the American College of Cardiology/American Heart Association Task Force on Practice Guidelines (Committee on Management of Acute Myocardial Infarction). [Consultado en diciembre de 2001]. Disponible en: <http://www.acc.org/clinical/guidelines> y <http://www.americanheart.org>.
- Zamorano J, Moreno R, Almería C, Serra V, Rodrigo J, Sánchez-Harguindey L. Rotura de la pared libre del ventrículo izquierdo durante prueba de estrés con dobutamina. *Rev Esp Cardiol* 2002; 55:312-4.
- Rodríguez García MA, Iglesias-Garriz I, Corral Fernández F, Garrote Coloma C, Alonso-Orcajo N, Branco L, et al. Evaluación de la seguridad de la ecocardiografía de estrés en España y Portugal. *Rev Esp Cardiol* 2001;54:941-8.