

Three-Dimensional Echocardiographic Assessment of Left Atrial Size and Function and the Normal Range of Asynchrony in Healthy Individuals

Francisco Azar,^a Leopoldo Pérez de Isla,^a Mar Moreno,^b Agustín Landaeta,^a Elena Refoyo,^b Teresa López Fernández,^b Carlos Macaya,^a and José Zamorano^a

^aUnidad de Imagen Cardiovascular, Hospital Clínico San Carlos, Madrid, Spain

^bUnidad de Imagen Cardiovascular, Hospital La Paz, Madrid, Spain

Left atrial size and function are very important prognostic factors. Our aim was to evaluate left atrial size, function, and mechanical synchrony using three-dimensional echocardiography in order to establish normal reference values. The study involved 63 healthy individuals enrolled at 2 hospitals. All underwent two-dimensional and three-dimensional echocardiography. Mechanical asynchrony was assessed by determining the standard deviation of the time each left atrial segment took to reach the minimum volume during atrial systole, normalized by the RR interval. The mean value for this normalized standard deviation was 15.4 (10.9). In conclusion, it is possible to analyze left atrial asynchrony, size and function using three-dimensional echocardiography.

Key words: Left atrium. Asynchrony. Three-dimensional echocardiography.

Evaluación de tamaño, función y rangos de normalidad de la asincronía de la aurícula izquierda en sujetos sanos mediante ecocardiografía tridimensional

El tamaño y la función de la aurícula izquierda tienen implicaciones pronósticas muy importantes. Nuestro objetivo fue evaluar el tamaño, la función y la sincronía mecánica de la AI mediante ecocardiografía tridimensional (eco-3D), para establecer los valores de referencia normales. Sesenta y tres sujetos sanos fueron estudiados en 2 hospitales. Todos ellos fueron sometidos a una ecocardiografía bidimensional (eco-2D) y eco-3D. Para la valoración de la asincronía, se obtuvo la desviación estándar del tiempo que cada segmento auricular emplea en alcanzar el mínimo volumen regional durante la sístole auricular, normalizado por el intervalo RR (IDS 16). El valor medio del IDS 16 fue 15,4 \pm 10,9. En conclusión, la asincronía, el tamaño y la función de la AI pueden ser analizados mediante eco-3D.

Palabras clave: Aurícula izquierda. Asincronía. Ecocardiografía tridimensional.

INTRODUCTION

Quantification of heart cavity parameters is an essential part of the echocardiographic examination. An enlarged left atrium (LA) is associated with various cardiovascular diseases¹⁻⁴ and the incidence of atrial fibrillation, cerebral ischemic events, and an increased risk of death. LA size is usually assessed with 2-dimensional echocardiography (2D-echo) and M-mode echocardiography.^{5,6} Recently, 3-dimensional echocardiography (3D-echo) has been included

in the clinical routine of many echocardiography laboratories, offering numerous advantages in the assessment and analysis of the heart cavities.

Our objective was to use 3D-echo to assess LA size, general function, and asynchrony in healthy individuals, in order to establish the normal reference values.

METHODS

Study Population

The study included 63 patients with no known cardiovascular disease or cardiovascular risk factors at 2 hospitals. The participants were hospital employees and patients who had no cardiac conditions or had been referred to rule out heart disease. All subjects were informed of the diagnostic techniques to be used and gave consent

Correspondence: Dr. J.L. Zamorano.
Unidad de Imagen Cardiovascular. Hospital Clínico San Carlos.
Prof. Martín Lagos, s/n. 28040 Madrid. España.
E-mail: jlzamorano@vodafone.es

Received May 6, 2008.

Accepted for publication November 12, 2008.

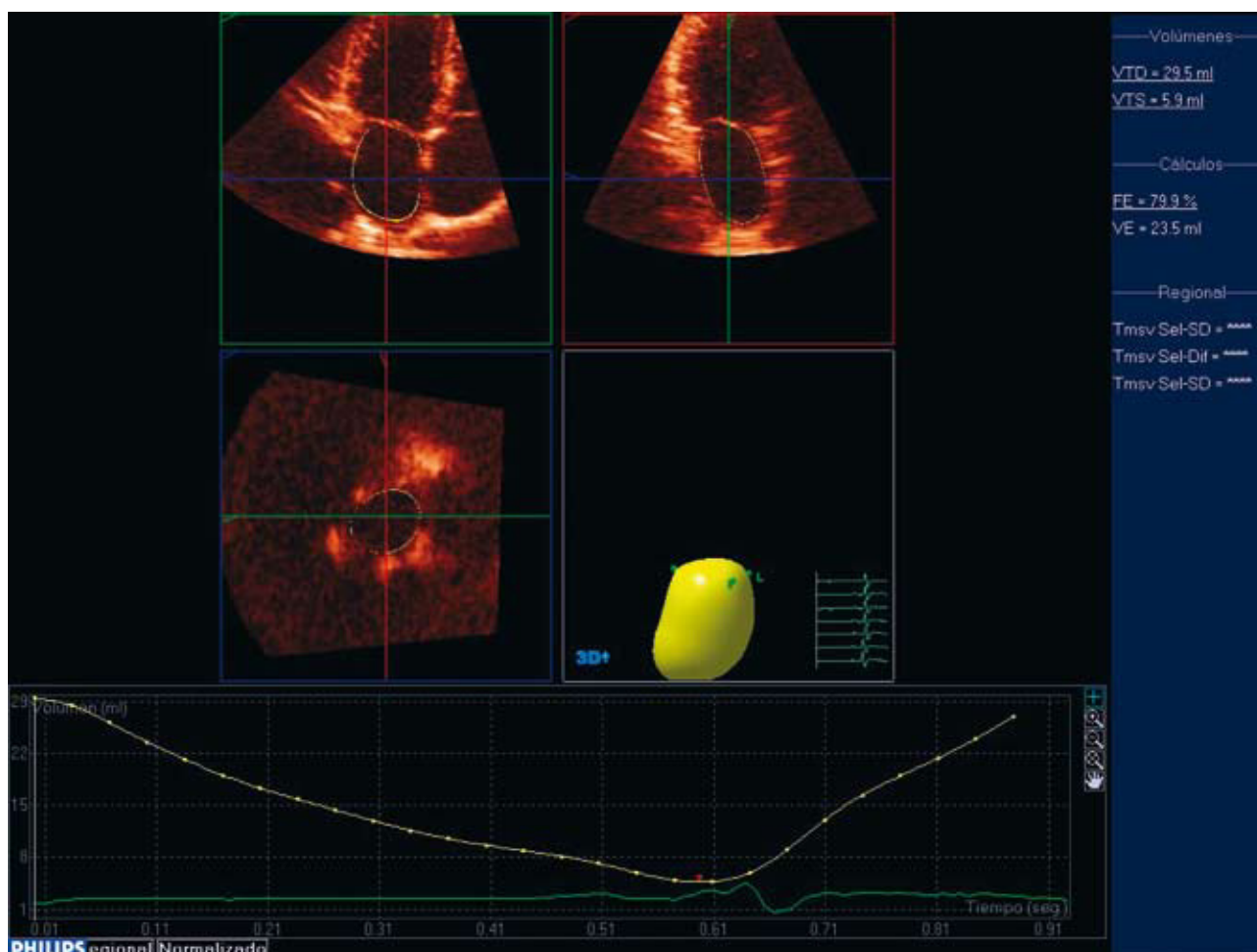


Figure 1. Analysis of left atrial volumes and overall function.

to participate. The studies were carried out by 4 observers, 2 at each participating site.

2D and 3D Echocardiographic Study

All patients underwent a 2D-echo study with a Philips IE-33 unit and S5-1 and X3-1 probes (Philips, Bothell, Washington, United States). 2D images of the LA were obtained using a parasternal long-axis and 4-chamber apical window.

The 3D-echo study was performed immediately after the conventional study. LA size, function, and synchrony were analyzed using the same computer application as that normally used to study the left ventricle (LV), applying delayed image acquisition to study atrial systole and diastole. A Philips X3-1 ultrasound probe (Philips, Bothell, Washington, United States) was used for the study. The system allows “full-volume” imaging. The 3D images were acquired from the apical window, stored on a main

server, and analyzed off-line using the QLAB 6.0 software (Philips, Bothell, Washington), and LA systolic and diastolic volume and the ejection fraction were measured (Figures 1 and 2). This computer application automatically divides LA volume into 17 segments and obtains the end-diastolic and end-systolic volumes and the ejection fraction for each segment. The application also obtains the R-R interval normalized standard deviation of time to minimum volume for 16 segments (Tmsv-16 SD). The theoretical “apex” of the atrium was located in the LA roof and the reference point for automatic segmentation was left by default in the place predefined by the software. The field that represents the atrial roof was excluded from this analysis. The left atrial appendage was always excluded, and the orifices of the pulmonary vein were not taken into account. The imaging parameters were adjusted to obtain the best time resolution possible in each patient.

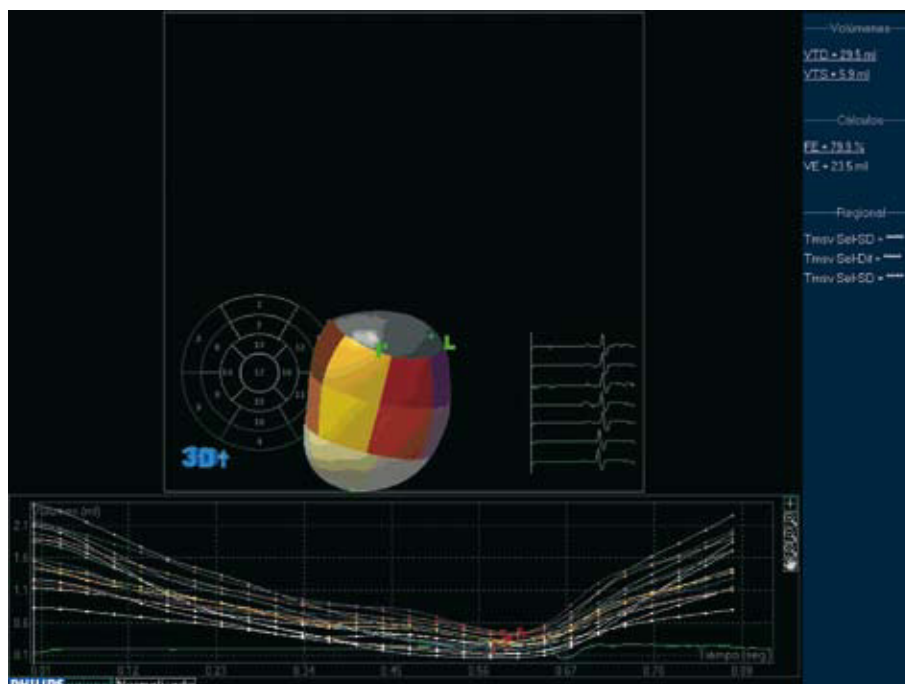


Figure 2. Analysis of regional function and assessment of left atrial asynchrony.

Statistical Methods

The statistical program used was SPSS version 11.0 (SPSS Inc., Chicago, Illinois, United States). Quantitative data are expressed as the mean (SD), corrected by the R-R, and qualitative data as the absolute number (percentage). The Tmsv-16 SD measurements were repeated in the first 20 patients by a second observer and by the first observer in a second step to perform the inter-observer reproducibility analysis and in 1 observer using the intraclass correlation coefficient. The Kolmogorov-Smirnov test was used to confirm normal distribution of the data.

RESULTS

The 63 participants had an average age of 50.53 (21.1) years (median, 48 years; interquartile range, 33.25 years) and 35 were men (55.6%). No subjects were excluded due to a poor acoustic window. The mean duration of acquisition and analysis was 12.3 (5.1) minutes per patient in the first 20 patients included.

The average LA diameter obtained by 2D-echo was 42.4 (11.6) mm; the mean left atrial end-diastolic volume assessed by 3D-echo was 48.9 (25.1) mL and the mean left atrial end-systolic volume obtained by 3D-echo was 62.3 (17.2) mL. The M-mode diameters and the mean LA end-diastolic and end-systolic volumes indexed by body surface area assessed by 3D-echo were 21.6 (6.4) mm/m², 23.9 (6.1) mL/m²,

and 9.7 (4.2) mL/m², respectively. The mean LA ejection fraction was 62.3% (17.2%) (Table).

Tmsv 16-SD was the last variable studied, with a mean value of 15.4 (10.9) (Table). The inter-observer and intra-observer agreement study for Tmsv 16-SD determination yielded an intraclass correlation coefficient of 0.82 and 0.79, respectively. Analysis of the linear association between the indexed LA volume and the Tmsv 16-SD gave a simple linear regression coefficient of only 0.3.

DISCUSSION

Left atrial enlargement is a risk predictor of cardiovascular events, and various studies have shown that 3D-echo is superior to 2D-echo in the assessment of LV function.⁷ Nevertheless, little is known about the role that atrial asynchrony may have on the assessment of healthy subjects and patients with heart disease. In this context, our study may be relevant because knowledge of the reference values in healthy patients could later be applied to the different pathologies.

Few studies have analyzed atrial asynchrony^{8,9}; the majority focus on interatrial asynchrony. Among the small number that analyze intra-atrial asynchrony, a trial by van Beeumen et al⁹ showed that patients with heart failure assessed by color Doppler have considerable right interatrial and intra-atrial asynchrony, which is related to elevated natriuretic peptide concentration.

Normal Left Atrial Reference Values Determined by With Three-Dimensional Echocardiography

Variable	Mean (SD)	Median	Interquartile Range
LA, mm	42.4 (11.6)	40	13
LA EDV, mL	48.9 (25.1)	43	20
LA EDV, mL	20.3 (18.4)	13.8	19.9
LA ESV, 2D-echo (Simpson)	51.2 (26.4)	44	21
LA EDV, 2D-echo (Simpson)	21.8 (19.3)	12	20
LAEF, %	62.3 (17.2)	61	21
Tmsv 16-SD, %	15.4 (10.9)	12	9

LA indicates left atrial diameters obtained in a parasternal long-axis view; LA EDV, left atrial end-diastolic volume; LA ESV, left atrial end-systolic volume; LAEF, left atrial ejection fraction; SD, standard deviation; Tmsv 16-SD, R-R interval normalized standard deviation of time to minimum volume for 16 LA segments.

The results of the present study are an initial approach to the use of 3D-echo for studying atrial asynchrony.

Limitations

The main limitation of this study was that the 3D-echo analysis of the LA was performed using a computer application designed for the LV. Another limitation is the limited frame-rate used by this system. Moreover, due to the relatively small number of patients, no analysis stratified by age and sex was carried out.

Nevertheless, we should highlight the fact that no technique is currently considered a reference method to study atrial asynchrony.

In conclusion, LA asynchrony, size, and function can be studied by 3D-echo. Our results provide, for the first time, atrial synchrony reference values for healthy subjects.

REFERENCES

1. Tsang TS, Barnes ME, Gersh BJ, Takemoto Y, Rosales AG, Bailey KR, et al. Prediction of risk for first age-related cardiovascular events in elderly population: the incremental value of echocardiography. *J Am Coll Cardiol.* 2003;42:1199-205.
2. Tsang TS, Barnes ME, Gersh BJ, Bailey KR, Seward JB. Left atrial volume as a morphophysiology expression of left ventricular diastolic dysfunction and relation to cardiovascular risk burden. *Am J Cardiol.* 2002;90:1284-9.
3. Kizer JR, Bella JN, Palmieri V, Liu JE, Best LG, Lee ET, et al. Left atrial diameter as an independent predictor of first cardiovascular events in middle-aged and elderly adults: the strong heart study. *Am Heart J.* 2006;151:412-8.
4. Simek CL, Feldman MD, Haber HL, Wu CC, Jayaweera AR, Kaul S. Relationship between left ventricular wall thickness and left atrial size: comparison with other measures of diastolic function. *J Am Soc Echocardiogr.* 1995;8:37-47.
5. Lang RM, Bierig M, Devereux RB, Flachskampf FA, Foster E, Pellikka PA, et al. Chamber Quantification Writing Group. American Society of Echocardiography's Guidelines and Standards Committee, European Association of Echocardiography. Recommendations for Chamber quantification. A report from the American Society of Echocardiography's Guidelines and Standards Committee and the Chamber Quantification Writing Group, developed in conjunction with the European Association of Echocardiography, a branch of the European Society of Cardiology. *J Am Soc Echocardiogr.* 2005;18:1440-63.
6. Lester SJ, Ryan EW, Schiller NB, Foster E. Best method in clinical practice and in research studies to determine left atrial size. *Am J Cardiol.* 1999;84:829-32.
7. Hung J, Lang R, Flachskampf F, Shernan SK, McCulloch ML, Adams DB, et al. 3D Echocardiography: A review of the current status and future directions. *J Am Soc Echocardiogr.* 2007;20:213-33.
8. Wang Z, Tan H, Zhong M, Jiang G, Zhang Y, Zhang W. Strain rate imaging for noninvasive functional quantification of the left atrium in hypertensive patients with paroxysmal atrial fibrillation. *Cardiology.* 2008;109:15-24.
9. van Beeumen K, Duytschaever M, Tavernier R, van de Veire N, De Sutter J. Intra- and interatrial asynchrony in patients with heart failure. *Am J Cardiol.* 2007;99:79-83.