

3. Amarencu P, Cohen A, Tzourio C, Bertrand B, Hommel M, Besson G, et al. Atherosclerotic disease of the aortic arch and the risk of ischemic stroke. *N Eng J Med*. 1994;331:1474.
4. Pujadas R, Arboix A, Anguera N, Oliveres M, Massons J, Comes E. Papel de las placas complejas de ateroma aórtico en la recurrencia del infarto cerebral de etiología incierta. *Rev Esp Cardiol*. 2005;58:34–40.
5. Tunick PA, Nayar AC, Goodkin GM, Mirchandani S, Francescone S, Rosenzweig BP, et al. Effect of treatment on the incidence of stroke and other emboli in 519

- patients with ischemic stroke. FAPS investigators. French Study of Aortic Plaques in Stroke. *Am J Cardiol*. 2002;90:1320–5.
6. Pujadas R, Oliveras M, Jané X. Complex Atheromatosis of the Aortic Arch in Cerebral Infarction. *Current Cardiology Reviews*. 2010;6:184.

<http://dx.doi.org/10.1016/j.rec.2013.10.009>

Transcatheter Aortic Valve Replacement With a Balloon-expandable Valve for the Treatment of Noncalcified Bicuspid Aortic Valve Disease



Reemplazo percutáneo de la válvula aórtica con una válvula de balón expandible para el tratamiento de la enfermedad valvular aórtica bicúspide no calcificada

To the Editor,

A 71-year-old woman diagnosed with symptomatic aortic stenosis (exertional dyspnea, New York Heart Association class III) and hostile chest was referred to our hospital for transcatheter aortic valve replacement (TAVR). She had undergone off-pump coronary bypass artery grafting several years previously, complicated with severe mediastinitis and sternal dehiscence requiring surgical intervention and chest reopening. She also had systemic arterial hypertension, type 2 diabetes, peripheral vascular disease, and chronic renal failure leading to an estimated risk of perioperative mortality of 21% and 6% as assessed by Logistic EuroSCORE and Society of Thoracic Surgeons score, respectively. The echocardiographic examination revealed a noncalcific bicuspid aortic valve with severe stenosis (mean gradient, 41 mmHg; valve area as assessed by the continuity equation, 0.54 cm²) (Figure A), and a left ventricular ejection fraction of 60%. A multidetector computed tomography confirmed severe thickening of the leaflets and the absence of calcium on the aortic valve (Figure B), severe calcification of the ascending aorta without significant dilatation (Figure B) and severe peripheral vascular disease with concentric calcification of both iliofemoral arteries and a minimal luminal diameter of 5.5 and 4.7 mm in the right and left side, respectively. The patient was deemed unsuitable for standard aortic valve surgery by the heart team, and TAVR using the transapical approach was proposed. The case was approved by the Special Access Program for compassionate clinical use of Health Canada, and the patient provided signed informed consent for the procedure. According to the assessment of the dimensions of the aortic annulus by multidetector computed tomography (21 x 27 mm; area, 4.7 cm²), a 26-mm balloon-expandable Edwards SAPIEN-XT valve (Edwards Lifesciences, Irvine, California, United States) was selected and, following balloon valvuloplasty with a 20-mm balloon, the transcatheter valve was successfully implanted (Figure C). The echocardiographic examination post-TAVR showed the

absence of residual aortic regurgitation (Figure D) and a valve area of 1.31 cm². At 1-month follow-up, a multidetector computed tomography showed both the adequate positioning and uniform expansion of the bioprosthesis (Figure E). Valve hemodynamics remained unchanged and the patient was asymptomatic at the 9-month follow-up.

Bicuspid aortic valve disease (BAVD) is the most common congenital heart defect and the first cause of aortic stenosis requiring aortic valve replacement. Although most cases occur in calcified valves, severe aortic stenosis in BAVD may occur in thick and fibrous valves lacking calcium, which is more frequent in younger patients.

Both the presence of a BAVD and the absence of calcium on the aortic valve are contraindications for TAVR¹ due to the potential risk of valve dislodgment. Valve calcification is considered to be a necessary condition for the anchoring of the valve stent frame, which might be even more relevant with the use of balloon-expandable valves. However, studies in animal models have shown that an accurate sizing of the valve with a higher degree of prosthesis oversizing may prevent device migration in valves without calcium.²

The use of self-expandable bioprostheses in noncalcified aortic valves allows a high oversizing with a minimal risk of annulus rupture. Nonetheless, the higher radial force of the balloon-expandable valves³ may allow an appropriate anchoring of the bioprosthesis in noncalcified valves with less oversizing.² In this case, a relative oversizing of 13% (within the recommended range of 10%–15%) was enough to prevent bioprosthesis embolization,⁴ but future studies will have to determine the degree of oversizing which should be used in these cases. Also, the eccentricity of the aortic annulus and the severe thickness of the leaflets in this patient might have contributed to resistance to migration forces. Moreover, the use of self-expandable bioprostheses in patients with BAVD has been associated with a greater eccentricity,⁵ which in turn might lead to a higher peak stress on the leaflets and a higher risk of central and paravalvular leak.⁶

Several series have reported the feasibility of TAVR in patients with calcified BAVD.⁵ However, this report shows for the first time that TAVR with the use of balloon-expandable valves can be successfully performed for the treatment of noncalcified BAVD, suggesting that TAVR might be a therapeutic alternative in selected patients with congenital aortic valve disease without valve calcification. Further studies are warranted.

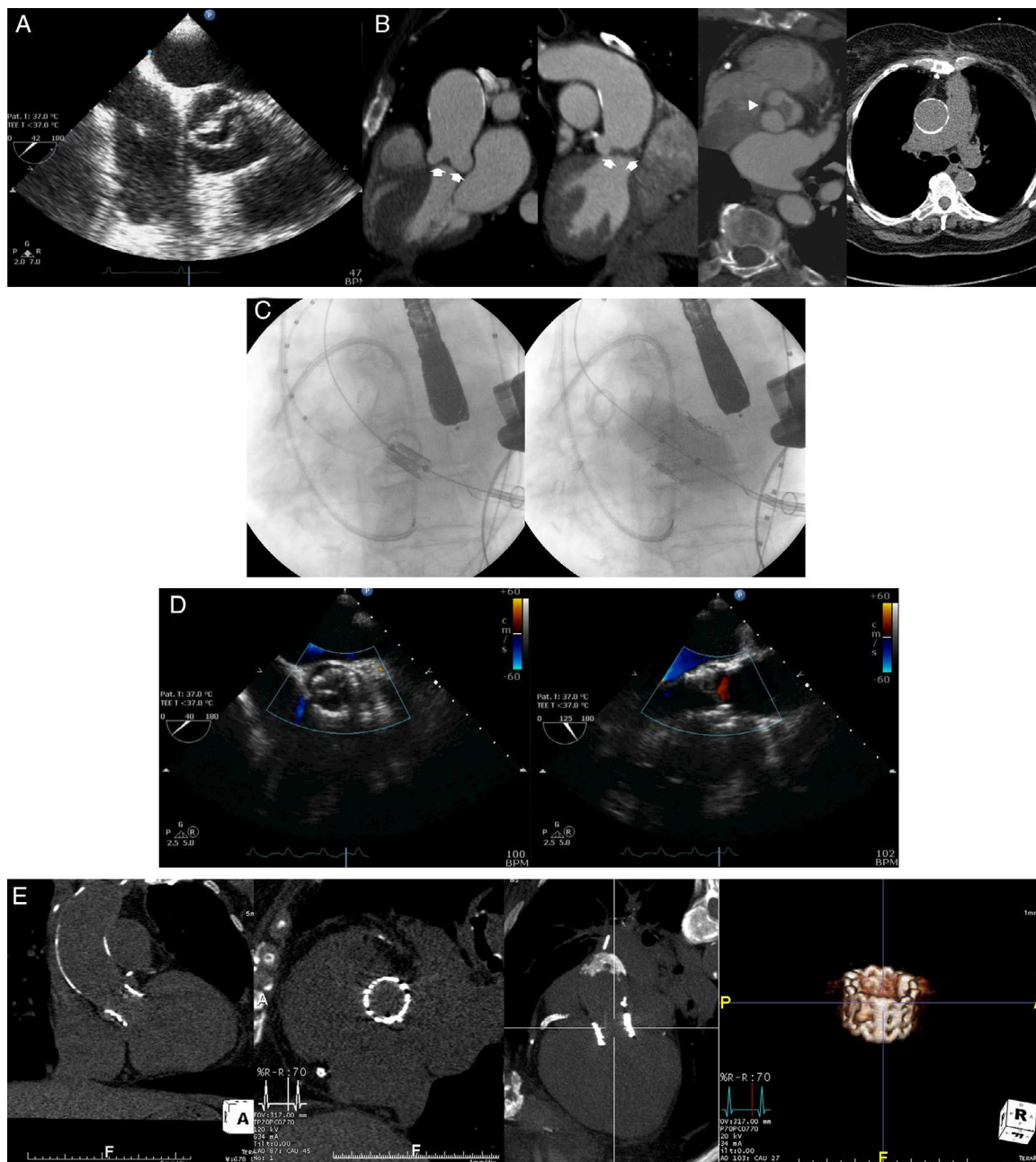


Figure.. A: transesophageal echocardiography mid-esophageal aortic short axis view showing a noncalcific bicuspid aortic valve. B: computed tomography images assessing the aortic valve and ascending aorta: coronal oblique reconstructions showing the absence of calcium on the aortic valve and the severe thickness of the cusps (arrows) and double oblique transverse view showing the presence of a thick raphe (arrowhead) and the asymmetric opening of the aortic valve; axial view displaying a severe calcified ascending aorta. C: fluoroscopic images showing the positioning, using a pigtail catheter placed on the aortic valve as reference, and deployment of a 26-mm balloon-expandable valve by transapical approach. D: postprocedural transesophageal echocardiography mid-esophageal long-axis and short-axis views showing the absence of residual aortic regurgitation. E: 30 days post implantation computed tomography coronal and sagittal views, coronal oblique reconstruction views and volume-rendered image showing the complete expansion and correct positioning of the stent valve.

CONFLICTS OF INTEREST

Dr Josep Rodés-Cabau is consultant for Edwards Lifesciences and St-Jude Medical. Dr. Eric Dumont is consultant for Edwards Lifesciences

Marina Urena,^a Daniel Doyle,^b Eric Dumont,^b Henrique Barbosa Ribeiro,^a Sylvie Bilodeau,^c and Josep Rodés-Cabau^{a,*}

^aDepartment of Cardiology, Quebec Heart & Lung Institute, Laval University, Quebec, Canada

^bDepartment of Cardiac Surgery, Quebec Heart & Lung Institute, Laval University, Quebec, Canada

^cDepartment of Radiology, Quebec Heart & Lung Institute, Laval University, Quebec, Canada

*Corresponding author:

E-mail address: josep.rodés@criucpq.ulaval.ca (J. Rodés-Cabau).

Available online 28 February 2014

REFERENCES

1. Holmes Jr DR, Mack MJ, Kaul S, Agnihotri A, Alexander KP, Bailey SR, et al. 2012 ACCF/AATS/SCAI/STS expert consensus document on transcatheter aortic valve replacement. *J Am Coll Cardiol*. 2012;59:1200–54.
2. Mummert J, Sirois E, Sun W. Quantification of biomechanical interaction of transcatheter aortic valve stent deployed in porcine and ovine hearts. *Ann Biomed Eng*. 2013;41:577–86.
3. Tzamtzis S, Viquerat J, Yap J, Mullen MJ, Burriesci G. Numerical analysis of the radial force produced by the medtronic-corevalve and edwards-sapien after transcatheter aortic valve implantation (TAVI). *Med Eng Phys*. 2013;35:125–30.
4. Achenbach S, Delgado V, Hausleiter J, Schoenhagen P, Min JK, Leipsic JA. SCCT expert consensus document on computed tomography imaging before transcatheter aortic valve implantation (TAVI)/transcatheter aortic valve replacement (TAVI). *J Cardiovasc Comput Tomogr*. 2012;6:366–80.
5. Hayashida K, Bouvier E, Lefevre T, Chevalier B, Hovasse T, Romano M, et al. Transcatheter aortic valve implantation for patients with severe bicuspid aortic valve stenosis. *Circ Cardiovasc Interv*. 2013;6:284–91.
6. Sun W, Li K, Sirois E. Simulated elliptical bioprosthetic valve deformation: Implications for asymmetric transcatheter valve deployment. *J Biomech*. 2010;43:3085–90.

<http://dx.doi.org/10.1016/j.rec.2013.10.014>

Initiation of an Inter-hospital ECMO Transfer Program for Patients Suffering From Severe Acute Heart and/or Pulmonary Failure



Experiencia inicial de un programa de transporte interhospitalario con ECMO para pacientes con insuficiencia cardiaca aguda y/o insuficiencia respiratoria grave

To the Editor,

Extracorporeal membrane oxygenators (ECMO) are an efficient means of providing emergency pulmonary and circulatory support for patients with cardiogenic shock refractory to conventional intensive therapy or hypoxic-hypercapnic respiratory failure refractory to advanced ventilation strategies.^{1,2}

Currently, ECMO use is limited to certain specialized tertiary centers that are both equipped to implement programs and experienced in their management. Hospitals that cannot undertake heart surgery or initiate ECMO find it extremely difficult to treat patients in refractory cardiogenic shock. Transferring patients to centers with better technical resources can be the only alternative but is often considered inviable due to their hemodynamic instability. Recent experience confirms that creating mobile heart surgery units—where support devices can be implanted in situ, followed by stabilization and transfer to a specialized center—offers these critical patients a chance of survival.^{3–5}

The objective of the present study is to determine the feasibility and safety of an inter-hospital transfer program for critical patients with ECMO support. We describe the logistic problems, indications, complications, and clinical course of the patients enrolled.

The Cardio-Thoracic Surgery Service of the J.W. Goethe University Hospital, Frankfurt, Germany, established a Distance Cardiac Care Unit to provide ECMO circulatory support for institutions in the Hessen area lacking this therapeutic resource. The unit was created in December 2011 and consists of a perfusionist and a heart surgeon permanently on call and in direct contact with the secondary hospitals' critical care units.

Veno-arterial ECMO support implantation was indicated in cases of cardiogenic shock refractory to conventional critical care treatment (systolic blood pressure under 80 mmHg, administration of at least two inotropic agents, and/or counterpulsation balloon and signs of inadequate perfusion).^{1,2} Veno-venous support was indicated in cases of hypoxic-hypercapnic respiratory failure refractory to advanced ventilation strategies (respiratory distress syndrome).^{1,6}

We used the PLS extracorporeal system (Maquet AG; Germany), consisting of a closed polyvinyl circuit, membrane oxygenator and centrifugal pump. The patient was intubated using percutaneous venous cannulas (17–25 Fr) and arterial cannulas (18–21 Fr). In patients with respiratory failure only, veno-venous ECMO support was established by using the Seldinger technique of inserting cannulas in both femoral veins, lodging one in the right atrium (outflow) and the other in the inferior vena cava (inflow). In cases of cardiogenic shock, veno-arterial ECMO support was surgically implanted in the deltopectoral groove giving access to the axillary artery to connect the arterial line and a venous cannula inserted percutaneously in the inferior vena cava. Procedures were performed under general anesthetic in the patient's intensive care unit bed, after administering 10 000 U heparin.

Table 1

Demographic Characteristics of Patients Enrolled. Causes of Cardiorespiratory Failure. Indications for ECMO and ECMO Support Type

Patient	Sex	Age	Etiology	Indication for support	Type of support
1	W	18	Drowning; immersion syndrome	CS + RDS	V-A
2	M	36	Attempted suicide by drug overdose; pneumonia due to aspiration	RDS	V-V
3	M	58	Acute myocarditis	CS	V-A
4	M	46	Pneumonia caused by <i>Influenza A</i>	RDS	V-V
5	M	43	Pneumonia caused by staphylococcus; right heart failure	CS + RDS	V-A
6	M	61	Acute myocardial infarction	CS	V-A
7	W	46	Pneumonia caused by <i>Influenza</i>	RDS	V-V
8	M	60	Pneumonia caused by <i>Influenza A</i>	RDS	V-V
9	M	55	Pneumonia caused by aspiration	RDS	V-V
10	M	52	Pneumonia caused by <i>Influenza</i>	RDS	V-V

CS, cardiogenic shock; ECMO, extracorporeal membrane oxygenator; M, man; RDS, respiratory distress syndrome; V-A, veno-arterial ECMO; V-V, veno-venous ECMO; W, woman.