

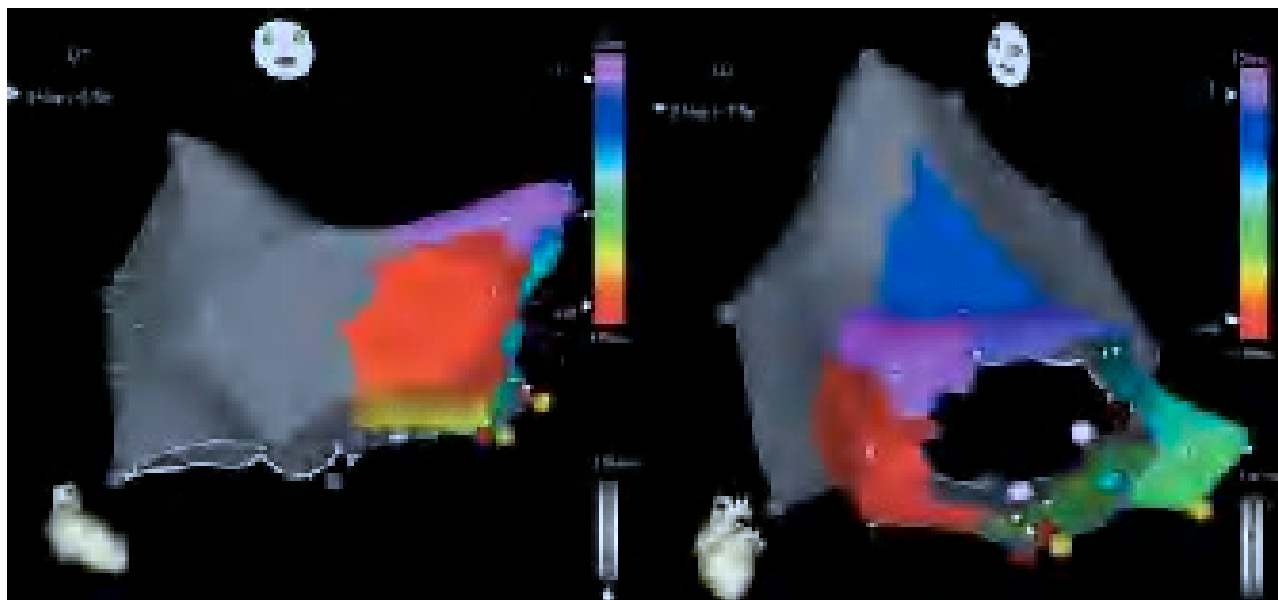Figure 1.

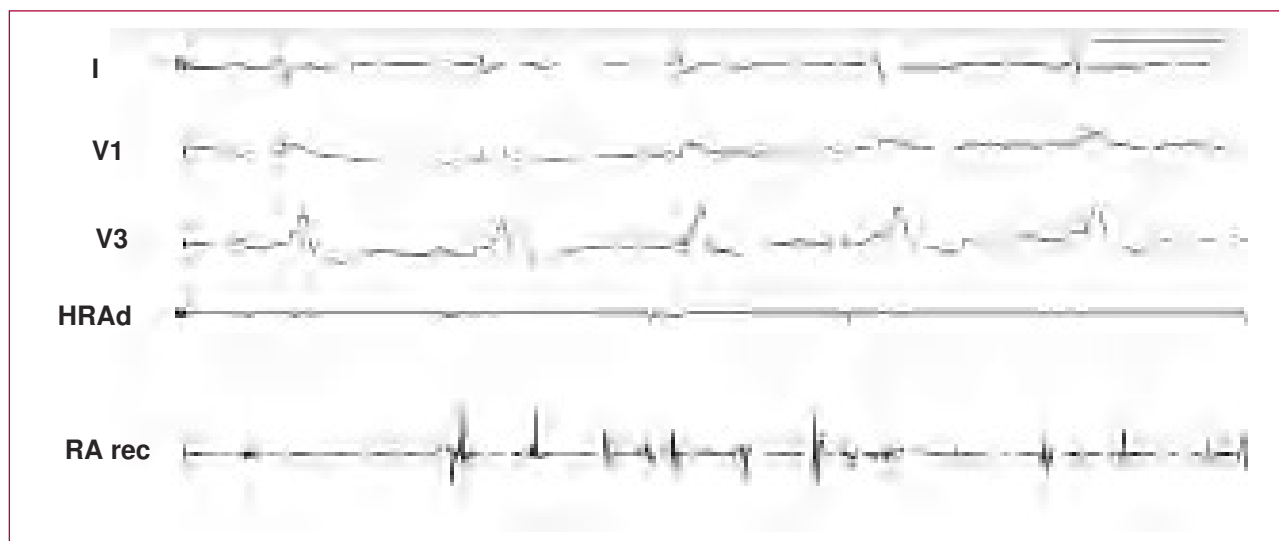


Figure 2.

## Typical Atrial Flutter in the Transplanted Heart

Atrial flutter is the most frequent arrhythmia occurring in patients who have undergone orthotopic heart transplantation. We present a representative case of typical atrial flutter with counterclockwise rotation around the tricuspid ring in a female patient who had received an orthotopic heart transplant 13 years before. The arrhythmia pattern seen on the activation map (Figure 1) shows the convergence between the earliest and latest areas, a characteristic of macroreentry.

The area corresponding to the recipient atrium, shown as "scar tissue" (in gray), presented atrial tachysystole with a slightly slower cycle length than the atrium with the flutter

and was unrelated to it. This visual differentiation between the 2 atria allowed more precise delimitation of the area where they were joined (suture) and, more importantly, the area of the cavotricuspid isthmus belonging to the donor atrium and under consideration for ablation.

Figure 2 shows the donor atrium (HRAd) in sinus rhythm following ablation and the recipient atrium (RA rec) in atrial tachysystole.

Víctor Bazán Gelizo, Enrique Rodríguez Font,  
and Xavier Viñolas Prat

Servicio de Cardiología, Hospital de la Santa Creu i Sant Pau,  
Barcelona, Spain.