

Unusual Cyanosing Heart Defect Due to Supravalvular Tricuspid Obstruction in an Infant

Juan C. García López,^a Inmaculada Sánchez Pérez,^b Mario Cazzaniga,^b Julio Pérez de León,^b and Carmen C. González Diéguez^b

^aServicio de Cardiología, Hospital Universitario de Getafe, Madrid, Spain.

^bServicio de Cardiología Pediátrica y Cirugía Cardíaca Pediátrica, Hospital Ramón y Cajal, Madrid, Spain.

We present a case involving a rare form of cyanotic congenital heart disease in a 2-month-old neonate. The initial diagnosis was thought to be tricuspid dysplasia with right-to-left shunting through an interatrial communication. However, surgery showed the presence of a pedunculated mass that prolapsed into the tricuspid valve orifice, thereby causing severe obstruction to right ventricular filling. This mass was attached to the lower part of the atrial septum. Pathological examination showed fibrotic myxoid tissue. After the mass was resected surgically, the tricuspid valve appeared normal. We comment on the pathogenesis and the differential diagnosis of this rare entity.

Key words: *Congenital heart disease. Tricuspid dysplasia. Cor triatriatum dexter.*

Una forma rara de cardiopatía cianósante por obstrucción supravalvular tricuspídea en el lactante

Presentamos el caso de un lactante de 2 meses con cianosis desde el primer día de vida. El diagnóstico de sospecha inicial fue displasia tricuspídea, con *shunt* derecha-izquierda a través de una comunicación interauricular. Fue necesario llegar al acto quirúrgico para objetivar un «bolsón» de tejido supratricuspídeo adherido al septo interauricular bajo, que dificultaba el llenado del ventrículo derecho. Tras su resección se evidenció el aspecto macroscópico normal de la válvula tricúspide. La histología fue compatible con tejido fibromixóide. Se discuten la etiopatogenia y posibilidades diagnósticas de este hallazgo inhabitual.

Palabras clave: *Cardiopatía congénita. Displasia tricuspídea. Cor triatriatum dexter.*

INTRODUCTION

The presence of structural abnormalities in the right atrium (RA) in the newborn establishes a differential diagnosis limited to congenital heart diseases, neoplasms, and thrombi. Remnants of the embryonic venous sinus (VS) are also relevant, because of the high incidence of morphological variants of this structure.

CASE STUDY

We describe the case of a 2-month-old infant with cyanosis at birth.

The physical examination disclosed a weight of 3410 g, height 51 cm, blood pressure 100 mm Hg, baseline Sat O₂ 77%, central cyanosis, tricuspid systolic murmur, mild hepatomegaly, sinus rhythm on electrocardiography, and an enlarged right atrium. The chest x-ray showed a thymic image and low pulmonary flow. Transthoracic echocardiography (TTE) (Figure 1), disclosed a smooth, mobile, redundant tricuspid valve with tense motion that generated a diastolic gradient (5 mm Hg), classified as a dysplastic tricuspid valve. In addition, there was an oval fossa defect (4×6 mm) with right-to-left shunting.

The 50% O₂ oximetry values were: systemic 85%, inferior vena cava 69.6%, superior vena cava 70.9%, right atrium 69.5%, pulmonary artery 70.6%, left anterior descending 77%, left ventricle 85.2%. Assuming 95% pulmonary flows, the QP/QS was 0.63. The pressures (mm Hg) were left ventricle 63/-6, right ventricle 22/-7, left atrium 6, right atrium 7, pulmonary artery 23/9/15, aorta 55/29/40. Contrast enhancement of the right ventricle on angiography

Correspondence: Dr. J.C. García López.
Orense, 23, 2.º izqda. 02005 Albacete. España.
E-mail: jcgarto@hotmail.com

Received September 24, 2004.
Accepted for publication April 21, 2005.

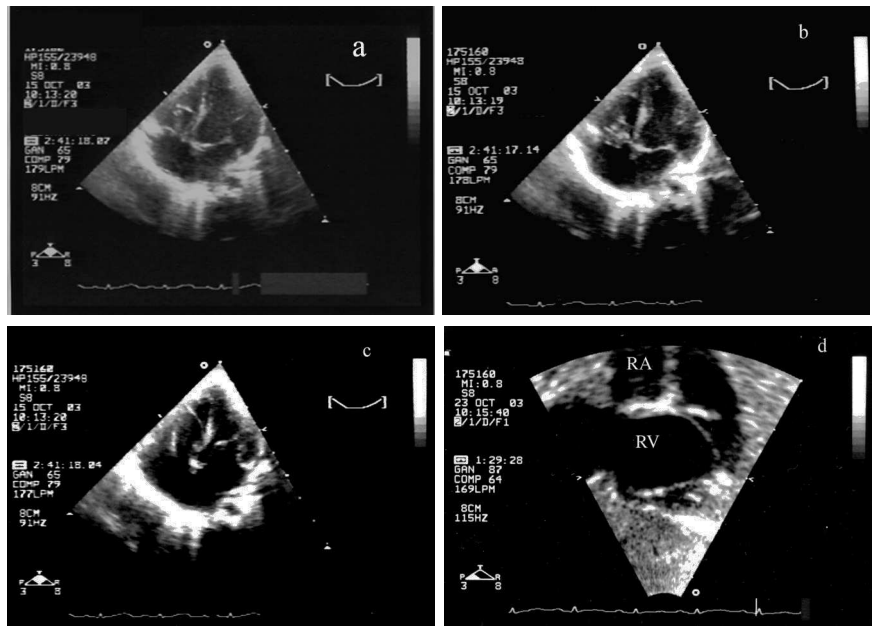


Figure 1. Apical echocardiographic views (diastole [c] systole [a,b]) and inverted subcostal [d] showing an apparently dysplastic tricuspid valve.

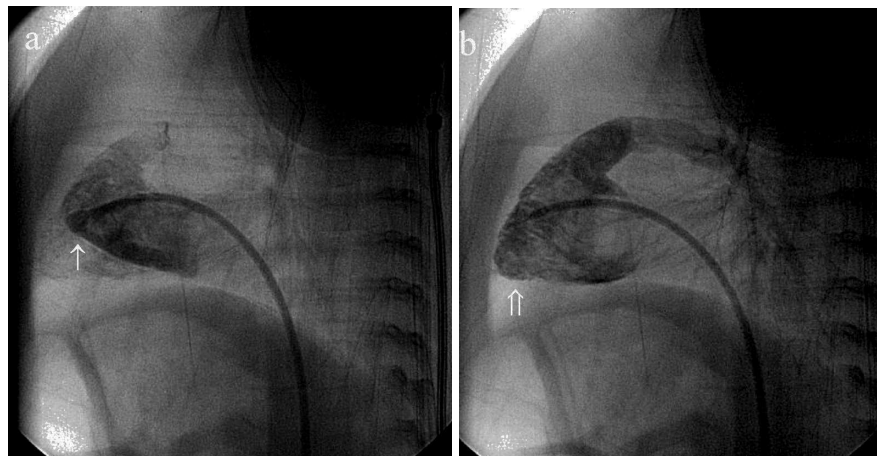


Figure 2. Right ventriculography in left oblique view. Fortuitous injection of contrast material (a) in small cavity (↑), which could be mistaken for a hypoplastic false right ventricle, corresponded to the vestigial cavity. When injected through the tricuspid valve (b), the morphologically normal true right ventricle is defined (↑↑).

(Figure 2) showed a double image: one small image adjacent to the tricuspid valve with smooth walls that initially went unnoticed, and another, more distant and larger that presented the classic trabeculation of the right ventricle, with tricuspid competence.

Surprisingly, an accessory “pocket-like” tissue with an inlet hole, joined on one side to the tricuspid ring was observed during surgery (Figure 3). The histological study was consistent with fibromyxoid tissue.

DISCUSSION

The clinical presentation suggested a diagnosis of cyanotic heart disease, initially characterized as tricuspid dysplasia. Based on the surgical findings, the apparent diagnosis was vestigial remnant of the right valve of the embryonic venous sinus,¹ an entity frequently found in conventional imaging tests (30%

of the unselected population).² The mildest form usually consists of a simple structure (eustachian or thebesian valve, terminal crest) or lacelike structure (Chiari’s net). In contrast, if the size is large enough to compartmentalize the right atrium, the most serious form is cor triatriatum dexter, an entity classified according to its distribution in the right atrium.¹ The clinical symptoms are defined by obstruction (if any) and the associated congenital abnormalities, with hypoplasia of the right ventricle the most frequent.^{2,3} Between these 2 anatomical variants there is a broad spectrum, depending on the moment at which the venous sinus development was altered.^{4,5}

Infections in this area,⁶ atrial arrhythmias, paradoxical strokes, and stunted growth due to enteropathy have been described as complications.

In our patient we also ruled out a coronary sinus of atypical distribution (TTE/recirculation).

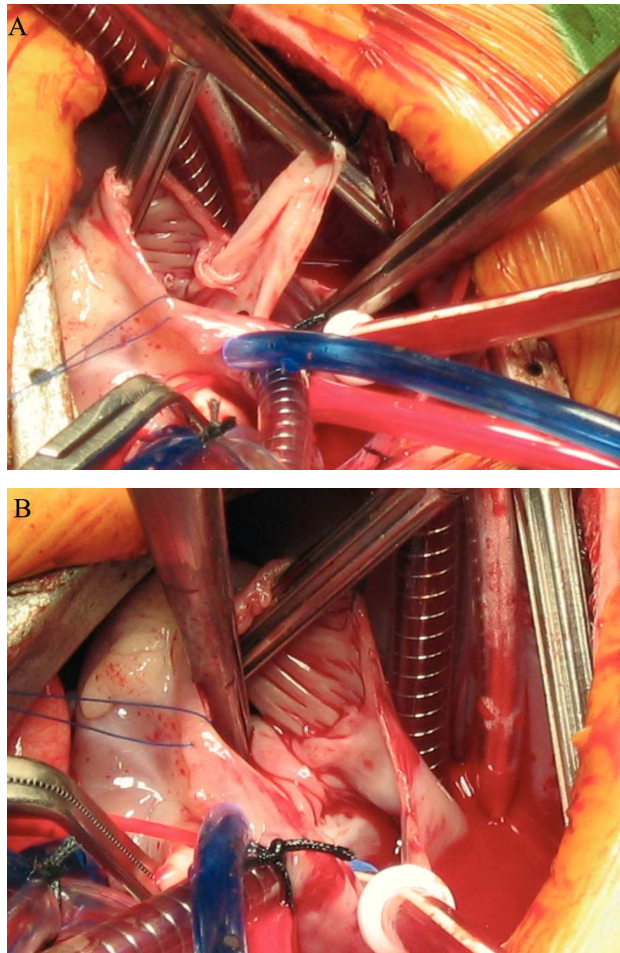


Figure 3. Intraoperative image (A) disclosing a “pocket” of supratricuspid accessory tissue (diameter 1.5 cm); a normal tricuspid valve is observed after resection (B).

Papillary fibroelastoma is one of the tumors with similar symptoms. However, unlike the condition in adults, in the pediatric age group it tends to affect the tricuspid valve. The tumor is usually suspected when the typical echocardiographic image is observed.

CONCLUSION

We have presented an unusual form of cyanotic heart disease in an infant, an entity that should be included in the screening for any right atrium structural abnormality.

REFERENCES

1. Moreno Granado F, Herráiz Sarachaga I, Castro Gussoni C, Duha-gon Cajelli P. Persistencia de la válvula derecha del seno venoso *cor triatriatum dexter*. *An Esp Pediat*. 1976;9:407-14.
2. Schutte D, Rowland D, Allen H, Bharati S. Prominent venous valves in hypoplastic right hearts. *Am Heart J*. 1997;134:527-31.
3. Inoue T, Tomomasa Y, Okada Y, Morikawa A. Divided right atrium associated with extensive coronary vein abnormalities. *Pediatric Cardiology*. 2002;1:68-70.
4. Trento A, Zuberbuhler JR, Anderson RH, Park SC, Siewers RD. Divided right atrium (prominence of the eustachian and thebesian valves). *J Thorac Cardiovasc Surg*. 1988;96:457-63.
5. Lanzarini L, Lucca E. Persistence of the right valve of the sinus venosus resulting in an unusually Chiari network remnant mimicking *cor triatriatum dexter*. *Pediatr Cardiol*. 2002;23:103-5.
6. San Román JA, Vilacosta I, Sarriá C, Garcimartín I, Rollán MJ, Fernández-Avilés F. Eustachian valve endocarditis: Is it worth searching for? *Am Heart J*. 2001;142:1037-40.