

Special article

Update on Cardiac Imaging Techniques 2012

José J. Gómez de Diego,^{a,*} Rocío García-Orta,^b Patricia Mahía-Casado,^c Joaquín Barba-Cosials,^d and Jaume Candell-Riera^e

^aServicio de Cardiología, Hospital Clínico San Carlos, Madrid, Spain

^bServicio de Cardiología, Hospital Virgen de las Nieves, Granada, Spain

^cServicio de Cardiología, Hospital Carlos III, Madrid, Spain

^dDepartamento de Cardiología, Clínica Universidad de Navarra, Pamplona, Navarra, Spain

^eServicio de Cardiología, Hospital Vall d'Hebron, Barcelona, Spain

Article history:

Available online 15 January 2013

Keywords:

Echocardiography

Nuclear cardiology

Computed tomography

Magnetic resonance imaging

ABSTRACT

Cardiac imaging is one of the basic pillars of modern cardiology. The potential list of scenarios where cardiac imaging techniques can provide relevant information is simply endless so it is impossible to include all relevant new features of cardiac imaging published in the literature in 2012 in the limited format of a single article. We summarize the year's most relevant news on cardiac imaging, highlighting the ongoing development of myocardial deformation and 3-dimensional echocardiography techniques and the increasing use of magnetic resonance imaging and computed tomography in daily clinical practice.

© 2012 Sociedad Española de Cardiología. Published by Elsevier España, S.L. All rights reserved.

Novedades en imagen cardiaca 2012

RESUMEN

La imagen cardiaca es uno de los pilares de la cardiología actual. La cantidad de situaciones en que las técnicas de imagen aportan información importante en clínica o investigación es sencillamente interminable, por lo que es imposible recoger en el formato reducido de un artículo todas las novedades importantes sobre imagen cardiaca que han aparecido en la literatura médica en el año 2012. Resumimos las publicaciones más importantes del año, entre las que destacan el desarrollo progresivo de las técnicas de deformación miocárdica y la ecocardiografía tridimensional y la incorporación creciente al trabajo clínico diario de la resonancia magnética y la tomografía computarizada.

© 2012 Sociedad Española de Cardiología. Publicado por Elsevier España, S.L. Todos los derechos reservados.

Palabras clave:

Ecocardiografía

Cardiología nuclear

Tomografía computarizada

Resonancia magnética

Abbreviations

Cardiac CT: cardiac computed tomography

SPECT: single-photon emission computed tomography

ECHOCARDIOGRAPHY

Update on Echocardiography

The most important publication of the year deals with the criteria for appropriate use¹ and represents a major drive to use this technique rationally.

Technically, the major innovation is the progressive introduction of pocket-size hand-held devices. A consensus document has been published that specifies the indications and type of training recommended for their use,² while different studies have shown their usefulness in clinical practice³ and in teaching.⁴ In the

foreseeable future, the number of these devices will increase rapidly and they will even be linked with smartphone applications.⁵

This year has seen a discreet revival in the use of backscatter signal, which can characterize tissues from the echocardiographic image. For example, in patients with hypertrophic cardiomyopathy, cyclical variation of the backscatter signal can be useful in predicting events,⁶ whereas in dilated cardiomyopathy it can predict inverse remodeling and the degree of fibrosis.⁷

No major innovation has appeared in other fields. A tool to determine the properties of myocardial contractility has been developed, based on so-called shear wave imaging,⁸ and analytical systems are being created to study left ventricular rotation dynamics.⁹ A system enabling us to follow contrast bubbles in order to analyze intracavity flow has also been developed.¹⁰

Stress Echocardiography

In dobutamine stress echocardiography, the troponin concentration is not elevated so its use provides no additional information to help interpret the studies; therefore, it is not recommended.¹¹ Stress echocardiography itself has shown that studying images of peak treadmill exercise is the most sensitive approach as it enables us to see ischemia most frequently and most extensively.¹² It has

* Corresponding author: Laboratorio de Ecocardiografía, Hospital Clínico San Carlos, Planta Primera Norte, Prof. Martín Lagos s/n, 28040 Madrid, Spain.

E-mail address: josejgd@gmail.com (J.J. Gómez de Diego).

also been shown that a significant proportion of patients with exertional dyspnea and normal ejection fraction (EF) have relevant diastolic dysfunction only during exercise,¹³ hence they would be not be identified by the criteria in current clinical practice guidelines.

Contrast Media

Transesophageal echocardiography (TEE) continues to be superior to cardiac computed tomography (cardiac CT) in the diagnosis of patent foramen ovale.¹⁴ However, TEE is less sensitive than transthoracic echocardiography (TTE) and transcranial Doppler and tends to underestimate shunt.¹⁵ Use of contrast enables us to determine the presence of microvascular damage in acute coronary syndrome and this damage has been shown to be reversible, which associates it with a favorable prognosis.¹⁶ Contrast media have been combined with exertion in new techniques like 3-dimensional (3D) echocardiography and with new drugs like regadenoson in myocardial perfusion studies.¹⁷ Finally, new data have appeared which confirm that contrast perfusion studies add important prognostic information to pharmacologic stress tests.¹⁸

Interventional Cardiology

Interventional cardiology in structural heart disease has grown considerably, with increasing use of imaging techniques in selecting suitable patients and procedure monitoring. The European Association of Cardiovascular Imaging (before European Association of Echocardiography) and the American Society of Echocardiography have prepared a joint document of recommendations for the use of echocardiography in these procedures¹⁹ which particularly highlights the value of 3D TEE (Fig. 1). Together with transcatheter aortic valve implantation, the other innovation is percutaneous atrial appendage occlusion, in which the opportunity to use 3D TEE improves results.²⁰

VALVULAR HEART DISEASE

Aortic Valve

The debate about low-flow low-gradient aortic stenosis with normal EF continues. In a new prospective study, patients with this pattern presented more severe stenosis and data indicating incipient ventricular infection with reduced longitudinal strain, which would explain their poor prognosis.²¹

One relatively new topic is the evaluation of pulmonary hypertension associated with aortic stenosis, which is found in $\leq 30\%$ of patients.²² The appearance of pulmonary hypertension with exercise in patients with severe asymptomatic aortic stenosis has prognostic value, hence it could be useful when making decisions on surgery.²³ Pulmonary hypertension is associated with greater mortality in patients undergoing valve replacement,²⁴ although the degree of pulmonary pressure does not condition mortality and in the presence of elevated capillary pressure can decline after valve replacement.²⁵

Mitral Valve

In the field of rheumatic mitral stenosis, an interesting index has been described. The $>50\%$ ratio between posterior and anterior leaflet length is an excellent predictor of good results in valvuloplasty²⁶ (Fig. 2).

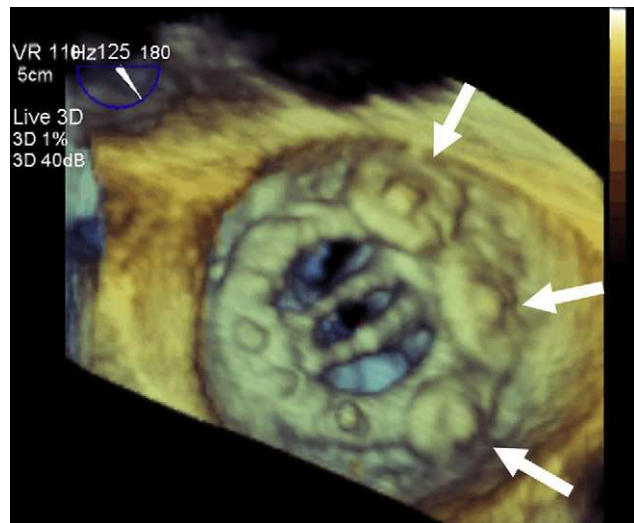


Figure 1. Three-dimensional transesophageal echocardiography in structural intervention. The image shows a mechanical mitral valve from the atrial side, with three closure devices (arrows) deployed to treat a perivalvular leak.

Mitral regurgitation has been associated with diminished exercise capacity in patients with heart failure and ventricular dysfunction.²⁷ In the clinically difficult context of treating mitral regurgitation in patients who undergo aortic valve replacement, prosthesis size mismatch has been shown to limit the expected improvement in the mitral valve lesion, which obliges us to optimize the surgical strategy.²⁸ On the other hand, in patients undergoing aortic valve replacement, moderate mitral regurgitation in the postoperative period is associated with greater mortality during follow-up.²⁹

Studies continue to appear that confirm the advantage of 3D imaging in analyzing valves requiring complex surgery^{30,31} and in the presurgical study of functional mitral regurgitation³² as they identify the valvular condition precisely³³ and enable us to determine the best position of the papillary muscles and assess the need for relocation associated with annuloplasty, which improves surgical results.³⁴

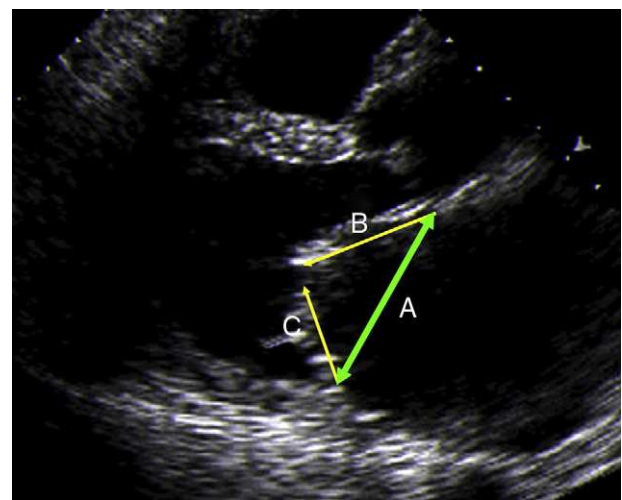


Figure 2. Transthoracic echocardiography. Typical opening movement in mitral valve stenosis and the method of measuring the maximum length of the mitral leaflets. A, mitral annulus length; B, anterior leaflet; C, posterior leaflet.

Tricuspid Valve

Two new studies of patients undergoing degenerative mitral regurgitation repair³⁵ or replacement for rheumatic mitral stenosis³⁶ have shown that, although the mild-to-moderate tricuspid regurgitation repair entailed is not accompanied by clear differences in the rates of mortality or need for new surgery, patients without tricuspid valve repair presented greater incidence of moderate-to-severe tricuspid regurgitation in the follow-up and worse event-free survival, which means that adding tricuspid valve repair to mitral valve surgery is recommendable.

Prosthetic Valves

Two new, relatively simple parameters have been identified (acceleration time > 100 ms and acceleration time/ejection time ratio > 0.37 ms) that help detect prosthetic aortic valve stenosis.³⁷

LESIONS OF THE AORTA

Young patients with stroke attributable to patent foramen ovale present larger aortic root diameters than healthy control subjects, which indicates a possible relationship to aortic dilatation.³⁸ In patients with severe aortic stenosis, a relationship exists between the complex atherosclerotic plaque in the aortic arch and cerebral infarction after hemodynamic study or valve replacement.³⁹

VENTRICULAR FUNCTION

Study of the ventricular mechanism using deformation parameters continues to develop apace despite its slow implantation in daily clinical practice. The publication of an excellent review article on its usefulness in coronary disease, which clearly summarizes its possible applications, stands out.⁴⁰ On the other hand, the problem of reproducibility and the standardization of these parameters is being toned down by the recent publication of the normal reference values.⁴¹ New tools based on 3D strain have shown its usefulness in studying ventricular function and volume,^{42–44} although their comparative reproducibility by teams from different commercial companies is again its principle limitation.⁴⁵ Promising new parameters have appeared, for example area strain (Fig. 3), which combines the longitudinal and circumferential deformations. Initial reports evaluate its usefulness in studying ventricular function.⁴⁶

CARDIOMYOPATHY

The need to combine information from different imaging techniques has been made clear and deformation parameters have been shown to be useful in several conditions. In patients with hypertrophic cardiomyopathy, simple parameters such as global strain have been proven to be independent predictors of the presence of fibrosis and the risk of adverse events.⁴⁷ Deformation parameters could also be useful in cardiomyopathy secondary to chemotherapy, in which early decrease in longitudinal strain has been related with cardiotoxicity at 6-month follow-up.^{48,49}

HEART FAILURE AND RESYNCHRONIZATION

The role of echocardiography in diagnosing heart failure is reflected in the new European Society of Cardiology guidelines,⁵⁰ which highlight the method of calculating EF and emphasize the

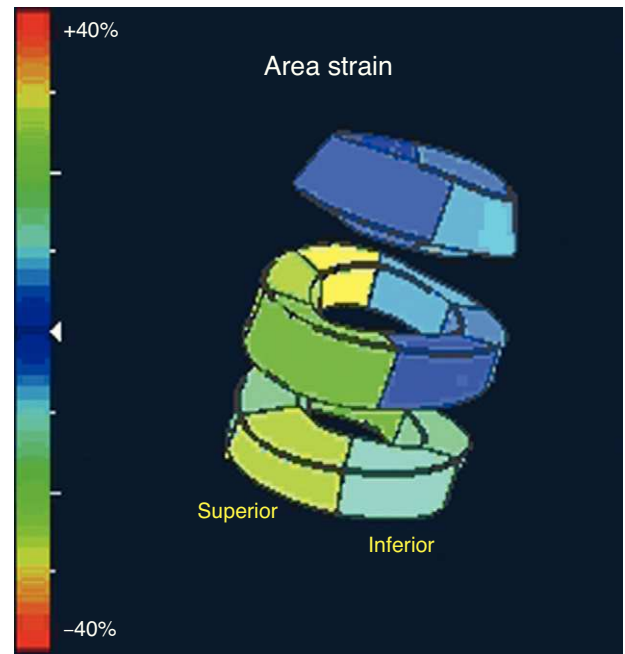


Figure 3. Parametric image of the area strain parameter in a healthy subject, obtained using 3-dimensional echocardiography.

usefulness of contrast media, 3D echocardiography and deformation techniques in the evaluation of ventricular function.

Speckle tracking is a promising technique in the identification of ventricular asynchrony. The MUSIC multicenter study concludes that the echocardiography enables us to identify resynchronization responders among patients with and without ischemia.⁵¹ Another novel issue is the suggestion that the effectiveness of resynchronization could be related to viability defined by using deformation techniques to study the segment where the electrode is placed.^{52,53} Three-dimensional echocardiography is another tool that enables us to determine the presence of asynchrony with tissular synchronization techniques, real-time 3D imaging and the 3D study of myocardial deformation and obtain a reliable prediction of response to resynchronization therapy.^{54,55}

NUCLEAR CARDIOLOGY

The technical advances aimed at reducing acquisition time and radiation dose and improving image quality^{56,57} with cardiac-dedicated single-photon emission computed tomography (SPECT) cameras are being held back in Spain as a consequence of the current economic crisis. Partly for the same reason, positron emission tomography (PET) has not become established in Spain despite the proliferation of PET-CT cameras in oncology.

A substantial number of more recent articles have focused on studying gated myocardial perfusion SPECT in subgroups of asymptomatic patients: with diabetes,⁵⁸ advanced kidney failure,⁵⁹ a family history of early heart disease,⁶⁰ aged > 80 years⁶¹ and as a preoperative evaluation.⁶² The use of SPECT with this patient type is not in the guidelines and constitutes one of the most frequent inappropriate uses of the technique.⁶³ This is of special interest if we consider that the impact of noninvasive exploration in therapeutic strategy is only relative.⁶⁴

The use of ¹²³I-metaiodobenzyl guanidine scintigraphy to study sympathetic innervation continues to be considered in the risk stratification of patients with heart failure.^{65,66} Severe arrhythmic

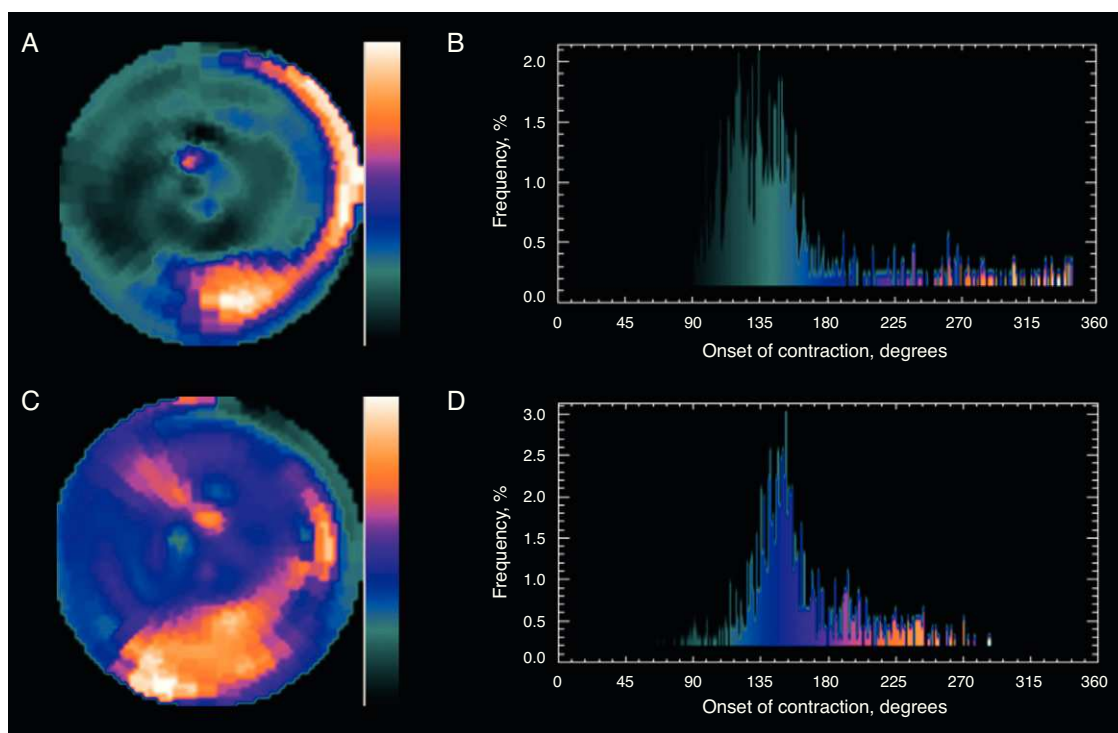


Figure 4. Fourier analysis of a gated myocardial perfusion single-photon emission computed tomography. Before resynchronization (A), the phase histogram amplitude increases abnormally. The polar map (B) shows that the greatest delay occurs in the inferior-lateral region of the left ventricle. After cardiac resynchronization therapy (C), the histogram amplitude (D) improves significantly. The patient improved clinically and left ventricular ejection fraction improved from 18% to 32% lower. (Images courtesy of Dr. Santiago Aguadé-Bruix, Hospital Universitari Vall d'Hebron, Barcelona.)

events or sudden death are unusual in patients with a heart/mediastinum ratio of >1.6 , which could mean that in one fifth of patients with primary indication for an implantable cardioverter-defibrillator⁶⁷ the implantation might be unnecessary. Another novel idea is the application of Fourier phase analysis to gated myocardial perfusion SPECT (Fig. 4). This is an automatic method that does not depend on the explorer and facilitates the rapid determination of left ventricular asynchrony.^{68,69}

The role of hybrid fusion of anatomic and functional images taken with 3D SPECT-CT or PET-CT continues under study because, although they represent a substantial qualitative advance, in practice obtaining these images entails a long processing time. Pazhenkottil et al.⁷⁰ have indicated that incidence of revascularization in ≤ 60 days following these studies is 41% when hybrid SPECT-CT images show that SPECT and CT findings coincide, 11% when the patterns do not coincide, and 0% if both are normal.

Myocardial viability, which has for years been a source of numerous publications using SPECT and PET, is gradually losing interest although articles on the impact of gated myocardial perfusion SPECT in the indication for catheterization⁷¹ and assessment of contractile response to low dosage dobutamine in patients with ischemic cardiomyopathy⁷² have been published. Pizzi et al.⁷³ have found that the so-called paradoxical scintigraphic pattern (greater uptake during stress than at rest) in regions with myocardial necrosis occurs in territories with scintigraphic criteria of myocardial viability with the responsible artery open (Fig. 5) or with good collateral circulation if the artery is occluded. Although PET is the most effective technique for noninvasive functional diagnosis of coronary disease when taking $>50\%$ stenosis in the invasive coronary angiography as a reference, SPECT remains the most widely indicated and validated technique.⁷⁴

CARDIAC COMPUTED TOMOGRAPHY

Cardiac CT is now firmly established in clinical practice. With the publication of the CONFIRM study,⁷⁵ a register with data on $>25\,000$ patients showing a clear relationship between the presence and severity of coronary disease diagnosed with cardiac CT and mid-term mortality, the debate over its prognostic value has ended (Fig. 6).

Developments in cardiac CT advance at a tremendous pace. As a technique, it has been shown to be as precise as cardiac magnetic resonance imaging in the assessment of ventricular function.⁷⁶ An interesting mathematical model has been developed that is capable of noninvasively deriving coronary fractional flow reserve and promises to improve CT performance in coronary disease.⁷⁷ Moreover, the application of late iodine enhancement is useful in the etiologic diagnosis of dilated cardiomyopathy.⁷⁸

In clinical practice, two very interesting articles have been published in the *New England Journal of Medicine* about the usefulness of cardiac CT in assessing the patient with chest pain attending the emergency department. Computed tomography has been shown to be a safe technique that facilitates the diagnosis of a larger number of patients who really have coronary disease and leads to a shorter stay in Emergency and a higher number of direct discharges.^{79,80} Also this year, the first study appeared with evidence that treatment of asymptomatic patients with baseline risk identified by cardiac CT can reduce the appearance of coronary events. This pioneering study may open the door to changes in the management of coronary disease.⁸¹

Finally, cardiac CT is fast gaining acceptance in the assessment of patients suitable for transcatheter aortic prosthesis implantation as data are being gathered that indicate it could prove the most precise way to measure the aortic annulus (and, therefore,

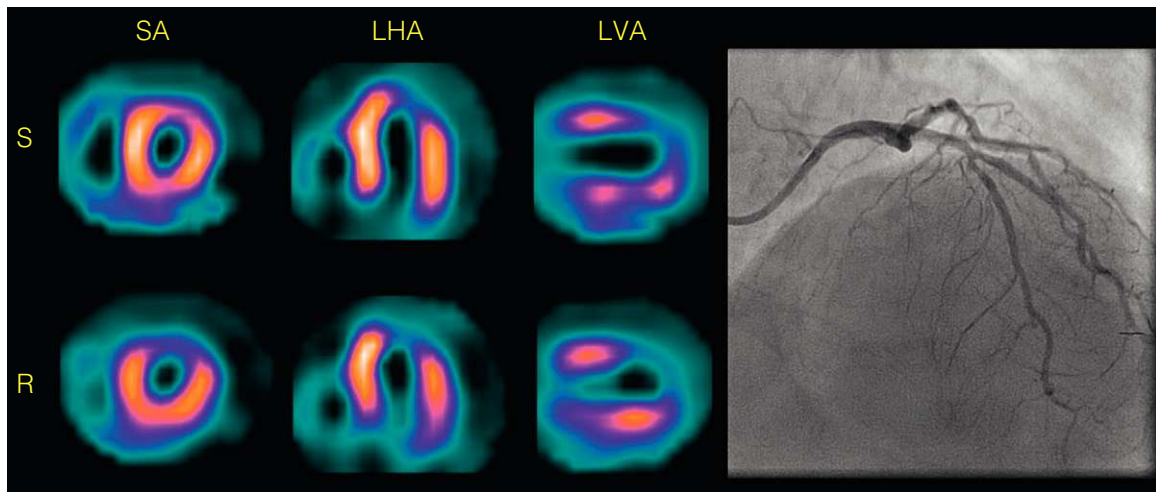


Figure 5. Single-photon emission computed tomography myocardial perfusion with ^{99m}Tc -tetrofosmin of a patient with chronic anterior infarction and paradoxical scintigraphic pattern, criteria of viability, and permeable anterior descending artery. LHA, long horizontal axis; LVA, long vertical axis; R, rest; S, stress; SA, short axis. (Images courtesy of Dr. M. Nazarena Pizzi, Hospital Universitari Vall d'Hebron, Barcelona.)

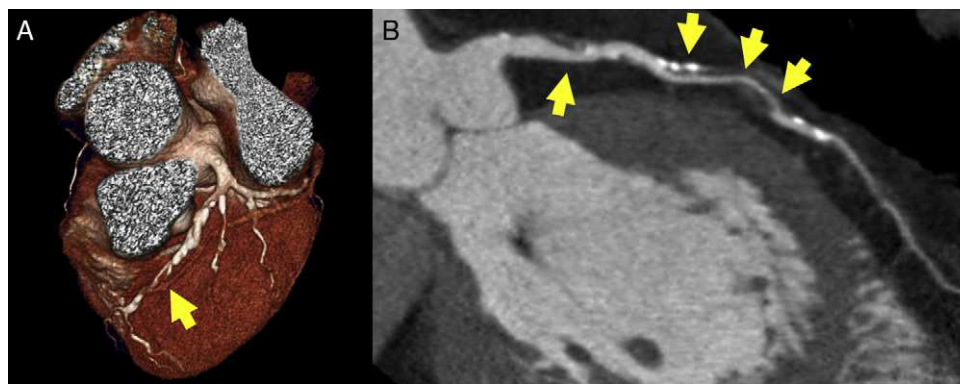


Figure 6. Stenosis of the left anterior descending artery in cardiac computed tomography study, visible (arrows) both in volumetric (A) and multiplanar reconstruction (B). The result has obvious prognostic and diagnostic implications.

select prosthesis size) and that its use could reduce the percentage of patients with postprocedural periprosthetic failure.^{82,83}

CARDIAC MAGNETIC RESONANCE IMAGING

Cardiac magnetic resonance imaging has become invaluable in ischemic cardiomyopathy, to the point where the loss of viability of a segment of myocardium has been included in the latest universal definition of myocardial infarction.⁸⁴ Late gadolinium enhancement is efficient in the etiologic study of dilated cardiomyopathy⁸⁵ and in prognostic assessment, as myocardial scarring is an efficient risk marker for ventricular arrhythmias.⁸⁶ The new 3D perfusion sequences have been validated. They perform well and enable us to calculate ischemic burden in the myocardium.⁸⁷ Strain encoded sequencing is another new technique that promises to improve the sensitivity of dobutamine tests.⁸⁸

The role of cardiac magnetic resonance imaging in studying the myocardium appears never-ending. In hypertrophic cardiomyopathy, it has been shown that fibrosis is a progressive process associated with the functional stage⁸⁹ and that intramyocardial fibrosis is a clear predictor of mortality in patients with aortic stenosis.⁹⁰ Also, left ventricular lesions in right ventricular arrhythmogenic dysplasia have been defined in detail.⁹¹ The capacity of cardiac magnetic resonance imaging to describe early

abnormalities, such as right ventricular hypertrophy in an apparently healthy population, has been demonstrated.⁹² Finally, one of the most novel observations of the year has been the demonstration that late enhancement can also be useful in pericardial pathology as it can predict how constrictive pericarditis will respond to antiinflammatory drug treatment.⁹³

CONFLICTS OF INTEREST

None declared.

REFERENCES

1. American College of Cardiology Foundation Appropriate Use Criteria Task Force; American Society of Echocardiography; American Heart Association; American Society of Nuclear Cardiology; Heart Failure Society of America; Heart Rhythm Society; Society for Cardiovascular Angiography and Interventions; Society of Critical Care Medicine; Society of Cardiovascular Computed Tomography; Society for Cardiovascular Magnetic Resonance; American College of Chest Physicians, Douglas PS, Garcia MJ, Haines DE, Lai WW, Manning WJ, Patel AR, et al. ACCF/AHA/ASNC/HFSA/HRS/SCAI/SCCM/SCCT/SCMR 2011 Appropriate Use Criteria for Echocardiography. *J Am Soc Echocardiogr.* 2011;24:229–67.
2. Sicari R, Galderisi M, Voigt JU, Habib G, Zamorano JL, Lancellotti P, et al. The use of pocket-size imaging devices: a position statement of the EAE. *Eur J Echocardiogr.* 2011;12:85–7.

3. Andersen GN, Haugen BO, Graven T, Salvesen Ø, Mjølstad OC, Dalen H. Feasibility and reliability of point-of-care pocket-sized echocardiography. *Eur J Echocardiogr.* 2011;12:665–70.
4. Panoulas VF, Daigeler AL, Malaweera AS, Lota AS, Baskaran D, Rahman S, et al. Pocket-size hand-held cardiac ultrasound as an adjunct to clinical examination in the hands of medical students and junior doctors. *Eur Heart J Cardiovasc Imaging.* 2012 July 24. <http://dx.doi.org/10.1093/ehjci/jes140>.
5. Choi BG, Mukherjee M, Dala P, Young HA, Tracy CM, Katz RJ, et al. Interpretation of remotely downloaded pocket-size cardiac ultrasound images on a web-enabled smartphone: validation against workstation evaluation. *J Am Soc Echocardiogr.* 2011;24:1325–30.
6. Kawasaki T, Yamano M, Kuribayashi T, Kaimoto S, Miki S, Kamitani T, et al. Three-layer ultrasonic tissue characterization of the ventricular septum is predictive of prognosis in patients with non-obstructive hypertrophic cardiomyopathy. *Eur J Echocardiogr.* 2011;12:90–7.
7. Park SM, Kim YH, Ahn CM, Hong SJ, Shim WJ. Relationship between ultrasonic tissue characterization and myocardial deformation for prediction of left ventricular reverse remodelling in non-ischaemic dilated cardiomyopathy. *Eur J Echocardiogr.* 2011;12:887–94.
8. Pernot M, Couade M, Mateo Ph, Crozatier B, Fischmeister R, Tanter M. Real-time assessment of myocardial contractility using shear wave imaging. *J Am Coll Cardiol.* 2011;58:65–72.
9. Ashraf M, Zhou Z, Nguyen T, Ashraf S, Sahn DJ. Apex to base left ventricular twist mechanics computed from high frame rate two-dimensional and three-dimensional echocardiography: a comparison study. *J Am Soc Echocardiogr.* 2012;25:121–8.
10. Gao H, Claus P, Amzulescu MS, Stankovic I, D'hooge J, Voigt JU. How to optimize intracardiac blood flow tracking by echocardiographic particle image velocimetry? *Eur Heart J Cardiovasc Imaging.* 2012;13:490–9.
11. Blatt A, Moravsky G, Filipodi G, Mor A, Benbeniste P, Vered Z, et al. Can dobutamine stress echocardiography induce cardiac troponin elevation? *Echocardiography.* 2011;28:219–22.
12. Peteiro J, Bouzas-Mosquera A, Estevez R, Pazos P, Piñeiro M, Castro-Beiras A. Head-to-head comparison of peak supine bicycle exercise echocardiography and treadmill exercise echocardiography at peak and at post-exercise for the detection of coronary artery disease. *J Am Soc Echocardiogr.* 2012;25:319–26.
13. Meluzin J, Sitar J, Kristek J, Prosecky R, Pesl M, Podrouzkova H, et al. The role of exercise echocardiography in the diagnostics of heart failure with normal left ventricular ejection fraction. *Eur J Echocardiogr.* 2011;12:591–602.
14. Hamilton-Craig C, Sestito A, Natale L, Meduri A, Santangeli P, Infusino F, et al. Contrast transoesophageal echocardiography remains superior to contrast-enhanced cardiac magnetic resonance imaging for the diagnosis of patent foramen ovale. *Eur J Echocardiogr.* 2011;12:222–7.
15. González-Alujas T, Evangelista A, Santamarina E, Rubiera M, Gómez-Bosch Z, Rodríguez-Palomares JF, et al. Diagnóstico y cuantificación del foramen oval permeable. ¿Cuál es la técnica de referencia? Estudio simultáneo con Doppler transcraneal, ecocardiografía transtorácica y transesofágica. *Rev Esp Cardiol.* 2011;64:133–9.
16. Funaro S, Galiuto L, Boccalini F, Cimino S, Canali E, Evangelio F, et al. Determinants of microvascular damage recovery after acute myocardial infarction: results from the acute myocardial infarction contrast imaging (AMICI) multicentre study. *Eur J Echocardiogr.* 2011;12:306–12.
17. Porter TR, Adolphson M, High RR, Smith LM, Olson J, Erdkamp M, et al. Echocardiography during regadenoson stress rapid detection of coronary artery stenoses with real-time perfusion. *Circ Cardiovasc Imaging.* 2011;4:628–35.
18. Gaibazzi N, Reverberi C, Lorenzoni V, Molinaro S, Porter T. Prognostic value of high-dose dipyridamole stress myocardial contrast perfusion echocardiography. *Circulation.* 2012;126:1217–24.
19. Zamorano JL, Badano LP, Bruce C, Chan KL, Gonçalves A, Hahn RT, et al. EAE/ASE recommendations for the use of echocardiography in new transcatheter interventions for valvular heart disease. *Eur J Echocardiogr.* 2011;12:557–84.
20. Perk G, Biner S, Kronzon I, Saric M, Chinitz L, Thompson K, et al. Catheter-based left atrial appendage occlusion procedure: role of echocardiography. *Eur Heart J Cardiovasc Imaging.* 2012;13:132–8.
21. Adda J, Mielot C, Giorgi R, Cransac F, Zirphile X, Donal E, et al. Low-flow, low-gradient severe aortic stenosis despite normal ejection fraction is associated with severe left ventricular dysfunction as assessed by speckle-tracking echocardiography: a multicenter study. *Circ Cardiovasc Imaging.* 2012;5:27–35.
22. Mutlak D, Aronson D, Carasso S, Lessick J, Reisner SA, Agmon Y. Frequency, determinants and outcome of pulmonary hypertension in patients with aortic valve stenosis. *Am J Med Sci.* 2012;343:397–401.
23. Lancellotti P, Magne J, Donal E, O'Connor K, Dulgheru R, Rosca M, et al. Determinants and prognostic significance of exercise pulmonary hypertension in asymptomatic severe aortic stenosis. *Circulation.* 2012;126:851–9.
24. Zuern CS, Eick C, Rizas K, Stoleriu C, Woernle B, Wildhirt S, et al. Prognostic value of mild-to-moderate pulmonary hypertension in patients with severe aortic valve stenosis undergoing aortic valve replacement. *Clin Res Cardiol.* 2012;101:81–8.
25. Cam A, Goel SS, Agarwal S, Menon V, Svensson LG, Tuzcu EM, et al. Prognostic implications of pulmonary hypertension in patients with severe aortic stenosis. *J Thorac Cardiovasc Surg.* 2011;142:800–8.
26. Mahfouz RA. Utility of the posterior to anterior mitral valve leaflets length ratio in prediction of outcome of percutaneous balloon mitral valvuloplasty. *Echocardiography.* 2011;28:1068–73.
27. Trivi M, Thierier J, Kuschner P, Acosta A, Marino J, Guglielmo R, et al. Predictores ecocardiográficos de capacidad de ejercicio en pacientes con insuficiencia cardíaca sistólica. Valor de la insuficiencia mitral. *Rev Esp Cardiol.* 2011;64:1096–9.
28. Angeloni E, Melina G, Pibarot P, Benedetto U, Refice S, Ciavarella GM, et al. Impact of prosthesis-patient mismatch on the regression of secondary mitral regurgitation after isolated aortic valve replacement with a bioprosthetic valve in patients with severe aortic stenosis. *Circ Cardiovasc Imaging.* 2012;5:36–42.
29. Jeong DS, Park PW, Sung K, Kim WS, Yang JH, Jun TG, et al. Long-term clinical impact of functional mitral regurgitation after aortic valve replacement. *Ann Thorac Surg.* 2011;92:1339–45.
30. Chikwe J, Adams DH, Su KN, Anyanwu AC, Lin HM, Goldstone AB, et al. Can three-dimensional echocardiography accurately predict complexity of mitral valve repair? *Eur J Cardiothorac Surg.* 2012;41:518–24.
31. Castillo JG, Solís J, González-Pinto, Adams D. Ecocardiografía quirúrgica de la válvula mitral. *Rev Esp Cardiol.* 2011;64:1169–81.
32. Berrebi A. Reparación de válvula mitral: la ecocardiografía es su mejor amigo. *Rev Esp Cardiol.* 2011;64:554–6.
33. Chen X, Sun D, Yang J, Feng W, Gu T, Zhang Z, et al. Preoperative assessment of mitral valve prolapse and chordae rupture using real time three-dimensional transesophageal echocardiography. *Echocardiography.* 2011;28:1003–10.
34. Fattouch K, Murana G, Castrovinci S, Mossuto C, Sampognaro R, Borruso MG, et al. Mitral valve annuloplasty and papillary muscle relocation oriented by 3-dimensional transesophageal echocardiography for severe functional mitral regurgitation. *Thorac Cardiovasc Surg.* 2012;143 Suppl 4:S38–42.
35. Navia JL, Brozzi NA, Klein AL, Ling LF, Kittayarak C, Nowicki ER, et al. Moderate tricuspid regurgitation with left-sided degenerative heart valve disease: to repair or not to repair? *Ann Thorac Surg.* 2012;93:59–67.
36. Kim JB, Yoo DG, Kim GS, Song H, Jung SH, Choo SJ, et al. Mild-to-moderate functional tricuspid regurgitation in patients undergoing valve replacement for rheumatic mitral disease: the influence of tricuspid valve repair on clinical and echocardiographic outcomes. *Heart.* 2012;98:24–30.
37. Ben Zekry S, Saad RM, Ozkan M, Al Shahid MS, Pepi M, Muratori M, et al. Flow acceleration time and ratio of acceleration time to ejection time for prosthetic aortic valve function. *JACC Cardiovasc Imaging.* 2011;4:1161–70.
38. Keenan NG, Brochet E, Juliard JM, Malanca M, Aubry P, Lepage L, et al. Aortic root dilatation in young patients with cryptogenic stroke and patent foramen ovale. *Arch Cardiovasc Dis.* 2012;105:13–7.
39. Sugioka K, Matsumura Y, Hozumi T, Fujita S, Ito A, Kataoka T, et al. Relation of aortic arch complex plaques to risk of cerebral infarction in patients with aortic stenosis. *Am J Cardiol.* 2011;108:1002–7.
40. Hoit BD. Strain and strain rate echocardiography and coronary artery disease. *Circ Cardiovasc Imaging.* 2011;4:179–90.
41. Marcus KA, Mavinkurve-Groothuis AM, Barends M, Van Dijk A, Feuth T, De Korte C, et al. Reference values for myocardial two-dimensional strain echocardiography in a healthy pediatric and young adult cohort. *J Am Soc Echocardiogr.* 2011;24:625–36.
42. Kleijn SA, Brouwer WP, Aly MF, Russel IK, De Roest GJ, Beek AM, et al. Comparison between three-dimensional speckle-tracking echocardiography and cardiac magnetic resonance imaging for quantification of left ventricular volumes and function. *Eur Heart J Cardiovasc Imaging.* 2012;13:834–9.
43. Reant P, Barbot L, Touche C, Dijos M, Arsac F, Pillois X, et al. Evaluation of global left ventricular systolic function using three-dimensional echocardiography speckle-tracking strain parameters. *J Am Soc Echocardiogr.* 2012;25:68–79.
44. Kleijn SA, Aly MF, Terwee CB, Van Rossum AC, Kamp O. Reliability of left ventricular volumes and function measurements using three-dimensional speckle tracking echocardiography. *Eur Heart J Cardiovasc Imaging.* 2012;13:159–68.
45. Gayat E, Ahmad H, Weinert L, Lang RM, Mor-Avi V. Reproducibility and inter-vendor variability of left ventricular deformation measurements by three-dimensional speckle-tracking echocardiography. *J Am Soc Echocardiogr.* 2011;24:878–85.
46. Pérez de Isla L, Millán M, Lennie V, Quezada M, Guinea J, Macaya C, et al. *Area strain*: umbrales de normalidad de un nuevo parámetro en sujetos sanos. *Rev Esp Cardiol.* 2011;64:1194–7.
47. Saito M, Okayama H, Yoshii T, Higashi H, Morioka H, Hiasa G, et al. Clinical significance of global two-dimensional strain as a surrogate parameter of myocardial fibrosis and cardiac events in patients with hypertrophic cardiomyopathy. *Eur Heart J Cardiovasc Imaging.* 2012;13:617–23.
48. Sawaya H, Sebag IA, Plana JC, Januzzi JL, Ky B, Cohen V, et al. Early detection and prediction of cardiotoxicity in chemotherapy-treated patients. *Am J Cardiol.* 2011;107:1375–80.
49. Stoodley PW, Richards DA, Hui R, Boyd A, Harnett PR, Meikle SR, et al. Two-dimensional myocardial strain imaging detects changes in left ventricular systolic function immediately after anthracycline chemotherapy. *Eur J Echocardiogr.* 2011;12:945–52.
50. McMurray JJ, Adamopoulos S, Anker SD, Auricchio A, Bohm M, Dickstein K, et al. ESC Guidelines for the diagnosis and treatment of acute and chronic heart failure 2012. *Eur Heart J.* 2012;33:1787–847.
51. Lim P, Donal E, Lafitte S, Derumeaux G, Habib G, Reant P, et al. Multicentre study using strain delay index for predicting response to cardiac resynchronization therapy (MUSIC study). *Eur J Heart Fail.* 2011;13:984–91.
52. Becker M, Zwicker C, Kaminski M, Napp A, Altiok E, Ocklenburg C, et al. Dependency of cardiac resynchronization therapy on myocardial viability at the LV lead position. *JACC Cardiovasc Imaging.* 2011;4:366–74.
53. Marwick TH. Use of speckle-strain in a multiparametric approach to dyssynchrony imaging. *JACC Cardiovasc Imaging.* 2011;4:375–7.

54. Auger D, Bertini M, Marsan NA, Hoke U, Ewe SH, Thijssen J, et al. Prediction of response to cardiac resynchronization therapy combining two different three-dimensional analyses of left ventricular dyssynchrony. *Am J Cardiol.* 2011;108:711–7.
55. Auger D, Schalij MJ, Bax JJ, Delgado V. Técnicas de imagen tridimensional en el tratamiento de resincronización cardíaca. *Rev Esp Cardiol.* 2011;64:1035–44.
56. Gordon E. Advances in SPECT camera software and hardware: currently available and new on the horizon. *J Nucl Cardiol.* 2012;19:551–81.
57. García EV. Physical attributes, limitations, and future potential for PET and SPECT. *J Nucl Cardiol.* 2012;19–34.
58. Hernández C, Candell-Riera J, Ciudin A, Francisco G, Aguadé-Bruix S, Simó R. Prevalence and risk factors accounting for true silent myocardial ischemia: a pilot case-control study comparing type 2 diabetic with non-diabetic control subjects. *Cardiovasc Diabetol.* 2011;10:9–11.
59. Kim JK, Kim SG, Song YR. Cardiac risk assessment by gated single-photon asymptomatic end-stage renal disease patients at the start of dialysis. *J Nucl Cardiol.* 2012;19:438–47.
60. Kral BG, Becker DM, Vaidya D, Yanek LR, Becker LC. Severity of inducible myocardial ischemia predicts incident acute coronary syndromes in asymptomatic individuals with a family history of premature coronary artery disease. *J Nucl Cardiol.* 2012;19:28–36.
61. Nair SU, Ahlberg AW, Mathur S, Katten DM, Polk DM, Heller GV. The clinical value of single photon emission computed tomography myocardial imaging in cardiac risk stratification of very elderly patients with suspected coronary artery disease. *J Nucl Cardiol.* 2012;19:244–55.
62. Koh AS, Flores JLS, Keng FY, Tan RS, Chua TSJ. Correlation between clinical outcomes and appropriateness grading for referral to myocardial perfusion imaging for preoperative evaluation prior to non-cardiac surgery. *J Nucl Cardiol.* 2012;19:277–84.
63. Hendel RC, Abbott BG, Bateman TM, Blankstein R, Calnon DA, Leppo JA, et al. The role of radionuclide myocardial perfusion imaging for asymptomatic individuals. *J Nucl Cardiol.* 2011;18:3–15.
64. Hachamovitch R, Nutter B, Hlatky MA, Shaw LJ, Ridner LM, Dorbala S, et al. Patient management after noninvasive cardiac imaging. Results from SPARC study. *J Am Coll Cardiol.* 2012;59:462–74.
65. Pizzi MN, Sabaté-Fernández M, De León G, Aguadé-Bruix S, Candell-Riera J. False heart-to-mediastinum ratio of I-123 metaiodobenzylguanidine due to right ventricular attenuation. *Clin Nucl Med.* 2011;36:828–30.
66. Chen J, Folks RD, Verdes L, Manatunga DN, Jacobson AF, García EV. Quantitative I-123 mIBG SPECT in differentiating abnormal and normal mIBG myocardial uptake. *J Nucl Cardiol.* 2012;19:92–9.
67. Jacobson AF, Senior R, Cerqueira MD, Wong ND, Thomas GS, López VA, et al. Myocardial iodine-123 meta-iodobenzylguanidine imaging and cardiac events in heart failure. *J Am Coll Cardiol.* 2010;55:2212–21.
68. Samad Z, Atchley AE, Trimble MA, Sun JL, Shaw LK, Pagnanelli R, et al. Prevalence and predictors of mechanical dyssynchrony as defined by phase analysis in patients with left ventricular dysfunction undergoing gated SPECT myocardial perfusion imaging. *J Nucl Cardiol.* 2011;18:24–30.
69. Aljaroudi W, Koneru J, Heo J, Iskandrian AE. Impact of ischemia on left ventricular dyssynchrony by phase analysis of gated single photon emission computed tomography myocardial perfusion imaging. *J Nucl Cardiol.* 2011;18:36–42.
70. Pazhenkottal AP, Nkoulou RN, Ghadri JR, Herzog BA, Küest SM, Husmann L, et al. Impact of cardiac hybrid single-photon emission computed tomography/computed tomography imaging on choice of treatment strategy in coronary artery disease. *Eur Heart J.* 2011;32:2824–9.
71. Romero-Farina G, Candell-Riera J, Aguadé-Bruix S, Castell-Conesa J, García-Dorado G. Impacto de la gated-SPECT de perfusión miocárdica en la indicación de una coronariografía en pacientes con miocardiopatía isquémica. *Rev Esp Med Nucl.* 2011;30:141–6.
72. Romero-Farina G, Candell-Riera J, Milá M, Aguadé-Bruix S, García-Dorado D. Assessment of left ventricular contractile reserve by means of myocardial perfusion gated SPECT in patients with early systolic dysfunction after acute myocardial infarction and in patients with chronic ischemic cardiomyopathy. *Nucl Med Commun.* 2011;32:583–90.
73. Pizzi MN, Sabaté-Fernández M, Aguadé-Bruix S, Romero-Farina G, Cuberas-Borrós G, De León G, et al. Paradoxical pattern in regions with myocardial necrosis in myocardial perfusion gated SPECT with 99mTc-tetrofosmin. *J Nucl Cardiol.* 2012;19:515–23.
74. Jaarsma C, Leiner T, Bekkers SC, Crijns HJ, Wildberger JE, Nagel E, et al. Diagnostic performance of noninvasive myocardial perfusion imaging using single-photon emission computed tomography, cardiac magnetic resonance, and positron emission tomography imaging for the detection of obstructive coronary artery disease. *J Am Coll Cardiol.* 2012;59:1719–28.
75. Min JK, Dunning A, Lin FY, Achenbach S, Al-Mallah M, Budoff MJ, et al. Age and sex-related differences in all-cause mortality risk based on coronary computed tomography angiography findings. Results from the International Multicenter CONFIRM of 23,854 patients without known coronary artery disease. *J Am Coll Cardiol.* 2011;58:849–60.
76. Greupner J, Zimmermann E, Grohmann A, Dübel HP, Althoff T, Borges AC, et al. Head to head comparison of left ventricular function assessment with 64-row computed tomography, biplane left cineventriculography, and both 2- and 3-dimensional transthoracic echocardiography: comparison with magnetic resonance imaging as the reference standard. *J Am Coll Cardiol.* 2012;59:1897–907.
77. Koo BK, Erglis A, Doh JH, Daniels DV, Jegere S, Min JK, et al. Diagnosis of ischemia-causing coronary stenoses by noninvasive fractional flow reserve computed from coronary computed tomographic angiograms. Results from the prospective multicenter DISCOVER-FLOW study. *J Am Coll Cardiol.* 2011;58:1989–97.
78. Estornell-Erill J, Igual-Muñoz B, Monmeneu-Menadas JV, Soriano-Navarro C, Valle-Muñoz A, Vilar-Herrero JV, et al. Diagnóstico etiológico de la disfunción ventricular izquierda con tomografía computarizada: comparación con coronariografía y cardiiorresonancia. *Rev Esp Cardiol.* 2012;65:517–24.
79. Litt HI, Gatsonis C, Snyder B, Singh H, Miller CD, Entikri DW, et al. CT angiography for safe discharge of patients with possible acute coronary syndromes. *N Engl J Med.* 2012;366:1393–403.
80. Hoffmann U, Truong QA, Schoenfeld DA, Chou ET, Woodard PK, Nagurney JT, et al. for the ROMICAT-II Investigators. Coronary CT angiography versus standard evaluation in acute chest pain. *N Engl J Med.* 2012;367:299–308.
81. Mulders TA, Sivapalaratnam S, Stroes ES, Kastelein JJ, Guerci AD, Pinto-Sietsma SJ. Asymptomatic individuals with a positive family history for premature coronary artery disease and elevated coronary calcium scores benefit from statin treatment. *JACC Cardiovasc Imaging.* 2012;5:252–60.
82. Willson AB, Webb JG, Labounty TM, Achenbach S, Moss R, Wheeler M, et al. 3-dimensional aortic annular assessment by multidetector computed tomography predicts moderate or severe paravalvular regurgitation after transcatheter aortic valve replacement: a multicenter retrospective analysis. *J Am Coll Cardiol.* 2012;59:1287–94.
83. Jilali H, Kashif M, Fontana G, Furugen A, Shiota T, Friede G, et al. Cross-sectional computed tomographic assessment improves accuracy of aortic annular sizing for transcatheter aortic valve replacement and reduces the incidence of paravalvular aortic regurgitation. *J Am Coll Cardiol.* 2012;59:1275–86.
84. Thygesen K, Alpert JS, Jaffe AS, Simoons ML, Chaitman BR, White HD. Third universal definition of myocardial infarction. *Eur Heart J.* 2012;33:2551–67.
85. Assomull RG, Shakespeare C, Kalra PR, Lloyd G, Gulati A, Strange J, et al. Role of cardiovascular magnetic resonance as a gatekeeper to invasive coronary angiography in patients presenting with heart failure of unknown etiology. *Circulation.* 2011;124:1351–60.
86. Klem I, Weinsaft JW, Bahnson TD, Hegland D, Kim HW, Hayes B, et al. Assessment of myocardial scarring improves risk stratification in patients evaluated for cardiac defibrillator implantation. *J Am Coll Cardiol.* 2012;31:408–20.
87. Jogiya R, Kozerke S, Morton G, De Silva K, Redwood S, Perera D, et al. Validation of dynamic 3-dimensional whole heart magnetic resonance myocardial perfusion imaging against fractional flow reserve for the detection of significant coronary artery disease. *J Am Coll Cardiol.* 2012;60:756–65.
88. Korosoglou G, Gitsioudis G, Voss A, Lehrke S, Riedle N, Buss SJ, et al. Strain-encoded cardiac magnetic resonance during high-dose dobutamine stress testing for the estimation of cardiac outcomes: comparison to clinical parameters and conventional wall motion readings. *J Am Coll Cardiol.* 2011;58:1140–9.
89. Todiere G, Aquaro GD, Piaggi P, Formisano F, Barison A, Masci PG, et al. Progression of myocardial fibrosis assessed with cardiac magnetic resonance in hypertrophic cardiomyopathy. *J Am Coll Cardiol.* 2012;60:922–9.
90. Dweck MR, Joshi S, Murigu T, Alpendurada F, Jabbour A, Melina G, et al. Midwall fibrosis is an independent predictor of mortality in patients with aortic stenosis. *J Am Coll Cardiol.* 2011;58:1271–9.
91. Igual B, Zorio E, Maceira A, Estornell J, Lopez-Lereu MP, Monmeneu JV, et al. Resonancia magnética cardíaca en miocardiopatía arritmogénica. Tipos de afección y patrones de realce tardío de gadolinio. *Rev Esp Cardiol.* 2011;64:1114–22.
92. Kawut SM, Barr RG, Lima JA, Praetgaard A, Johnson WC, Chahal H, et al. Right ventricular structure is associated with the risk of heart failure and cardiovascular death: The MESA-right ventricle study. *Circulation.* 2012;126:1681–8.
93. Feng D, Glockner J, Kim K, Martinez M, Syed IS, Araoz P, et al. Cardiac magnetic resonance imaging pericardial late gadolinium enhancement and elevated inflammatory markers can predict the reversibility of constrictive pericarditis after antiinflammatory medical therapy: a pilot study. *Circulation.* 2011;124:1830–7.