

ARRHYTHMIAS

Electrophysiological and Clinical Characterization of Left Atrial Macroreentrant Tachycardia

Carina P. Cantale, Francisco García-Cosío, María A. Montero, Agustín Pastor, Ambrosio Núñez and Antonio Goicolea

Servicio de Cardiología. Hospital Universitario de Getafe. Madrid.

Background and objective. We are reporting the characteristics of 9 patients with left atrial macroreentrant tachycardia, an arrhythmia not well studied in man.

Patients and method. Mean age was 60 years and 7 were men. Tachycardia was spontaneous in 6 and induced in 3. Two had no heart disease, 2 sick sinus syndrome, 3 aortic prosthesis, 2 hypertension, 1 cardiomyopathy and 1 chronic bronchitis. Simultaneous recordings from right atrial, coronary sinus and right pulmonary artery were obtained at baseline and with atrial pacing. Macroreentrant tachycardia was diagnosed when entrainment with fusion was documented.

Results. Cycle length was 230-440 ms (287 ± 67). The ECG showed atypical flutter in 3 patients and P waves with flat baseline in 6. Coronary sinus activation was distal to proximal in 7. Right atrial activation was circular in 3 with previous typical flutter ablation. Entrainment from the right atrium produced long return cycles in the right atrial recordings, but equal to basal tachycardic cycle in coronary sinus recordings. Entrainment from the coronary sinus produced local return cycles equal to basal cycle in 8 and prolonged in 1. After stimulation, 4 recovered sinus rhythm, 4 went to atrial fibrillation and 1 had no change. After a follow-up of 9-19 months 5 remain in sinus rhythm treated with antiarrhythmic drugs and/or atrial pacing.

Conclusions. Left atrial macroreentrant tachycardia is associated with organic heart disease. The ECG most frequent pattern tends to show P waves with flat baseline at a relatively slow rate. Most circuits turn clockwise in anterior view. Atrial stimulation is not very effective for cardioversion to sinus rhythm. The prognosis of long term rhythm is uncertain.

Key words: Atrial flutter. Arrhythmia. Electrophysiology. Mapping. Reentry.

Dr. Cantale has received a grant from Fundación Miguel Servet of Medtronic Ibérica S.A.

Correspondencia: Dr. F. García-Cosío.
Servicio de Cardiología. Hospital Universitario de Getafe.
Ctra. de Toledo, km 12,5. 28905 Getafe. Madrid. Spain
Correo electrónico: cantale@hotmail.com

Received 13 February 2001
Accepted for publication 24 May 2001

Caracterización electrofisiológica y clínica de la taquicardia macrorreentrante auricular izquierda

Introducción y objetivos. Describimos las características de 9 pacientes con taquicardia macrorreentrante auricular izquierda, un tipo mal conocido de arritmia.

Pacientes y método. La edad media de los pacientes era 60 años y siete eran varones. La taquicardia fue espontánea en 6 casos e inducida en tres. En 2 enfermos no había cardiopatía, tres tenían una prótesis aórtica, dos disfunción sinusal, dos hipertensión arterial, uno miocardiopatía dilatada y uno bronquitis crónica. Se obtuvieron registros simultáneos de la aurícula derecha, el seno coronario y la arteria pulmonar derecha. Se diagnosticó taquicardia macrorreentrante en presencia de encarrilamiento con fusión en los registros endocavitarios.

Resultados. La longitud de ciclo era 230-440 ms (287 ± 67) y el patrón de ECG de aleteo era atípico en 3 pacientes y onda P con línea isoeletrica en seis. El seno coronario se activaba de distal a proximal en 7 casos. La activación de la aurícula derecha era circular en 3 enfermos con ablación previa de aleteo típico. El encarrilamiento desde la aurícula derecha puso de manifiesto pausas de retorno largas en los registros de la aurícula derecha e iguales al ciclo de la taquicardia en el seno coronario. El encarrilamiento desde el seno coronario evidenció una pausa local igual al ciclo basal en 8 pacientes y prolongada en uno. Con la estimulación, 4 enfermos pasaron a ritmo sinusal, cuatro a fibrilación auricular y uno no cambió. Un total de 5 pacientes se mantuvieron en ritmo sinusal entre 9-19 meses con fármacos antiarrítmicos y/o estimulación auricular.

Conclusiones. La taquicardia macrorreentrante auricular izquierda se asocia a cardiopatía. El patrón más frecuente es de onda P con línea isoeletrica y frecuencia relativamente lenta. La mayoría giran en sentido «horario» en visión anterior. La estimulación es poco eficaz para restablecer el ritmo sinusal. El pronóstico del ritmo a largo plazo es incierto.

Palabras clave: Aleteo auricular. Arritmia. Electrofisiología. Reentrada. Mapeo.

INTRODUCTION

In the last 10 years knowledge of the mechanisms of atrial tachycardia has advanced greatly as a result of cardiac electrophysiological studies (mapping) complemented by response to stimulation. Common

ABBREVIATIONS

MRT: macroreentrant tachycardia
 RA: right atrium
 LA: left atrium
 CS: coronary sinus
 RPA: right pulmonary artery
 CL: cycle length

flutter has been characterized as a macroreentrant tachycardia (MRT) around anatomic and functional obstacles in the right atrium (RA) with a counter-clockwise circuit (oblique left anterior view). Reverse flutter (clockwise) has been described, which uses the same circuit with activation in the opposite direction.¹⁻⁴ Other right atrial MRT are caused by surgical scars, generally after surgery for congenital heart disease.^{5,6} Tachycardia with presumably functional obstacles (areas of low-voltage potentials) has been described in patients without previous surgery.⁷ The localization and description of these MRT circuits has made it possible to perform ablation of the critical isthmuses, thus permanently interrupting the mechanism of the arrhythmia.

MRTs of the left atrium (LA) have not been studied systematically until very recently. The only publication on the topic is that of Jaïs et al.⁸ who used cardiac electrophysiological studies with electromagnetic localization of the catheter position in the LA to describe various types of circuit. These circuits are generally several centimeters in diameter and turn around anatomo-

mic structures and low-voltage zones, possibly related with scar tissue. These left atrial MRTs can be interrupted, although the presence of large low-voltage zones could denote the presence of serious, possibly irreversible, myocardial damage, and the prognosis for the long-term recovery of contractile function is dubious.

Given the risk of left intra-atrial electrophysiological studies, it would be useful to define methods for diagnosing left atrial MRT without having to resort to transeptal puncture. We report our experience with 9 cases of left atrial MRT diagnosed by electrophysiological studies of the RA, coronary sinus (CS), and right pulmonary artery (RPA) and the study of the fusion patterns and return cycles after transitory entrainment in multiple simultaneous recordings.

PATIENTS AND METHODS

Patients

We studied 9 patients (7 males) ranging in age from 40 to 81 years (mean \pm SD = 60 \pm 16) with left atrial MRT that was spontaneous (6 cases) or induced in the electrophysiological study (3 cases). Seven of the 9 patients (77.7%) had cardiovascular disease, including 3 with previous aortic valve surgery, 2 sinus node dysfunction, 2 hypertension, 1 chronic obstructive pulmonary disease, and 1 dilated cardiomyopathy of unclear origin. Two patients showed no appreciable structural heart disease.

In 6 patients the electrocardiogram (ECG) revealed regular atrial tachycardia with P waves separated by an isoelectric baseline (Figure 1) and in the other 3 pa-

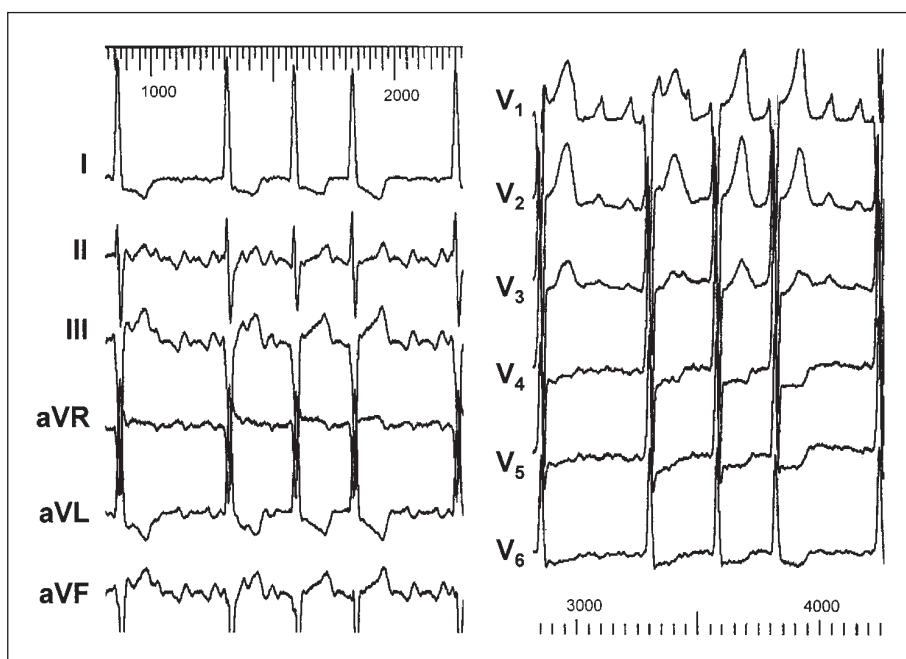


Fig. 1. Twelve-lead ECG of patient 9 in which tachycardia with an isoelectric line between P waves is visible. Recording speed 25 mm/s.

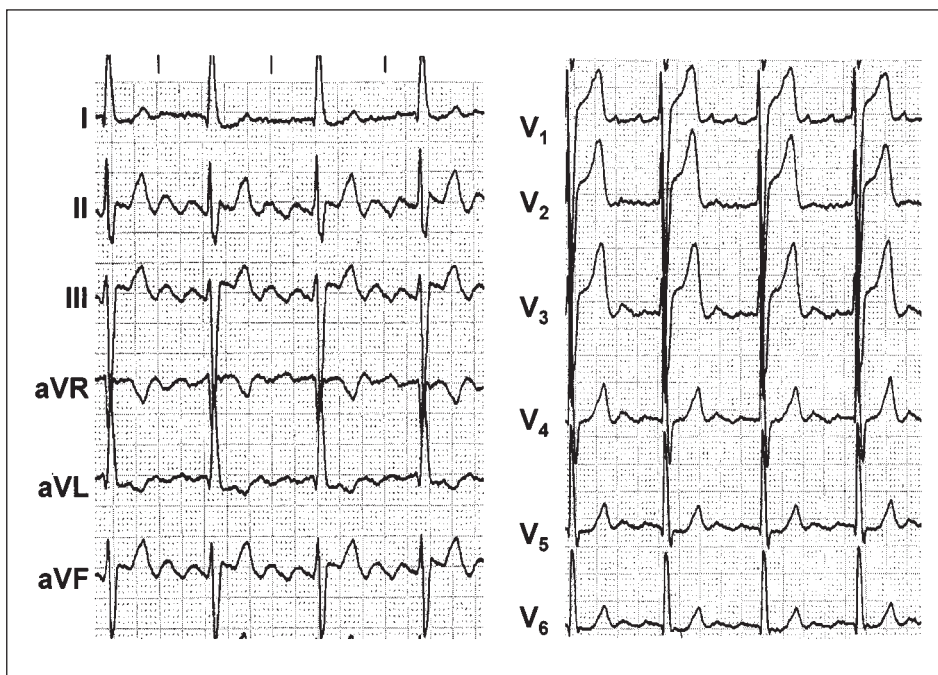


Fig. 2. Twelve-lead ECG of patient 5 in which atypical atrial flutter can be seen. Recording speed 25 mm/s.

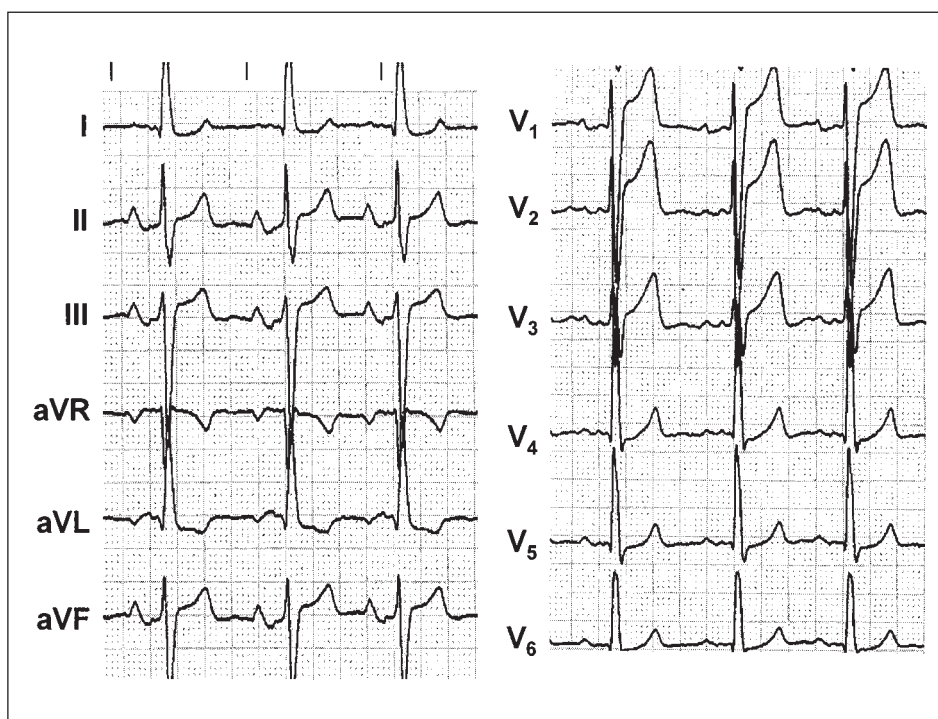


Fig. 3. Twelve-lead ECG in sinus rhythm in which blockade of the Bachmann bundle can be seen (biphasic P wave in II-III and aVF). Recording speed 25 mm/s.

tients, atypical flutter defined as a continuous undulation without an isoelectric baseline (Figure 2). In 4 of the 6 patients analyzed in sinus rhythm, signs of advanced interatrial conduction disorder were observed, with a pattern of blockade of the Bachmann bundle in the surface ECG (Figure 3). Seven of the 9 patients had other documented atrial arrhythmias (Table 1): 2 had a history of atrial fibrillation, 2 right atrial MRT, 2

common flutter, and one focal atrial tachycardia of the septal RA.

Electrophysiological study

The electrophysiological study was made in fasting conditions and mild sedation with midazolam after obtaining informed consent from the patient.

TABLE 1. Clinical and electrophysiological characteristics of 9 patients with left atrial macroreentrant tachycardia

Patients	Age (years)	Organic disease	Cycle length	Anterior/septal RA activation	LAMRT	Coronary sinus activation	Fusion	Other arrhythmias	Drugs
1	77	Sinus node dysfunction	255	Simultaneous/ascending	Induced	Distal to proximal	Constant	Atrial fibrillation	Atenolol
2	78	Aortic valve replacement	310	Simultaneous/simultaneous	Clinical manifestations	Simultaneous	Progressive	No	Amiodarone
3	58	AHT	330	Ascending/ascending	Clinical manifestations	Distal to proximal	Progressive	Atrial fibrillation	Amiodarone
4	65	DCM sinus node dysfunction	250	Simultaneous/simultaneous	Clinical manifestations	Distal to proximal	Progressive	Free wall RAMRT	Digoxin
5	81	AHT, COPD	235	Descending/ascending	Clinical manifestations	Proximal to distal	Progressive	Atrial flutter	No
6	40	Aortic valve replacement	280	Simultaneous/ascending	Clinical manifestations	Distal to proximal	Progressive	No	Digoxin
7	40	No	440	Descending/ascending	Induced	Distal to proximal	Constant	RAMRT	No
8	55	No	250	Descending/ascending	Induced	Distal to proximal	Progressive	Atrial flutter	No
9	49	Aortic valve replacement	230	Ascending/ascending	Clinical manifestations	Distal to proximal	Constant	Focal AT	Amiodarone

AHT indicates arterial hypertension; AT, atrial tachycardia; COPD, chronic obstructive pulmonary disease; CS, coronary sinus; DCM, dilated cardiomyopathy of origin unknown; LAMRT, left atrial macroreentrant tachycardia; RA, right atrium; RAMRT, right atrial macroreentrant tachycardia.

Antiarrhythmic drugs were discontinued 24 to 36 h before the study, except in 3 patients who received amiodarone (1 g per week), 2 digoxin, and 1 who received beta blockers.

Intra-atrial electrophysiological study

The cardiac electrophysiological study was made using an electrode catheter with 12 pairs of poles (pole separation 2 mm and pair separation 8 mm, Bard Electrophysiology Inc., MA, USA) as the stable reference in the RA. The electrode catheter was inserted through the femoral vein and placed against the anterolateral and septal walls (Figure 4). LA activity generally was recorded with a decapolar electrode catheter (pole separation 2 mm and pair separation 5 mm) in

the coronary sinus and an electrode catheter with deflectable tip in the RPA. Six to 10 simultaneous recordings were made of the RA and 2 to 5 of the coronary sinus. In 3 patients, electrograms of the cephalad left atrium were recorded from the RPA (Figure 5). Bipolar recordings (30-500 Hz) were stored on magnetic tape (FM analog recording) or optical disk (digitalized at 1 KHz) for later analysis. Measurements were made at a recording speed of 100 mm/s.

Transitory entrainment

Changes in activation during RA or CS stimulation were studied in all the recordings together. Atrial stimulation began at a cycle length (CL) 10 ms shorter than the CL of the MRT to avoid modifying circuit

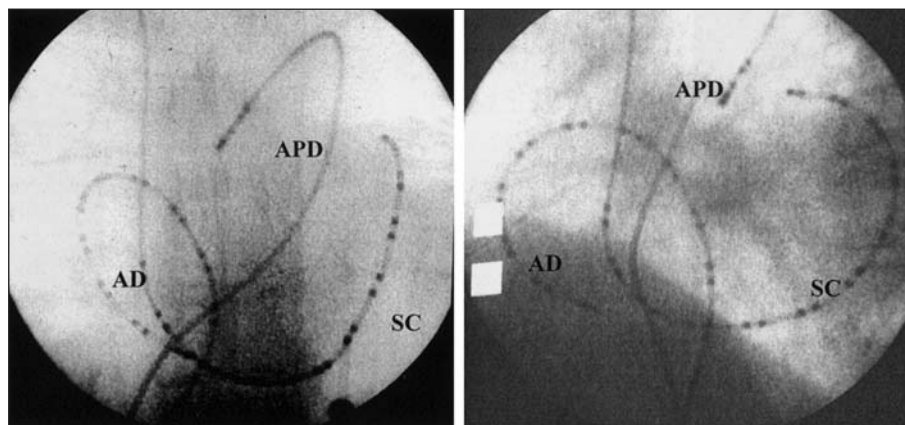


Fig. 4. Radioscopic image in antero-posterior and oblique left anterior views. Location of a 24-pole catheter in the right atrium and coronary sinus and deflectable-tip catheter in the right pulmonary artery.

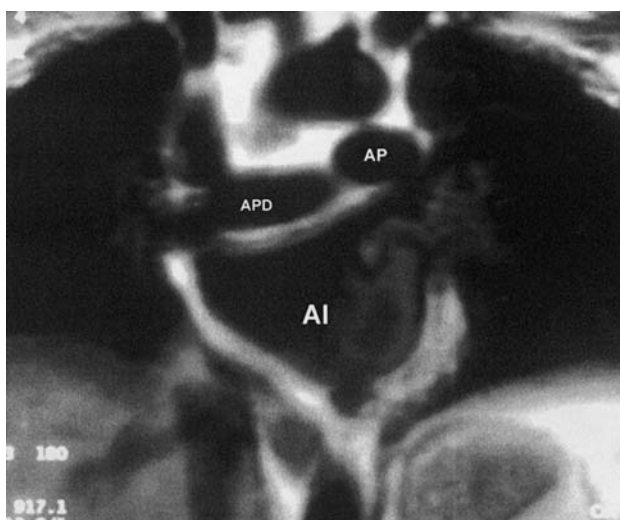


Fig. 5. Magnetic resonance imaging (coronal section) showing the relation between the right pulmonary artery (RPA) and left atrial cephalad face.

properties, such as induction of delayed conduction dependent on increased frequency.⁹ In the recordings made at a distance from the stimulation point, the return cycle was measured after the last entrained electrogram.

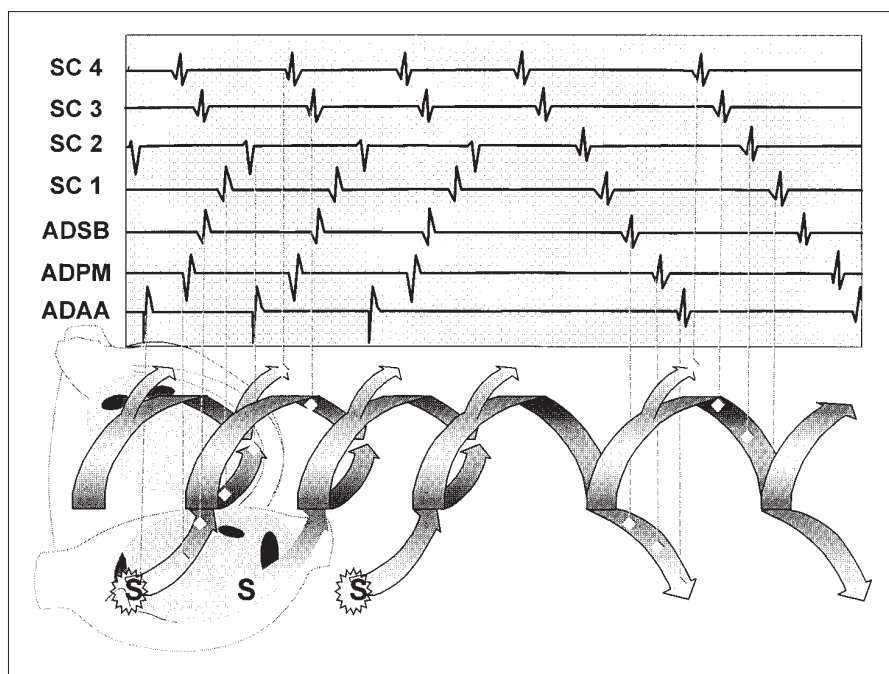
Definition of terms

The diagnosis of left atrial MRT required demonstration of entrainment with progressive and/or constant fusion and return cycles (20 ms difference) equal to the baseline cycle of the tachycardia in the CS and/or RPA recordings. A diagram of the correlation between the changes in activation and the recordings is shown in figure 6 with the aid of an helicoidal representation of reentry.¹⁰ The existence of entrainment with constant and/or progressive fusion indicates the presence of a large circuit (MRT) because small circuits (microreentry) can be entrained but do not exhibit fusion.¹¹ The return cycle inside and outside the MRT circuit is also shown in Figure 6.

Transitory entrainment was considered to be established when all electrograms in 2 trains of stimulation increased in frequency to that of stimulation in all the recording points, and the tachycardia immediately returned to the baseline CL when stimulation stopped, in at least in one recording, even if not at the point of stimulation.¹² The return cycle at any point in the recording was considered to be the first cycle that did not maintain the stimulated CL after discontinuing stimulation.

Constant fusion was considered to be present when a partial change occurred in the sequence of electrograms during entrainment, with recovery of the baseli-

Fig. 6. Diagram of the changes in the electrograms recorded inside and outside a left atrial macroreentrant tachycardia circuit during entrainment from the upper anterior right atrium. In the upper panel are appreciated the electrograms made at the points in the circuit marked with vertical dotted lines. During spontaneous activation (right), the sequence CS3 to CS1 is continuous, indicating distal to proximal activation of the CS. During entrainment, the antidromic wavefront reverses CS1-C2 activation, as indicated by a change in the sequence of these recordings, but produces no change in the CS3-CS2 sequence, which represents the orthodromic wavefront (fusion). The collision occurs in CS2 and the form, but not the sequence, of the electrogram changes. After stimulation, the cycle length of electrograms of the circuit and a point (CS4) outside the circuit, activated orthodromically during entrainment, returns to baseline value. The return cycles in RA recordings are long. In the lower panel, the temporal dimension of reentrant activation is illustrated, producing a helicoidal form 11. The superimposed atrial scheme is provided as a guide to the anatomic position of each recording and the circuit. Stimuli (S) applied to the upper right atrium with a shorter cycle than the spontaneous cycle capture the reentrant circuit and are propagated orthodromically and antidromically. The antidromic wavefront collides with the orthodromic wavefront from the previous stimulus and is extinguished. When stimulation is discontinued, the baseline reentry is restored (last two cycles). CS1-4 indicates proximal to distal CS; LSRA, lower septal RA; MPRA, middle posterior RA; RA, right atrium; UARA, upper anterior RA.



ne sequence when stimulation ended. No attempt was made to analyze the possible fusion pattern in the ECG because of the difficulty of analyzing P waves or flutter waves due to interference by QRS complexes and T waves.

Progressive fusion was defined as a change in the degree of fusion upon increasing the frequency of entrainment, with displacement of the point of collision of the activation wavefronts (the reentrant orthodromic and stimulated antidromic wavefronts) near the site of the circuit 9.

RESULTS

The electrophysiological findings are summarized in table 1. The cycle length of left atrial MRT in the 9 patients was 230-440 ms (287 ± 67), and 236-440 ms (285 ± 77) in 6 patients not treated with amiodarone. Activation of the septal RA was ascending in 7 patients and simultaneously cephalocaudad in 2 patients. Activation of the anterior face was simultaneously cephalocaudad in 4 cases, descending in 3 and ascending in 2. In 3 patients with previous ablation of the cavotricuspid isthmus (2 for typical flutter and 1 for right atrial TMR dependent on the isthmus),

RA activation was descending in the anterior wall and ascending in the septum, simulating typical flutter. The CS activation was distal to proximal in 7 patients, proximal to distal in 1, and simultaneous throughout its length in 1. The recorded RA electrograms covered 100% of the CL in 2 patients with circular activation of the RA and a CL of 250 and 235 ms; in the rest they covered 27-50% of the CL. The combination of the RA, CS, and RPA electrograms covered 48-100% (mean, $80 \pm 18\%$) of the tachycardia cycle.

Entrainment from the anterior and septal RA revealed return cycles 30 ms longer than the baseline CL throughout the RA, while the return cycle was equal to the baseline CL in the CS and/or RPA in all cases (Figure 7). During entrainment, constant fusion was demonstrated in all patients (Figures 7 and 8) and progressive fusion in 6 patients (Figure 9). In 4 patients with progressive fusion, the point of collision of the orthodromic (entrained) and antidromic (stimulated) wavefronts could be identified in the CS. The displacement of the point of collision in the CS with shortening of the stimulation CL was proximal to distal in 3 patients who had distal to proximal activation and RA stimulation, and distal to proximal in 1 patient with

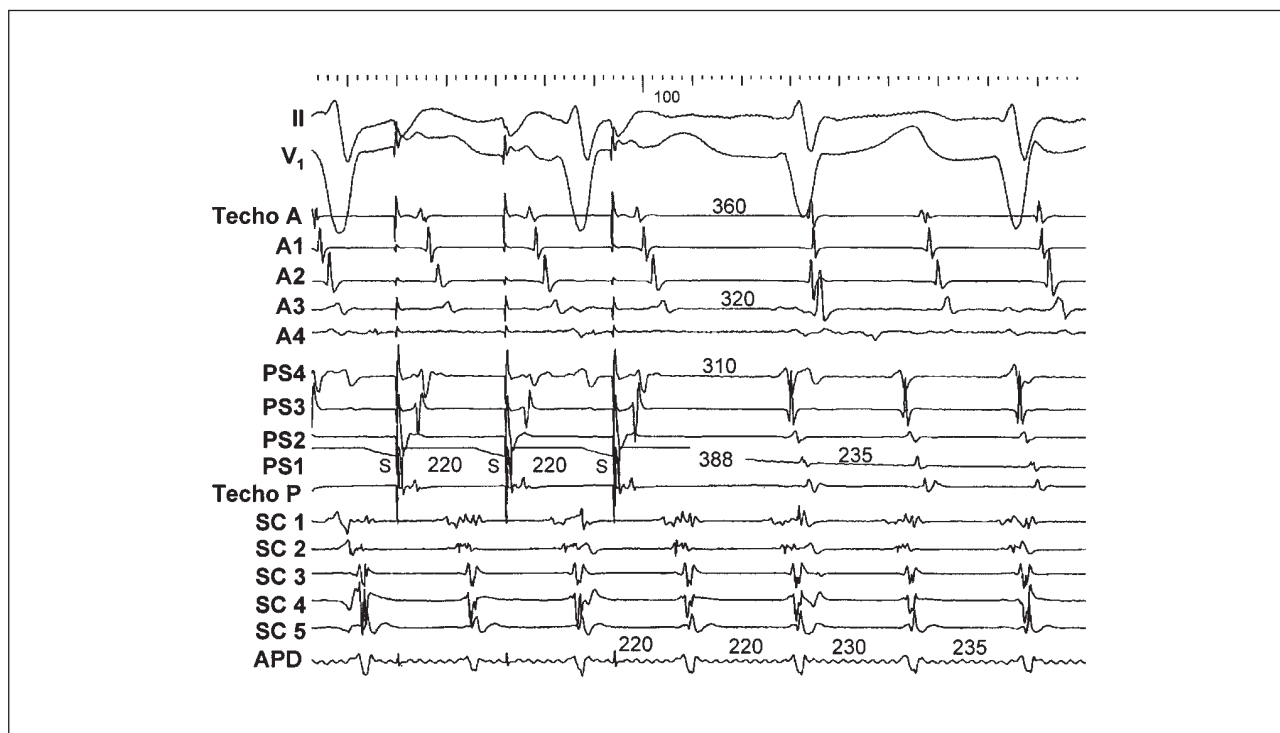


Fig. 7. Entrainment from the upper septal RA (stimulation cycle length 220 ms) of left atrial macroreentrant tachycardia. The first two recordings show leads I and V1 of the surface ECG. The other recordings show bipolar electrograms of the anterior face (A cephalad to A4) and septal face (PS4 to P cephalad) of the right atrium (RA), proximal to distal coronary sinus (CS1 to CS5), and right pulmonary artery (RPA). Long return cycles are appreciated on the anterior and septal face of the RA, equal to the tachycardia cycle in the electrogram of the right pulmonary artery. A cephalad indicates anterior cephalad RA; A1, upper anterior RA; A2-A3, middle anterior RA; A4, lower anterior RA; CS, coronary sinus; P cephalad, posterior cephalad RA; PS1, upper septal RA; PS2-PS3, middle septal RA; PS4, lower septal RA; RPA, right pulmonary artery; S, stimulus. Recording speed 100 mm/s.

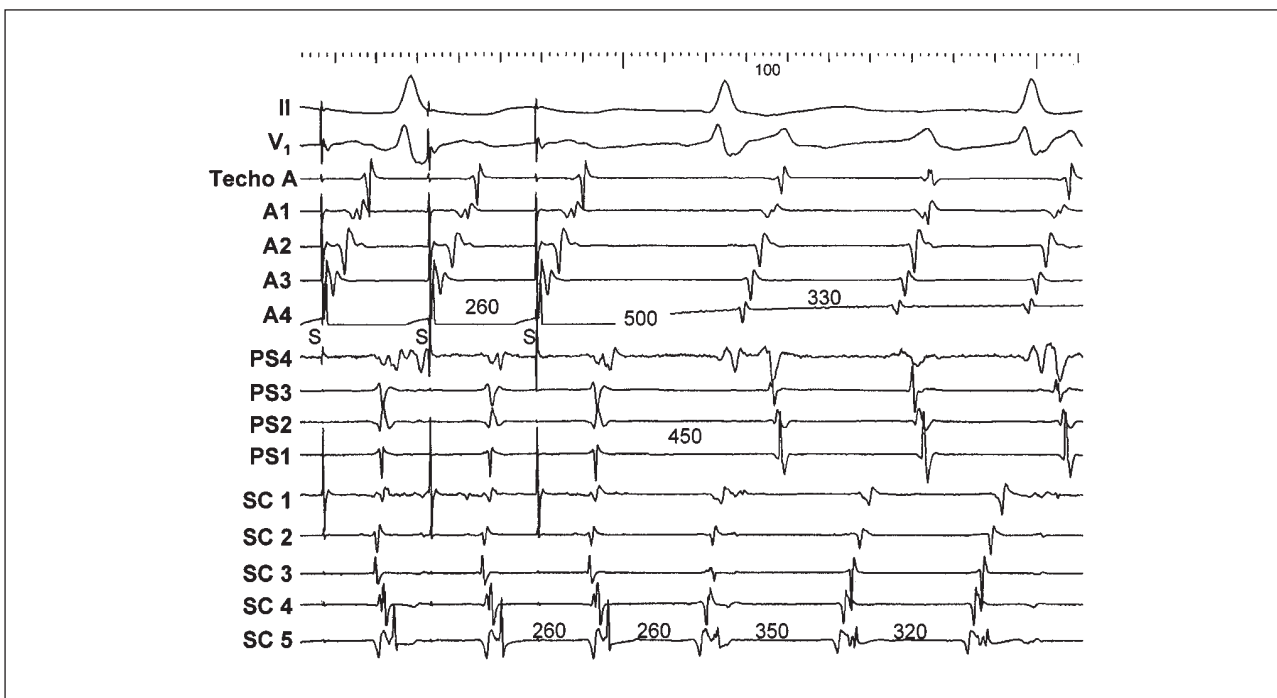


Fig. 8. Entrainment from the lower right atrium of a left atrial macroreentrant tachycardia (stimulation cycle length 260 ms). The first two recordings show leads I and V₁ of the surface ECG. The other recordings show bipolar electrograms of the anterior face (A cephalad to A4) and septal face (PS4 to P cephalad) of the right atrium (RA), and of the proximal to distal coronary sinus (CS1 to CS5). A slight change in the activation of the septal face of the RA and the collision of two activation wavefronts in CS3-CS4 of the coronary sinus (constant fusion) are appreciated. A cephalad indicates anterior cephalad RA; A1, upper anterior RA; A2-A3, middle anterior RA; A4, lower anterior RA; CS, coronary sinus; P cephalad, posterior cephalad RA; PS1, upper septal RA; PS2-PS3, middle septal RA; PS4, lower septal RA; RPA, right pulmonary artery; S, stimulus. Recording speed 100 mm/s.

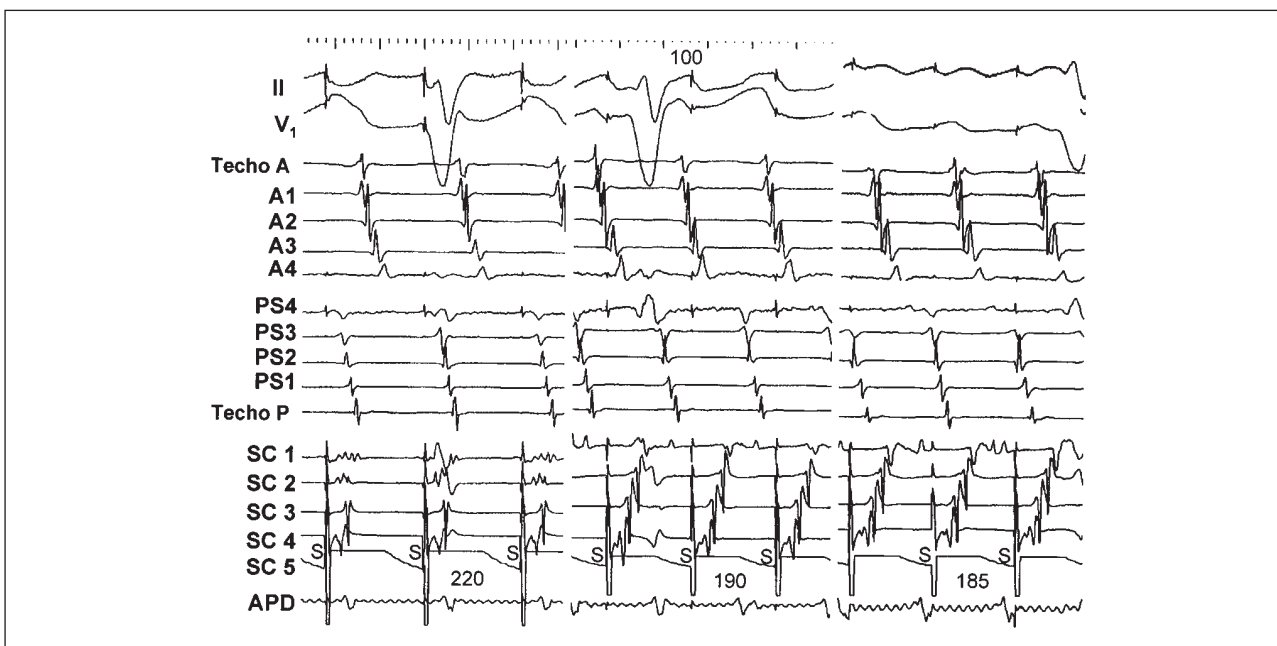


Fig. 9. Entrainment from the distal coronary sinus of a left atrial macroreentrant tachycardia at different stimulation cycle lengths (left panel 220 ms, central panel 190 ms, and right panel 185 ms). The first two recordings show leads I and V₁ of the surface ECG. The other recordings show bipolar electrograms of the anterior face (A cephalad to A4) and septal face (PS4 to P cephalad) of the right atrium (RA), proximal to distal coronary sinus (CS1 to CS5), and right pulmonary artery (RPA). The displacement of the zone of collision of stimulated and reentrant wavefronts (progressive fusion) toward the proximal coronary sinus is evident. A cephalad indicates anterior cephalad RA; A1, upper anterior RA; A2-A3, middle anterior RA; A4, lower anterior RA; CS, coronary sinus; P cephalad, posterior cephalad RA; PS1, upper septal RA; PS2-PS3, middle septal RA; PS4, lower septal RA; RPA, right pulmonary artery; S, stimulus. Recording speed 100 mm/s.

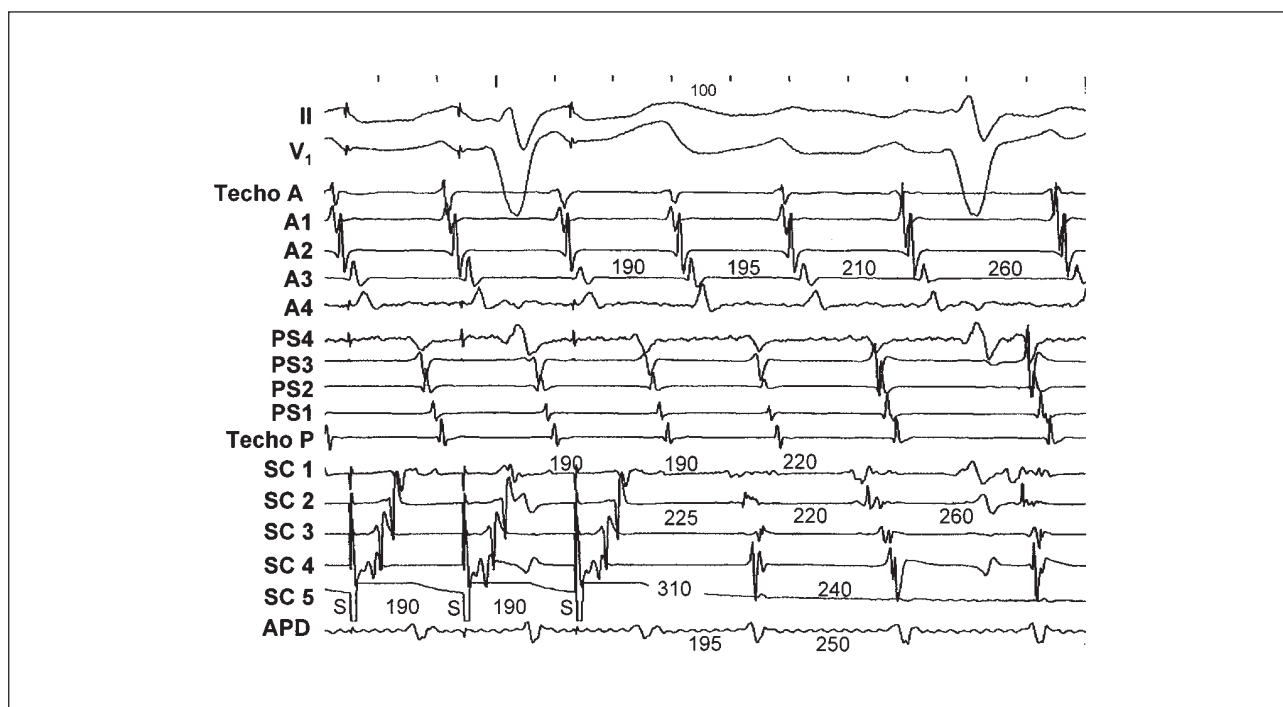


Fig. 10. Entrainment from the distal coronary sinus (stimulation cycle length 190 ms). The first two recordings show leads I and V1 of the surface ECG. The other recordings show bipolar electrograms of the anterior face (A cephalad to A4) and septal face (PS4 to P cephalad) of the right atrium (RA), proximal to distal coronary sinus (CS1 to CS5), and right pulmonary artery (RPA). A prolonged return cycle (310 ms) is seen in the distal coronary sinus (CS5) when stimulation is applied to the same point. In the RA and RPA recordings, the return cycles are equal to the tachycardia cycle length. A cephalad indicates anterior cephalad RA; A1, upper anterior RA; A2-A3, middle anterior RA; A4, lower anterior RA; CS, coronary sinus; P cephalad, posterior cephalad RA; PS1, upper septal RA; PS2-PS3, middle septal RA; PS4, lower septal RA; RPA, right pulmonary artery; S, stimulus. Recording speed 100 mm/s.

proximal to distal activation during distal CS stimulation (Figure 9).

After atrial stimulation, 4 patients went to sinus rhythm, 4 developed atrial fibrillation and 1 remained in left atrial MRT without change. Follow-up data for 9 to 25 months was available for 8 patients. Three remained tachycardic after the study and were treated with frequency control and anticoagulation. Two patients were implanted a DDD pacemaker for sinus node dysfunction. One has not suffered any recurrence in 16 months without antiarrhythmic drugs and the other relapsed at 18 months, but recovered sinus rhythm with oral propafenone. Of 3 patients who received amiodarone (1 g per week), 1 maintained sinus rhythm for 9 months, 1 for 13 months until the patient died in the postoperative period of cardiac valve replacement, and the third relapsed at 19 months and is awaiting a new study or cardioversion.

DISCUSSION

Left atrial MRT has been little studied in human clinical practice. The need for transeptal catheterization makes it difficult to justify a direct cardiac electrophysiological study without a clear therapeutic indication,

so in most cases the diagnosis must be established using indirect techniques, such as observation of the response to stimulation (entrainment). Only very recently, Jaïs et al⁸ published a relatively extensive experience with direct cardiac electrophysiological studies of left atrial MRT. They demonstrated that in most cases circuits are large and activation is routed around combinations of natural obstacles, particularly the mitral valve, and obstacles of unknown nature, in the form of lines of conduction block or zones of low-voltage electrical activity that suggest the absence of functional myocardium. These authors used entrainment techniques to confirm the location of circuits that could not be fully delimited by cardiac electrophysiological study. Only summaries have been published of other experiences, which gives us little information about the anatomic and functional details.^{13,14,20}

The diagnosis of right atrial MRT is easier because recordings of circular activity throughout the entire MRT cycle is very suggestive of macroentry, as opposed to focal activity. However, if transeptal catheterization is not performed, this finding will not be of much help in left atrial MRT because RA activity covers much of the CL, especially when added conduction disorders force activation to be circular.

Entrainment is necessary to distinguish between reentrant activation and «passive» circular activation¹⁵ because, in the case of a RA circuit, return cycles at this point are always equal to the baseline CL.^{9,16} This study applied techniques used in the study of right atrial MRT, including typical flutter, to the diagnosis of left atrial MRT. However, entrainment was supported by multiple recordings in both atria, which, as we have demonstrated in the RA,⁹ make it possible to more easily detect return cycles equal to the baseline CL and signs of fusion than isolated recordings¹⁷ because they provide information from within and around the circuit. In the absence of fusion and/or a complete cardiac electrophysiological study of the LA, the mere detection of concealed entrainment, a criterion used by other authors, does not allow MRT to be distinguished from a focal tachycardia with a microreentrant mechanism¹⁸

In Figure 6 a schema illustrates how a stimulated wavefront from outside the circuit captures a point in the circuit and initiates an antidromic wavefront that collides with, and interrupts, the circuit, and then an orthodromic wavefront reinitiates it, according to the classic description of the entrainment.¹² In this Figure, the inversion of the direction of activation in the part of the circuit captured antidromically can be seen clearly, as reflected by the inversion in the sequence of electrograms recorded in this zone. The point of return is equal to the baseline CL at the point where the stimulated wavefront captures the circuit, but in order to measure the return cycle in orthodromically entrained recordings, one must await the cycle after the first non-fusion cycle because it is still entrained.

However, a return cycle equal to the MRT cycle can occur outside the circuit, if it is activated orthodromically from the circuit during entrainment at a distance (Figure 6). Consequently, this finding does not serve to locate the circuit precisely, although it allows it to be situated in the LA when the return cycles are long in all RA recordings and equal to the CL of the left atrial MRT. Case 5 is an example of this situation, with a return cycle in the distal CS equal to the MRT cycle when entrainment was from the RA, but prolonged when entrainment was from the distal CS (Figure 10).

It is interesting that activation tended to turn «clockwise» around the mitral valve in our cases and those of Jaïs et al.⁸ It is likely that the tendency toward ascending activation of the septal RA is due to the emergence of the activation wavefront around the ostium of the CS. The detection of distal to proximal CS activation during flutter is a sign suggestive of the left-side origin of activation and would contribute to the diagnosis of left atrial MRT when RA activation is counterclockwise, as in common flutter, which may suggest typical flutter in the ECG.

The ECG pattern is equivocal because 6 patients had a well-delimited P wave with isoelectric lines and

relatively low frequencies, even in the absence of treatment with antiarrhythmic drugs, suggestive of «focal» atrial tachycardia. Only 3 patients presented the pattern of continuous waves (flutter) generally associated with macroreentrant tachycardia. The inscription of the P wave generally coincided with RA recordings, indicating that most of the activity in the LA reentrant circuit was low-voltage and not clearly manifested in the ECG. This concurs with the observations of Schoels et al in an experimental model of pericarditis in the dog,¹⁹ where they found this type of situation in the LA reentrant circuits. Therefore, the image of tachycardia «with P waves» in the ECG should not be taken as indicative of focal tachycardia without first performing cardiac electrophysiological studies and entrainment to exclude MRT.

The clinical characteristics of the patients were interesting, suggesting the idea that left atrial MRT is a manifestation of underlying disease of the atrial myocardium. This coincides with the findings of other authors,^{8,20} who also observed an association with heart valve disease and previous surgery. The low-voltage zones in the atrial myocardium and lines of functional blockade could indicate the presence of myocardial lesions, which brings into question the long-term prognosis of the atrial mechanical function and rhythm, although the tachycardia circuit can be interrupted acutely. Only 5 of our patients passed to a stable sinus rhythm during admission, 2 had relapses in a follow-up of 1-2 years and required antiarrhythmic drugs, and 2 required chronic atrial stimulation for sinus node dysfunction.

REFERENCES

1. Cosío FG, Arribas F, López-Gil M, Palacios J. Atrial flutter mapping and ablation I: studying atrial flutter mechanisms by mapping and entrainment. *PACE* 1996; 19: 841-853.
2. Arribas F, López-Gil M, Goicolea A, Cosío FG. *Flutter* auricular: mapeo y ablación con radiofrecuencia. *Rev Esp Cardiol* 1993; 46: 246-254.
3. Kalman JM, Olgin JE, Saxon LA, Lee RJ, Scheinman MM, Lesh MD. Electrocardiographic and electrophysiologic characterization of atypical atrial flutter in man: use of activation and entrainment mapping and implications for catheter ablation. *J Cardiovasc Electrophysiol* 1997; 8: 121-144.
4. Cosío FG, Arribas F, López-Gil M, González HD. Atrial flutter mapping and ablation II: radiofrequency ablation of atrial flutter circuits. *PACE* 1996; 19: 965-975.
5. Van Hare GF, Lesh MD, Ross BA, Perry JC, Dorostkar PC. Mapping and radiofrequency ablation of intraatrial reentrant tachycardia after the Senning or Mustard procedure for transposition of the great arteries. *Am J Cardiol* 1996; 77: 985-991.
6. Kalman JM, Van Hare GF, Olgin JE, Saxon LA, Stark SI, Lesh MD. Ablation of «incisional» reentrant atrial tachycardia complicating surgery for congenital heart disease. Use of entrainment to define a critical isthmus of conduction. *Circulation* 1996; 93: 502-512.

7. Kall JG, Rubenstein DS, Koop DE, Burke MC, Verdino RJ, Lin AC. Atypical atrial flutter originating in the right atrial free wall. *Circulation* 2000; 101: 270-279.
8. Jais P, Shah DC, Haïssaguerre M, Hocini M, Peng JT, Takahashi A et al. Mapping and ablation of left atrial flutters. *Circulation* 2000; 101: 2928-2934.
9. Cosío FG, López-Gil M, Arribas F, Palacios J, Goicolea A, Núñez A. Mechanisms of entrainment of human common flutter studied with multiple endocardial recordings. *Circulation* 1994; 89: 2117-2125.
10. Cosío FG. Helical representation of atrial reentry: a teaching aid for electrophysiology. *J Cardiovasc Electrophysiol* 2000; 11: 484-487.
11. Brugada P, Waldo AL, Wellens HJJ. Transient entrainment and interruption of atrioventricular node tachycardia. *J Am Coll Cardiol* 1987; 9: 769-775.
12. Waldo AL, Plumb VJ, Arciniegas JG, Mac Lean WAH, Cooper TB, Priest MF et al. Transient entrainment and interruption of the atrioventricular bypass pathway type of paroxymal atrial tachycardia: a model for understanding and identifying reentrant arrhythmias. *Circulation* 1983; 67: 73-83.
13. Cheng J, Steiner PR, Lee RJ, Scheinman MM. The region between the right pulmonary veins and fossa ovalis may serve as critical isthmus atypical atrial flutter [resumen]. *PACE* 1999; 22: 704.
14. Ouyang F, Volkman M, Hansen PS, Bansch D, Ernest S, Zhuang S et al. Electroanatomical mapping and conventional entrainment for identification of the entire circuit and critical isthmus for radiofrequency ablation in left atrial macroreentrant tachycardias [resumen]. *Circulation* 1999; 100 (Supl I): 454.
15. Jais P, Shah DC, Haïssaguerre M, Takahashi A, Hocini M, Garrigue S et al. Right atrial criteria to identify left atrial flutter [resumen]. *PACE* 1999; 22: 711.
16. Arenal A, Almendral J, San Román D, Delcan JL, Josephson ME. Frequency and implications of resetting and entrainment with right atrial stimulation in atrial flutter. *Am J Cardiol* 1992; 70: 1292-1298.
17. Henthorn R, Okumura K, Olshansky B, Plumb VJ, Hess PG, Waldo AL. A fourth criterion for transient entrainment: the electrogram equivalent of progressive fusion. *Circulation* 1988; 77: 1003-1012.
18. Bogun F, Bender B, Li Y, Hohnloser SH. Ablation of atypical atrial flutter guided by use of concealed entrainment in patients without prior cardiac surgery. *J Cardiovasc Electrophysiol* 2000; 11: 136-145.
19. Schoels W, Offner B, Brachmann J, Kuebler W, EL-Sherif N. Circus movement atrial flutter in the canine sterile pericarditis model. *J Am Coll Cardiol* 1994; 23: 799-808.
20. Natale A, Richey M, Tomassoni GF, Beheiry S, Rajkovich K, Wides B et al. Clinical characteristics and ablation of left side atrial flutter [resumen]. *J Am Coll Cardiol* 1999; 33 (Supl A): 117.