

## BRIEF REPORTS

# Survival After Two Consecutive Left Ventricular Free Wall Ruptures with an Atypical Occurrence After a Pre-Discharge Exercise Test

Tomás Ripoll Vera, Carlos Fernández Palomeque, José F. Forteza, Oriol Bonnín<sup>a</sup>, Juan Casanova and Armando Bethencourt

Servicio de Cardiología. Hospital Universitario de Son Dureta. <sup>a</sup>Servicio de Cirugía Cardíaca. Policlínica Miramar. Palma de Mallorca.

Left ventricular free wall rupture is an unusual but highly lethal complication of acute myocardial infarction. We report on the extremely rare occurrence of a patient surviving two episodes of free wall rupture within a seven-month period. The first event happened in the course of an exercise testing after a seemingly uncomplicated inferior acute myocardial infarction; the second, seven months after the first, as a pseudoaneurysm in the setting of a new inferior wall infarction. Surgical repair was successful in both instances, with patient remaining asymptomatic in follow-up.

**Key words:** *Myocardial infarction. Exercise. Heart arrest. Aneurysm. Surgery.*

## Supervivencia a rotura cardíaca recurrente de pared libre ventricular izquierda, con presentación atípica tras ergometría postinfarto

La rotura aguda de la pared libre ventricular izquierda es una complicación poco frecuente del infarto agudo de miocardio, pero que comporta una elevada mortalidad. Presentamos el caso infrecuente de un paciente que «sobrevivió» a 2 roturas cardíacas, en ambas ocasiones con una presentación atípica: la primera durante la realización de una ergometría tras un infarto no complicado, y la segunda 7 meses después de la primera, en forma de pseudoaneurisma, en el contexto de la fase hiperaguda de un nuevo infarto inferior. En ambos casos el paciente fue tratado quirúrgicamente con éxito, quedando asintomático en el seguimiento.

**Palabras clave:** *Infarto de miocardio. Ejercicio. Parada cardíaca. Aneurisma. Cirugía.*

## INTRODUCTION

We report an exceptional clinical case of a patient with uncomplicated acute myocardial infarction (AMI) who suffered acute cardiac rupture of the free wall of the left ventricle (CRFW) during pre-discharge exercise testing. This occurs only rarely and has not been reported often in the literature. However, the patient suffered yet another cardiac rupture 7 months later, in the form of a pseudoaneurysm (a very rare complication) that occurred in the acute phase of inferior reinfarction. Surgery was successful in both instances. Recurrence of CRFW is exceptional and has not been reported in the literature to our knowledge.

Correspondencia: Dr. T. Ripoll Vera.  
Santuari, 12 1.º izq. 07006 Palma de Mallorca. Balears. Spain  
Correo electrónico: tomasripoll@airtel.net

Received 23 January 2001  
Accepted for publication 27 May 2001

## CLINICAL CASE

A 70-year-old man, an exsmoker with a high cholesterol level, was seen in the emergency room after 14 h of coronary chest pain. He was diagnosed as inferoposterior AMI, which was initially uncomplicated. Thrombolysis was not performed because it was too late in the evolution and electrical criteria were absent. Peak CPK/CPK-MB was 937/143. Treatment with beta-blockers was begun. An echocardiogram made to stratify postinfarction risk showed that the overall left ventricular function (LV) was preserved, with inferoposterobasal akinesia and inferoposteromedial hypokinesia, but no other findings. On postinfarction day 10, exercise testing was carried out according to the Bruce protocol. In the sixth minute, supraventricular tachycardia with significant depression of the ST segment appeared and the test was discontinued. In the immediate post-stress period, cardiac arrest occurred as a result of electromechanical dissociation, but the patient recovered with advanced cardiopulmonary resuscitation maneuvers. The ECG

## ABBREVIATIONS

AMI: acute myocardial infarction  
 CRFW: cardiac rupture of the left ventricular free wall  
 LV: left ventricle  
 RV: right ventricle

showed a hyperacute inferior subepicardial lesion that normalized rapidly. Suspecting CRFW, an emergency echocardiogram was made, which disclosed severe pericardial effusion in the posterior sac, probably containing blood, and a large thrombus occupying the anterior sac over the free wall of the right ventricle (RV) (Figure 1). There were no signs of acute cardiac tamponade and the image was suggestive of inferoapical perforation. Emergency surgery was performed based on evidence of CRFW, disclosing rupture of the posterior wall of the LV with extension to the lateral RV wall. The defect was repaired with a Dacron patch glued to the epicardium with cyanocrylate. There were no postoperative complications.

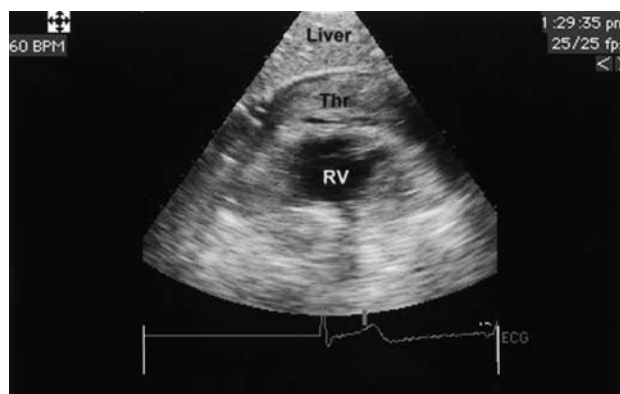
An echocardiogram performed one month after surgery revealed an inferoposterobasal and medial aneurysm, with conservation of overall LV systolic function and no pericardial effusion.

Seven months after the first AMI, the patient suffered inferior reinfarction, with ventricular fibrillation in the first hour of evolution. Electrical cardioversion and reanimation measures resolved the situation. Primary percutaneous coronary angioplasty was performed on the right coronary artery, which had a severe ostial lesion of the circumflex artery and a diffusely affected anterior descending coronary artery. Ventriculography revealed a posterobasal pseudoaneurysm (Figure 2, left). In the echocardiogram, an inferoposterobasal and medial pseudoaneurysm with slowing of the blood flow was observed; LV systolic function was preserved (Figure 2, right). Surgery confirmed the presence of a wide-mouthed pseudoaneurysm (48 × 30 mm) occupied by a large thrombus, which was located in the posterolateral LV outside the area of the first patch. Resection of the pseudoaneurysm, thrombectomy, and closure with a Dacron patch were performed without complications. Coronary revascularization was not performed because of poor distal vessels.

Two months later, a follow-up echocardiogram demonstrated a small inferobasal aneurysmal area with dense echoes (patches) and preserved LV systolic function. Two years after the first AMI, the patient is alive and free of cardiovascular symptoms.

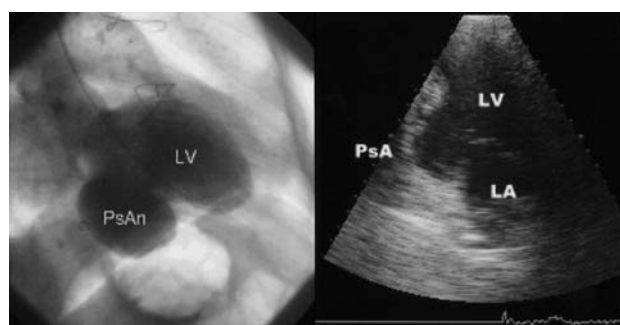## DISCUSSION

CRFW is an infrequent complication, occurring in 3-5% of all AMI<sup>1</sup> and in 10-25% of post-mortem se-



**Fig. 1.** Transthoracic echocardiogram performed during the first cardiac rupture showing a large thrombus occupying the anterior pericardial sac covering the free wall of the right ventricle. The echocardiographic image shown is probably not the most illustrative of free-wall rupture, since it corresponds to a subcostal plane made in a patient in critical condition, which is a technically difficult situation. Liver indicates liver; RV, right ventricle; Thr, thrombus.

ries. After cardiogenic shock, CRFW is the second most frequent cause of hospital death due to AMI. It is debated whether thrombolysis increases its relative incidence<sup>2</sup>, although administration of this treatment in the first 6 h reduces the absolute number of cardiac ruptures as a consequence of the overall decrease in mortality. Forty per cent of CRFW occur in the first 24 h of AMI and 85% in the first week. CRFW is thought to be associated more often with advanced age, female sex, arterial hypertension, primary transmural AMI without previous angina or collateral circulation, and relatively small and uncomplicated infarcts.<sup>3</sup> The diagnosis of CRFW is suggested by its clinical presentation, that is, the appearance of sudden electromechanical dissociation (without previous heart failure), and is confirmed by echocardiographic evidence of a large pericardial effusion with echoes suggestive of the pre-



**Fig. 2.** Left: Ventriculography during the second AMI in which a large posterobasal pseudoaneurysm (second rupture) is visible. Right: Transthoracic echocardiogram showing the left ventricle with a pseudoaneurysm comprising the inferoposterobasal and medial segments, with slow flow inside. LA indicates left atrium; LV, left ventricle; PsA, pseudoaneurysm.

sence blood or hemopericardium. In rare cases, the rupture closes with pericardial adhesion and thrombus formation, producing a pseudoaneurysm. The incidence of this type of CRFW is very low, probably less than 1% of all AMI (less than 0.4% of post mortem studies), and its natural evolution is not well known.<sup>4</sup> The diagnosis of pseudoaneurysm is also echocardiographic, and the recommended treatment in the acute phase is surgical resection, regardless of symptoms, size, or location, because spontaneous rupture of the pseudoaneurysm occurs without warning in one-third of the cases.

In our patient, the first CRFW occurred during exercise testing before hospital discharge, on day 10 of an uncomplicated inferior AMI in which fibrinolysis was not carried out. This test is traditionally considered low-risk in the hospital. In various series of postinfarction patients, very low incidences of CRFW are observed, but it is nonetheless one of the most frequent causes of death during exercise testing. In a series of 151, 949 postinfarction exercise tests (4 weeks, 76% = 14 days), the overall mortality was 0.03%, non-fatal major complications occurred in 0.09%, and other cardiac complications in 1.4%. The incidence of CRFW in this series was 0.1% of all complications (only 2 cases, both in the first 14 days postinfarction), making it an extremely rare complication.<sup>5</sup> In another Spanish series, the reported incidence was 0.03% (in 17,328 postinfarction exercise tests).<sup>6</sup>

Our patient presented several uncommon points of interest:

1. The first CRFW that occurred during hospital exercise testing for AMI is a very rare complication that has rarely been cited in the medical literature (only 3 other cases published).<sup>7-9</sup>

2. The second CRFW occurred as a pseudoaneurysm, which also is an rare postinfarction complication. It has been associated most often with CRFW in the context of posterior or lateral AMI, mainly in patients who survive an episode of CRFW with hemopericardium.<sup>10</sup>

3. Recurrence of CRFW is exceptional. Although there are reports in the bibliography of the recurrence of ruptures of the interventricular septum after surgery,<sup>11</sup> this is due more often to imperfect surgical treatment (an incompletely closed or loose patch) than to recurrence *per se*. We found no references in the bibliography to a situation like that of our patient, eg, recurrence of a rupture of the free wall (not the interventricular septum) adjacent to the site of the first rupture,

but unrelated with the previous intervention (the patch of the first rupture was well sealed).

4. CRFW has traditionally been considered a serious clinical condition with a high mortality that requires emergency surgery.<sup>12-14</sup> Our patient has survived two cardiac ruptures within a 7-month period, requiring advanced cardiopulmonary resuscitation measures in both cases, which confirms the importance of these measures in the treatment of complications of AMI.

## REFERENCES

- López-Sendón J, González A, López de Sá E, Coma-Canella I, Roldán I, Domínguez F et al. Diagnosis of subacute ventricular wall rupture after acute myocardial infarction: sensitivity and specificity of clinical, hemodynamic and echocardiographic criteria. *J Am Coll Cardiol* 1992; 19: 1145-1153.
- Roldán I, López-Sendón J, Perdigo C. Causes of death after thrombolytic therapy in acute myocardial infarction. *Eur Heart J* 1991; 12 (Supl): 267.
- Björck G, Mogensen L, Nyquist O, Orinius E, Sjogren A. Studies of myocardial rupture with tamponade in acute myocardial infarction: clinical features. *Chest* 1972; 61: 4-6.
- López de Sá E, López-Sendón JL, Rubio R. Infarto agudo de miocardio: clínica, evolución y complicaciones. En: Delcán JL, editor. *Cardiopatía isquémica*. Madrid: ENE ediciones, 1999; 583-584.
- Hamm LF, Crow RS, Stull GA, Hannan P. Safety and characteristic of exercise testing early after acute myocardial infarction. *Am J Cardiol* 1989; 63: 1193-1197.
- Cantalapiedra JL, García J, Del Castillo S, Fuentes ME. La ergometría en la cardiopatía isquémica. En: Delcán JL, editor. *Cardiopatía isquémica*. Madrid: ENE ediciones, 1999; 179-211.
- Bodi V, Monmeneu JV, Marin F. Acute cardiac rupture complicating pre-discharge exercise testing. A case report with complete echocardiographic follow-up. *Int J Cardiol* 1999; 68: 333-335.
- Pedersen P, Nielsen IB. Myocardial rupture during exercise ECG. *Ugeskr Laeger* 1998; 160: 1331-1334.
- Carlson R, Pedon L, Maiolino P. Heart rupture during maximal exercise test before hospital discharge after acute myocardial infarction. *G Ital Cardiol* 1996; 26: 539-544.
- Figueras J, Cortadellas J, Calvo F, Soler-Soler J. Relevance of delayed hospital admission on development of cardiac rupture during acute myocardial infarction: study in 225 patients with free wall, septal or papillary muscle rupture. *J Am Coll Cardiol* 1998; 32: 135-139.
- Cox FF, Morshuis WJ, Kelder JC, Plokker HW, Langemeijer HJ, Vermeulen FE. Rupture recurrence after surgical repair of postinfarction ventricular septal rupture. Influence of early thrombolysis. *Eur J Cardiothorac Surg* 1996; 10: 748-753.
- Oliva PO, Hammill SC, Edwards WE. Cardiac rupture, a clinically predictable complication of acute myocardial infarction: report of 70 cases with clinicopathologic correlations. *J Am Coll Cardiol* 1993; 22: 720-726.
- Pappas PJ, Cernainu AC, Baldino WA, Cilley JH Jr, Del Rossi AJ. Ventricular free wall rupture after myocardial infarction: treatment and outcome. *Chest* 1991; 99: 892-895.
- Alonso JJ, Azpitarte J, Bardají A, Cabades A, Fernández A, Palencia M et al. Guías de práctica clínica en cirugía coronaria. *Rev Esp Cardiol* 2000; 53: 241-266.